

Non Surgical Treatment of Eagle's Syndrome - A Case Report -

Department of Anesthesiology and Pain Medicine, Ajou University College of Medicine, Suwon, Korea

Min Kyu Han, MD, Do Wan Kim, MD, and Jong Yeun Yang, MD

Eagle's syndrome is a disease without a clear lesion that is associated with repeated episodes of pharyngalgia, odynophagia, the sensation of a foreign body in the pharynx, tinnitus, and otalgia in which patients displaying these types of symptoms must be given a differential diagnosis. It is known to be characterized by styloid process elongation or increasing compression to adjacent anatomical structures through stylohyoid ligament calcification. In serious cases, continuous pressure to the carotid artery can lead to a stroke. Diagnosis is confirmed through clinical symptoms, radiological findings, and physical examinations. The most common type of treatment consists of a surgical excision of elongated styloid process. Nonetheless, this study presents a case of treating Eagle's syndrome with conservative management. (Korean J Pain 2013; 26: 169-172)

Key Words:

Eagle's syndrome, styloid process elongation, stylohyoid ligament calcification.

The styloid process is a protrusion of long, thin, cylindrical bone from the temporal bone, which is located between the internal carotid artery and external carotid artery. The mastoid process is at the posterior of it and the tonsillar fossa is located inside it [1]. Eagle's syndrome, first defined by W.W. Eagle in 1937, is pain caused by excessive growth or morphologic abnormality of the styloid process and calcification of the stylohyoid ligament [1,2].

Symptoms present diversely according to the length and width of the styloid process, angle and direction of the curve, and degree of calcification of the stylohyoid ligament. Recognized symptoms include facial pain, sore throat, otalgia, dysphagia, headache, and a sensation of a foreign

body in the pharynx; in rare cases, alteration in taste or vocal changes can also be observed [1,2]. There are both surgical and conservative methods for treating Eagle's syndrome, but in most cases, surgery is performed to remove the elongated styloid process at the outset. However, in this case, a conservative method was chosen due to the preference of the patient, and a significant treatment effect was observed. We report the case along with a literature review.

CASE REPORT

A 36-year-old female patient visited the hospital

Received October 19, 2012. Revised December 18, 2012. Accepted December 21, 2012.

Correspondence to: Do Wan Kim, MD

Department of Anesthesiology and Pain Medicine, Ajou University College of Medicine, San 5 Wonchon-dong, Yeongtong-gu, Suwon 443-749, Korea

Tel: +82-31-219-5896, Fax: +82-31-219-5579, E-mail: anekkindo@naver.com

© This is an open-access article distributed under the terms of the Creative Commons Attribution Non-Commercial License (<http://creativecommons.org/licenses/by-nc/3.0/>), which permits unrestricted non-commercial use, distribution, and reproduction in any medium, provided the original work is properly cited.

Copyright © The Korean Pain Society, 2013

complaining of otalgia that had started approximately 3 years previously. The pain had been recurring 2 to 3 times a month, and there were no abnormalities in her medical history. No particular abnormalities were observed in the otoscopy performed by the otolaryngology department. The pain was characterized as a needle-like, piercing pain inside the ear, and it had worsened one week before the patient's visit to the hospital.

In the physical examination, tenderness was felt in the left mastoid process. Although the styloid process was not felt, it caused pain when the tonsils were touched, and the patient complained of severe pain when turning her neck to the left. The VAS score was 8.

A radiograph (Fig. 1) and CT scan (Fig. 2) were taken

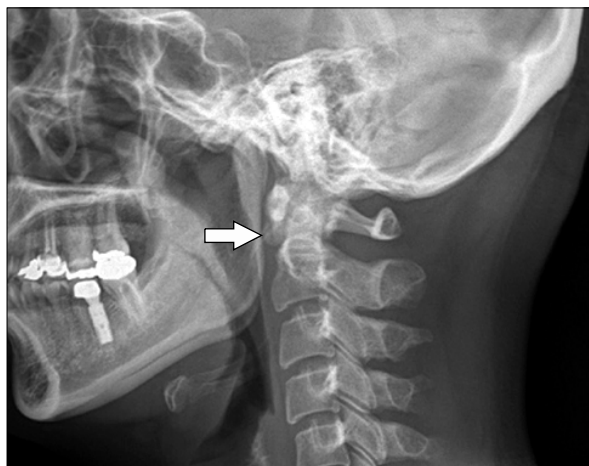


Fig. 1. Lateral view plain radiograph of cervical spine shows elongated styloid process at left side (white arrow).

for differential diagnosis of Eagle's syndrome. The results showed that the length of the right styloid process was approximately 18 mm, within the normal range, whereas the left was approximately 30 mm, which was elongated compared with the right. The disease was explained to the patient and surgical treatment was recommended, but the patient refused. Hence, conservative treatment was selected and performed. Oral medication was begun with administration of gabapentin (Gabapentin[®], Dong-A Pharm Co., Seoul, Korea) 300 mg/d, tianeptine (Stablon[®], Jeil Pharm Co., Seoul, Korea) 1.5 mg/d, and tramadol hydrochloride 37.5 mg/acetaminophen 325 mg (Paramacet[®], Dong-A Pharm Co., Seoul, Korea) 3 tablets/d. In addition, approximately 1 ml of triamcinolone 10 mg combined with 0.3% mepivacaine 3 ml was injected once in the tonsils and tender areas. Afterwards, a stellate ganglion block was performed on the left side once a week for approximately 4 weeks.

The symptoms gradually improved following the drug administration and injection, and after two weeks, the VAS score had fallen to 2.

As the pain did not worsen during the 3-month monitoring period, drug administration was stopped. The patient agreed to consider surgical treatment in case of pain recurrence, and treatment was concluded.

DISCUSSION

Abnormal elongation of the styloid process occurs in approximately 4% of the population; among these, only 4% complain of symptoms. The condition is known to occur

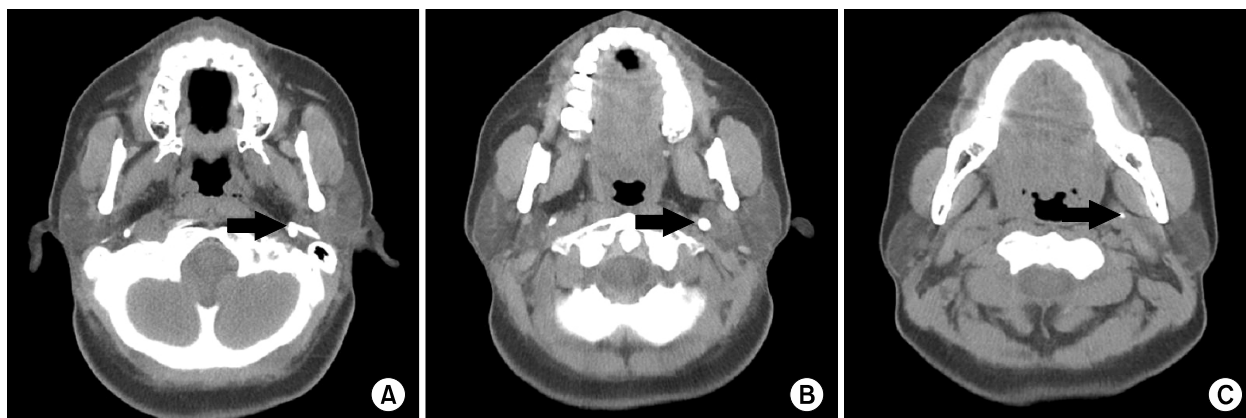


Fig. 2. Axial CT view shows elongated styloid process at left side (black arrows). (A) Origin, (B) Midportion, (C) Distal portion.

most frequently in females in their 30s, 40s, and 50s [3]. The normal length of the styloid process differs according to each individual but is generally less than 20 mm. It is considered elongated when it is 30 mm or longer [4].

There are several hypotheses regarding the cause of Eagle's syndrome. Eagle initially described two types [2,5]. First, 'classic styloid syndrome' occurs mainly after tonsillectomy and is characterized by isolated pharyngalgia in the tonsillar fossa. Its symptoms include dysphagia,odynophagia, a sensation of increased salivation, and a sensation of a foreign body in the pharynx. In rare cases, it can be accompanied by vocal changes [5]. These symptoms are all caused by stimulation to the 5, 8, 9, and 10 cranial nerves near the styloid process, resulting when nerves are entrapped by locally formed granular tissue after tonsillectomy [1]. Damage to the surrounding soft tissue during tonsillectomy can cause ossification and lead to styloid process elongation and ossification of the stylohyoid ligament [4]. Ossification occurs within 2–12 months after such damage [2].

The second type that Eagle described is 'stylocarotid syndrome', which is caused by the stylohyoid organs exerting pressure on the internal and external carotid arteries, regardless of tonsillectomy. The symptoms usually appear along the carotid artery route and are known to be caused by the stimulation of the sympathetic nerve plexus around the blood vessel. Pain in the eye and parietal cephalalgia can occur and may lead to difficulty in differential diagnosis, as these symptoms are also present in cluster headache and migraine. Rarely, aphagia and vision disturbance can occur, and in severe cases, syncopal episodes can occur [5].

Other hypothesized causes include pressurization in surrounding structures due to the proliferation of granulation tissue after styloid process fracture; stimulation of surrounding nerves, such as the terminal branches of the glossopharyngeal nerve and trigeminal nerve or the chorda tympani nerve; and insertion tendonitis, which is a degenerative and inflammatory change occurring in the tendinous portion of the attached area of the stylohyoid ligament [4].

Diagnosis is achieved through clinical symptoms, palpation of the styloid process through the tonsillar fossa, evaluation of pain relief after lidocaine injection, and radiologic tests [6].

With clinical symptoms alone, many difficulties exist in

differential diagnosis due to the existence of various other diseases with similar presentations, such as migraine, tension headache, atypical facial pain, myofascial pain syndrome, salivary gland disease, tonsillitis, and psychosomatic disease. In addition, according to several studies, palpation of the styloid process through the tonsillar fossa is only possible when the length of the styloid process is at least 7.5 cm, and Eagle's syndrome is known to occur in patients with shorter styloid processes [7,8]. The styloid process can be observed easily through a lateral-view plain radiograph, but difficulties may arise in deciphering the image when the styloid processes on both sides overlap. In this case, a CT scan can be useful, and the form of the styloid process can be evaluated from a greater number of angles in 3DCT [9]. Using the lidocaine infiltration test can assist in diagnosis by assessing whether symptoms disappear when the test is performed on the area where the styloid process can be felt in the tonsillar fossa [2].

Both surgical and conservative treatment methods exist. Surgical methods involve amputating or removing the elongated styloid process through an intraoral or extraoral approach. In conservative treatment, oral medication with antidepressants and anticonvulsants can be used, and steroid or local anesthesia with long-term effects can be used on the tonsil or tender areas [10]. Other methods include reducing pain through physical therapy, relaxing the muscles that had been constricted due to styloid process stimulation [3].

The patient in the above case had no abnormalities in her medical history, and the length of the left styloid process was 30 mm, which is on the borderline between the normal range and elongation. Hence, it could not be felt through the tonsillar fossa, and there were difficulties in initial diagnosis. However, otalgia, tenderness of the masseter process and tonsillar fossa area, and pain when turning the neck all occurred on the left side. The diagnosis of Eagle's syndrome was made after confirming through radiograph images that styloid process elongation existed only on the left side. It was presumed that the symptoms had resulted from the elongated styloid process stimulating the surrounding nerves, such as the trigeminal nerve and facial nerves.

At present, in most cases when Eagle's syndrome is diagnosed, surgical removal of the abnormally elongated styloid process is performed, without conservative treatment.

Because the patient in this case refused surgery, however, drug therapy and injection in the tender areas were performed to reduce pain and relieve anxiety. The effect of treatment was expected to be temporary, but during the 3-month monitoring period, pain relief persisted with conservative treatment alone.

Of course, conservative treatment cannot completely replace surgical treatment. However, a satisfactory treatment effect was achieved in this case using only conservative treatment. Therefore, rather than uniformly performing surgical treatment in patients diagnosed with Eagle's syndrome, it may help to attempt conservative treatment first and then consider surgery as required according to progress.

REFERENCES

1. Fusco DJ, Asteraki S, Spetzler RF. Eagle's syndrome: embryology, anatomy, and clinical management. *Acta Neurochir (Wien)* 2012; 154: 1119–26.
2. Piagkou M, Anagnostopoulou S, Kouladouros K, Piagkos G. Eagle's syndrome: a review of the literature. *Clin Anat* 2009; 22: 545–58.
3. Wong ML, Rossi MD, Groff W, Castro S, Powell J. Physical therapy management of a patient with Eagle syndrome. *Physiother Theory Pract* 2011; 27: 319–27.
4. Murtagh RD, Caracciolo JT, Fernandez G. CT findings associated with Eagle syndrome. *AJNR Am J Neuroradiol* 2001; 22: 1401–2.
5. Eagle WW. Symptomatic elongated styloid process; report of two cases of styloid process–carotid artery syndrome with operation. *Arch Otolaryngol* 1949; 49: 490–503.
6. Balbuena L Jr, Hayes D, Ramirez SG, Johnson R. Eagle's syndrome (elongated styloid process). *South Med J* 1997; 90: 331–4.
7. Hampf G, Aalberg V, Tasanen A, Nyman C. A holistic approach to stylalgia. *Int J Oral Maxillofac Surg* 1986; 15: 549–52.
8. Ghosh LM, Dubey SP. The syndrome of elongated styloid process. *Auris Nasus Larynx* 1999; 26: 169–75.
9. Baddour HM, McAnear JT, Tilson HB. Eagle's syndrome. Report of a case. *Oral Surg Oral Med Oral Pathol* 1978; 46: 486–94.
10. Glogoff MR, Baum SM, Cheifetz I. Diagnosis and treatment of Eagle's syndrome. *J Oral Surg* 1981; 39: 941–4.