

Atypical femoral fractures after anti-osteoporotic medication: a Korean multicenter study

Joon Soon Kang · Ye Yeon Won · Jong Oh Kim ·
Byeong Woo Min · Kee Haeng Lee · Kwan Kyu Park ·
Joo Hyun Song · Young Tae Kim · Geon Ho Kim

Received: 19 September 2013 / Accepted: 12 December 2013 / Published online: 25 January 2014
© Springer-Verlag Berlin Heidelberg 2014

Abstract

Purpose Increasing numbers of atypical femoral fractures have been reported among long-term bisphosphonate users. We evaluated clinical characteristics of atypical femoral fractures throughout Korean multicenter studies.

Methods We retrospectively analysed the bone mineral density, prodromal symptoms before femoral fracture, and

medication history of osteoporosis in 76 cases of atypical femoral fracture.

Results The mean age of cases was 71.4 ± 8.8 (range, 43–89) years old. The mean follow-up period after the fracture operation was 24.5 ± 12.9 (range, 12–79) months. BMI was 23.2 ± 3.0 on average. The mean BMD of femur was -1.9 ± 1.4 (range, -4.8 to 1.3). Prodromal symptoms including thigh pain before femoral fracture appeared in 22 (28.9 %) of 76 patients. All patients included in the study used bisphosphonate. The duration of taking bisphosphonate before fracture was 36.8 ± 50.8 (one–204 months) months. Fifty-seven (75 %) of 76 patients were taking the medication for more than three years. Delayed union occurred in 43 (56.5 %) of 76 patients. Delayed union was defined as a fractured bone that did not completely heal within six months of injury. The group of having taken anti-osteoporotic medication for more than three years showed relatively longer union period compared to that for a shorter period medication group (4.8 ± 2.5 months vs 9.3 ± 3.7 months, $p=0.017$). The delayed union developed in 43 (56.5 %) of 76 patients and showed a significantly higher incidence in the group with long-term therapy (five/43 vs 38/43, $p=0.021$). The bilateral femoral fractures developed in 23 (30.2 %) of 76 patients and showed a high incidence in the group medicated more than three years (two/23 vs 21/23, $p=0.039$).

Conclusions The longer bisphosphonates are used, the more the cases of delayed union and the more frequent the development of bilateral fractures following unilateral fractures. With regard to the delayed union, the methods of the acceleration of fracture healing may be beneficial in atypical femoral fracture patients who had been receiving long-term bisphosphonates therapy. Careful observation is required for contra-lateral femurs due to a high incidence of bilateral atypical femoral fractures.

J. S. Kang (✉) · Y. T. Kim (✉) · G. H. Kim
Department of Orthopaedic Surgery, College of Medicine, Inha University, 7-206, 3-ga, Sinhueng-dong, Jung-gu, Incheon 400-711, Korea
e-mail: kangjoon@inha.ac.kr
e-mail: zero-ti@daum.net

Y. Y. Won
Department of Orthopaedic Surgery, College of Medicine, Ajou University, San-5, Wonchon-dong, Yeongtong-gu, Suwon 443-721, Korea

J. O. Kim
Department of Orthopaedic Surgery, College of Medicine, Ewha University, 911-1, Mok-dong, Yangcheon-gu, 158-710 Seoul, Korea

B. W. Min
Department of Orthopaedic Surgery, Dongsan Medical Center, Kyemyung University College of Medicine, 56 Dalseong-ro, Jung-gu, Daegu 700-712, Korea

K. H. Lee
Department of Orthopaedic Surgery, College of Medicine, Bucheon St. Mary's Hospital, Catholic University of Korea, 327 Sosa-dong, Wonmi-gu, Bucheon, Gyeonggi-do, Korea

K. K. Park
Department of Orthopaedic Surgery, Yonsei University College of Medicine, 134 Shinchon-dong, Seodaemun-gu, Seoul 120-752, Korea

J. H. Song
Department of Orthopaedic Surgery, College of Medicine, Suwon St. Vincent's Hospital, Catholic University of Korea, 327 Paldal-gu, Suwon, Gyeong-do, Korea

Keywords Atypical femoral fracture · Osteoporosis · Bisphosphonates · Delayed union

Introduction

Osteoporosis is associated with significant morbidity and mortality [1, 2], and approximately 50 % of women older than 50 years will sustain an osteoporosis-related fracture during their lifetime, and one of five patients with an osteoporosis-related fracture will die within 12 months [3–5].

Bisphosphonates (BPs) reduce the overall risk of fractures among patients with osteoporosis, with a long-lasting beneficial effect [6], but it is known that they reduce bone remodeling, they might “freeze” the skeleton, and they allow accumulation of micro-cracks over time, leading to fatigue fractures (also called stress fractures) [7].

In published case reports that classified femoral fractures as stress fractures or non-stress fractures according to their radiographic appearance, among patients admitted to tertiary centres, such stress fractures (commonly called atypical femoral fractures, the term used here) were more common in patients who received bisphosphonate than in those who did not [8]. However, recent data suggests that the relative risk of patients with atypical femoral fractures taking bisphosphonates is high, but the absolute risk of atypical femoral fracture associated with bisphosphonates therapy is low [9–11]. Several studies suggest that the incidence of atypical femoral fractures increases with increasing duration of exposure [12].

The relationships between the duration of bisphosphonates use and atypical femoral fractures have not been studied thoroughly until recently and most studies have been limited to Westerners and females. There have been few documented multicenter studies of atypical femoral fractures in Korea compared with the number of studies that have been conducted in Western populations.

The aim of this multicenter study was to investigate the clinical features of atypical femoral fractures among bisphosphonates users, to clarify the association between long-term (greater than three year) bisphosphonates therapy and characteristics of atypical femoral fractures.

Methods

Patients and clinical data collection

The Institutional Review Boards of the participating centres provided ethical approval of the study.

A total of 108 consecutive patients with displaced atypical femoral fracture sustained after minimal trauma between January 2005 and June 2011 were retrospectively reviewed based on images and the medical records from eight tertiary referral hospitals. According to the criteria of the ASBMR Task Force 2013, atypical femoral fracture was defined as a fracture located along the femur from just distal

to the lesser trochanter to just proximal to the supracondylar flare, associated with minimal or no trauma history, transverse or short oblique configuration, non-comminuted or minimal comminuted, complete fractures extending through both cortices or incomplete fracture involving only the lateral cortex, localized periosteal or endosteal thickening of the lateral cortex [11].

Radiographs of all patients were assessed by two orthopaedic surgeons in each participating centre, blinded for all background information.

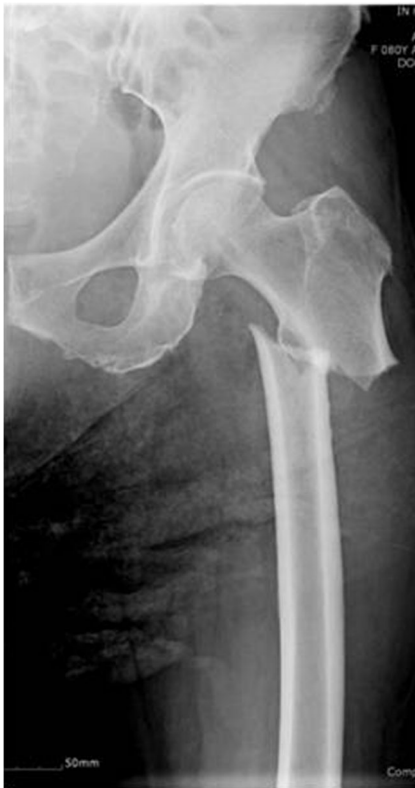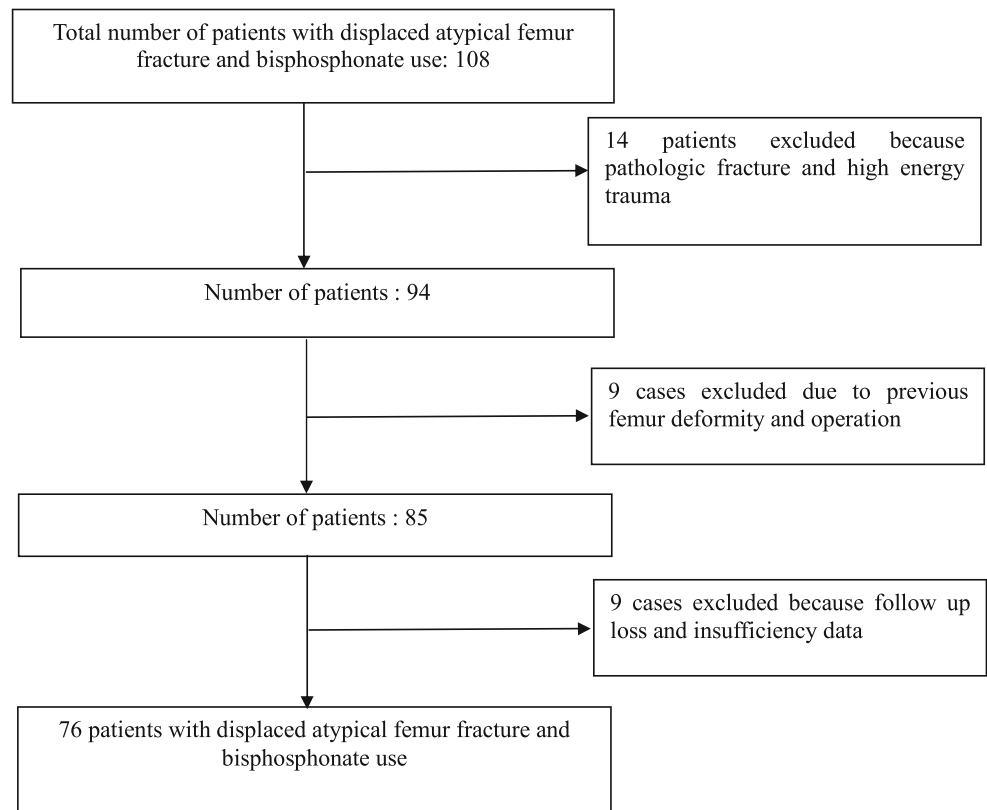
Among these patients, 32 were excluded because of history of pathologic fracture, high energy traumas, deformities, a previous history of femoral operation on another site, or insufficient data. We included the patients with a history of cancer which were not related to the femur fracture, but excluded pathologic fracture as mentioned. Finally, 76 patients were included for the analyses (Fig. 1).

Data collected from the medical record included detailed demographic and clinical data such as hypertension, diabetes, renal disease, cancers, steroid use, and hormonal treatment in female patients. The use of bisphosphonates and its duration, the history of prodromal symptoms, and the mechanisms of injury were recorded. The history of operation was also gathered from medical records including types of the operations and instruments used.

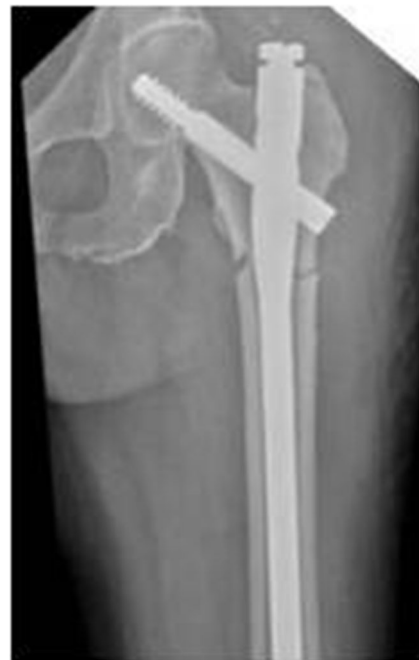On radiologic evaluation, we classified fracture pattern (subtrochanteric or femur shaft fractures) using radiologic analyses. The subtrochanteric fracture was defined as extending 5 cm below the lesser trochanter. The femur shaft fracture was defined as extending from below the subtrochanteric region to supracondylar metaphyseal flare. We also checked bilaterality for atypical femoral fractures on initial and follow-up radiographs. Bony union of the atypical femoral fracture was assessed using plain radiographs at three months, six months, 12 months, and yearly thereafter, but a shorter interval of check up was made when a bony union was not seen or controversial. Radiographic healing was defined as bony bridging of three of four cortices on anteroposterior (AP) and lateral radiographs, as well as painless weight bearing on the affected extremity. Dual energy X-ray absorptiometry hip images were taken in all patients within three months after fractures and thereafter with an interval of one year at the corresponding hospitals (Figs. 2, 3, 4, and 5).

Statistical analysis

Baseline data demonstrated means \pm standard deviations with ranges for continuous variables and counts and percentages for categorical variables. Wilcoxon rank sum test was used for the comparisons of continuous variables of two groups and Fisher's exact test was used for the comparisons of categorical variables according to the different variables. All statistical

Fig. 1 Flow diagram of the selection of the patients**Fig. 2** Pre-operative radiography of an 80-year-old woman who had taken oral alendronate medication for five years prior to atypical femoral subtrochanteric fracture

analyses were carried out using SPSS version 20.0 software package (Chicago, IL, USA). P-values less than 0.05 were considered statistically significant. This study was reviewed and approved by the institutional review board, and informed consent from the patients was waived.

**Fig. 3** Immediate postoperative radiography

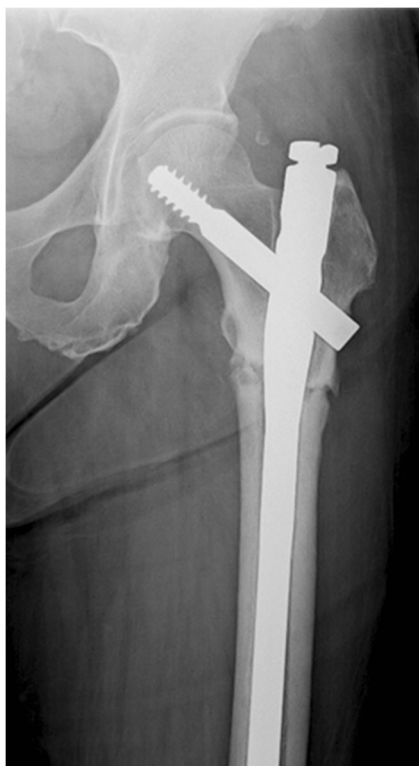

Fig. 4 At six months after operation, delayed union of fracture was noticed. Parathyroid hormone (PTH) was administered subcutaneously for four months

Results

The mean age of the 76 patients was 71.4 ± 8.8 years. The majority of patients were females (three males and 73 females). The BMI was 23.2 ± 3.0 kg/m² on average. The bone

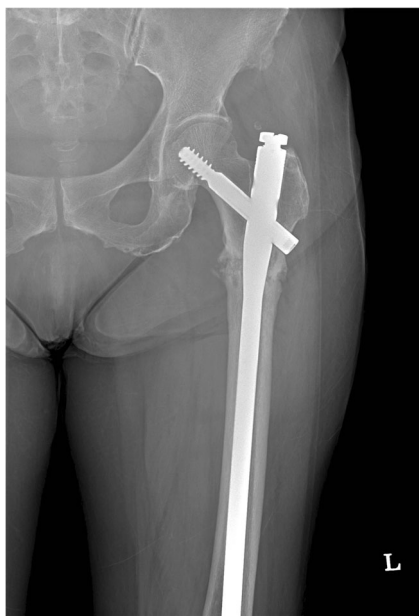

Fig. 5 Union of fracture was obtained 11 months after operation

Table 1 Demographic data of the patients

Variable	Atypical fracture (n=76)
Age (year)	71.4±8.8 (range, 43–89)
Gender (male : female)	3 (3.94 %)/73 (96 %)
BMI	23.2±3.0
BMD (T-score, femur)	-1.9±1.4 (range, -4.8 to -1.3)
F/U after operation (months)	24.5±12.9 (range, 12–79)
Renal disease (n)	7 (9.2 %)
Steroid use (n)	9 (11.8 %)
Hormone replacement therapy (n)	26 (34.2 %)
Cancer history (n)	5 (6.6 %)

BMI body mass index, BMD bone mineral density, F/U follow up

mineral density (BMD) of total femurs was -1.9 ± 1.4 . Forty eight (63.7 %) of 76 patients were in the osteopenic range, not osteoporotic range.

Seven (9.2 %) of 76 patients had renal diseases and nine (11.8 %) of 76 patients had a history of steroids use. Five (6.6 %) of 76 patients had a history of cancers and 26 (34.2 %) of 76 patients underwent hormone replacement treatments (Table 1).

All patients included in the study took bisphosphonates. The total duration of taking anti-osteoporotic medications was 36.8 ± 50.8 months, and 57 (75 %) of 76 patients took them for more than three years. With regard to the anti-osteoporotic medications, alendronate was administered to 41 (53.9 %) patients, risedronate to 18 (23.6 %) patients, ibandronate to ten (13.1 %), pamidronate to one (1.3 %), zolendronate to one (1.3 %), and two or more of these to five (6.5 %) patients (Table 2).

Prodromal symptoms developed in 22 (28.9 %) of the 76 patients and the duration of the symptoms was 6.3 ± 8.1 months.

With respect to the types of fractures, 59 (77.6 %) patients showed subtrochanteric fractures, and in 17 (22.4 %) patients femoral shafts were involved. Regarding the methods of surgical treatments, 37 (62.7 %) patients of subtrochanteric fractures and nine (52.9 %) of femoral shaft fractures were treated by open reductions, which exceeded the number of closed reductions.

The duration of union was 9.4 ± 5.9 months and the union was delayed for more than six months in 43 (56.5 %) patients.

Table 2 Characteristics of the anti-osteoporotic medications

Characteristic	Patients (n=76)
Medication duration (months)	36.8±50.8 months (range, 1–204)
>3 year medication (n)	57 (75 %)
Alendronate (n)	41 (53.9 %)
Risedronate (n)	18 (23.6 %)
Ibandronate (n)	10 (13.1 %)
Pamidronate (n)	1 (1.3 %)
Zolendronate (n)	1 (1.3 %)
Mixed (n)	5 (6.5 %)

Table 3 Characteristics of the clinical symptoms and fractures

Characteristic	Atypical fracture (<i>n</i> =76)	
Prodromal symptom (<i>n</i>)	22 (28.9 %)	
Prodromal symptom duration (months)	6.3±8.1 months (range, 1–37)	
Fracture type	Subtrochanteric (<i>n</i>)	59 (77.6 %)
	Shaft (<i>n</i>)	17 (22.4 %)
Open reduction	Subtrochanteric (<i>n</i> =59)	37 (62.7 %)
	Shaft (<i>n</i> =17)	9 (52.9 %)
Duration of union (months)	9.4±5.9 months (range, 4–26)	
Delayed union (>6 months) (<i>n</i>)	43 (56.5 %)	
Bilateral fracture (<i>n</i>)	Incidence (<i>n</i>)	23 (30.2 %)
	Interval between fracture	23.3±26.2 months (range, 5–84)

The majority of patients suffered from unilateral fractures, and bilateral fractures occurred in 23 (30.2 %) patients. The interval between the fractures on one side and the other was two years on average (23.3±26.2 months) (Table 3).

Considering the duration of union of fractures and the development of bilateral fractures according to the duration of taking anti-osteoporotic medications, the duration of union was prolonged with the administration of medications for more than three years. The duration of union was 4.8±2.5 months in patients who had taken medications for less than three years, and 9.3±3.7 months in those who had been medicated for more than three years. This difference was statistically significant with a *P* value of 0.017. Five out of 19 patients (26.3 %) represented delayed union within three years of medication while 38 out of 57 patients (66.6 %) developed delayed union with more than three years of medication. This difference was also statistically significant (*P*=0.021).

Two out of 19 patients (10.5 %) developed bilateral fractures with less than three years of medication while 21 out of 57 patients (36.8 %) experienced bilateral fracture with more than three years of medication. The incidence of bilateral fractures in the more-than-three-year-medication group was higher than the less-than-three-year-medication group, with the difference being statistically significant (*P*=0.039) (Table 4).

Discussion

We attempted to demonstrate the relationship between the administration of anti-osteoporotic medications and atypical femoral fractures, by analysing the cases diagnosed as having

atypical fractures among the patients who were taking bisphosphonates, and reviewing the results of Korean multi-center studies. We also tried to elucidate the inter-relationship between the atypical fractures and the long-term administration of anti-osteoporotic medications for more than three years.

An interesting finding of our study was the discovery that the mean bone density T-scores of femur at time of fracture were in the osteopenic range. Forty eight (63.7 %) of 76 patients had osteopenia or normal BMD. The majority of the patients did not have osteoporosis. This finding was similar with recent reports, and supports that atypical femoral fractures are a separate fracture entity with osteoporotic femur fracture. As shown in our cases, prolonged suppression of bone remodeling improves BMD, but made bone less able to deform, therefore predisposing to accumulation of microdamage. These findings suggest that bisphosphonate therapy could be stopped when BMD is increased, in order to prevent adverse events, in agreement with other authors which recommend a drug holiday in selected patients [13].

In our study, delayed unions following the treatment of atypical fractures comprised more than half of cases (56.5 %), which showed higher percentage than the previous study [14]. Those of Asian race have differences in femur geometry that may contribute to the high prevalence of delayed union. Regarding the bilaterality of atypical femur fracture, fractures developed in 23 out of 76 patients (30.2 %). The high incidence of bilaterality is consistent with previous reports [14]. These two variables (union being delayed for more than six months, and bilateral fractures) had statically significant relationships with the duration of taking medications. The longer the duration of taking medications, the more frequent the incidence of these variables.

Table 4 Differences of characteristics of the fractures according to the duration of bisphosphonate therapy

Characteristic	<3 year medication (<i>n</i> =19)	>3 year medication (<i>n</i> =57)	<i>p</i> -value
Duration of union (months)	4.8±2.5 months	9.3±3.7 months	0.017
Delayed union (<i>n</i> =43)	5	38	0.021
Bilateral fraction (<i>n</i> =23)	2	21	0.039

Delayed union of femur fracture may lead to long-term recumbent status and poor functional outcomes. Delayed fracture healing may indicate a need for more aggressive medical and biologic augmentations.

The bone graft is known as the gold standard of treatment of delayed union, and studies on the use of parathyroid hormone (PTH) in delayed union have resulted in an improvement in the union.

The use of PTH is approved for use in patients who are at high risk for osteoporotic fractures. With its short half life, intermittent daily administration has been shown to increase bone mass by proliferating the osteoblast and suppressing the apoptosis of osteoblast [15]. Bukata et al., who presented an observational cohort of 145 patients with delayed fracture healing, noted that 135 patients (93 %) achieved radiological union of fracture with PTH administration within 2.8 months [16]. Recently, Aspenberg et al. showed that osteoporotic distal radius fractures that were treated with PTH resulted in earlier cortical bridging compared to a placebo group [17].

The possibility of inducing fracture healing through physical methods has been investigated. Recent studies have shown an accelerating effect of low-intensity pulsed ultrasound (LIPUS) on delayed union. Rubin et al. reported that The Food and Drug Administration approved the use of low-intensity ultrasound for the accelerated healing of delayed union [18]. Jingushi et al. analysed the factors that influence the union rate on delayed union and nonunion. They concluded that the earlier LIPUS treatments were started, the better the results [19].

In this study, 43 (56.5 %) of 76 patients need more than six months for fracture healing. We think that bisphosphonate-related femoral fractures require additional methods for stimulating bone healing. Thus, using PTH medications and LIPUS treatment in the postoperative period may be helpful to prevent delayed union of bisphosphonate-associated atypical fracture.

Another finding is the high occurrence of bilateral femoral fractures. In this study, 23 (30.2 %) of 76 patients experienced bilateral fracture. Notedly, 21 (91.3 %) patients belonged to the long-term (greater than three year) medication group. Regarding bilateral atypical femoral fracture, few publications described treatments and outcomes.

Das et al. [20] performed a retrospective review of alendronate-associated subtrochanteric fractures that tend to be bilateral, have unique radiological features, are associated radiologically with a pre-existing ellipsoid thickening of the lateral femoral cortex and are likely to be preceded by prodromal pains. Ha et al. [21] reported femoral insufficiency fractures after long-term bisphosphonate therapy seldom healed spontaneously and most patients had surgery due to displacement of fractures and persistent pain. Capeci and Tejwani reported seven patients who sustained bilateral subtrochanteric or diaphyseal femoral fracture. They recommended that prophylactic fixation should be considered for contralateral femur stress fractures [22].

In this study, we found that long-term bisphosphonate therapy was associated with a high incidence of bilateral fracture. Thus, routine radiographs of the contra-lateral femurs and more frequent follow-up visits are necessary, especially if a patient has a medical history of long-term bisphosphonate therapy. If a contralateral stress fracture is found, prophylactic fixation should be considered.

Limitations of this study could be the fact that it is retrospectively undertaken and that the collection of data is based on medical records which may pose the possibility of inaccuracy.

Conclusions

In our study, the longer bisphosphonates are used, the more the cases of delayed union and the more frequent the development of bilateral fractures following unilateral fractures. We believe that more aggressive medical and surgical strategies are necessary for patients on long-term bisphosphonate therapy who present with atypical femoral fracture. Considering high incidence of bilateral atypical femoral fracture, careful observation is required for the contralateral femur.

Conflict of interest None to declare.

Ethical review committee statement This multicenter study was approved by the institutional review board of the authors' institute.

References

- Ioannidis G, Papaioannou A, Hopman WM et al (2009) Relation between fractures and mortality: results from the Canadian multicentre osteoporosis study. *CMAJ* 181(5):265–271
- Papaioannou A, Kennedy CC, Ioannidis G, CaMos Study Group et al (2009) The impact of incident fractures on health-related quality of life: 5 years of data from the Canadian multicentre osteoporosis study. *Osteoporos Int* 20(5):703–714
- Haentjens P, Magaziner J, Colon-Emeric CS et al (2010) Meta-analysis: excess mortality after hip fracture among older women and men. *Ann Intern Med* 152(6):380–390
- US Department of Health and Human Services (2004) Bone Health and Osteoporosis. A report of the surgeon general. US Dept of Health and Human Services, Office of the Surgeon General, Rockville
- Haleem S, Lutchman L, Mayahi R, Grice JE, Parker MJ (2008) Mortality following hip fracture: trends and geographical variations over the last 40 years. *Injury* 39(10):1157–1163
- Black DM, Schwartz AV, Ensrud KE et al (2006) Effects of continuing or stopping alendronate after 5 years of treatment: the Fracture Intervention Trial Long-term Extension (FLEX): a randomized trial. *JAMA* 296:2927–2938
- Neer RM (1995) Skeletal safety of tiludronate. *Bone* 17(Suppl): 501S–503S
- Lenart BA, Neviasser AS, Lyman S et al (2009) Association of low-energy femoral fractures with prolonged bisphosphonate use: a case control study. *Osteoporos Int* 20:1353–1362

9. Schilcher J, Michaelsson K, Aspenberg P (2010) Bisphosphonate use and atypical fractures of the femoral shaft. *N Engl J Med* 364:1728–1737
10. Thompson RN, Phillips JR, McCauley SH, Elliott JR, Moran CG (2012) Atypical femoral fractures and bisphosphonate treatment: experience in two large United Kingdom teaching hospitals. *J Bone Joint Surg Br* 94:385–390
11. Shane E, Burr D, Ebeling PR et al (2014) Atypical subtrochanteric and diaphyseal femoral fractures: second report of a task force of the American Society for Bone and Mineral Research. *J Bone Miner Res* 29(1):1–23. doi:10.1002/jbmr.1998
12. Dell RM, Adams AL, Greene DF, Funahashi TT, Silverman SL, Eisemon EO, Zhou H, Burchette RJ, Ott SM (2012) Incidence of atypical nontraumatic diaphyseal fractures of the femur. *J Bone Miner Res* 27:2544–2550
13. Watts NB, Diab DL (2010) Long-term use of bisphosphonates in osteoporosis. *J Clin Endocrinol Metab* 95:1555–1565
14. Shane E, Burr D, Ebeling PR et al (2010) Atypical subtrochanteric and diaphyseal femoral fractures: report of a task force of the American Society for Bone and Mineral Research. *J Bone Miner Res* 25(11):2267–2294
15. Rogers MJ, Crockett JC, Coxon FP, Mönkkönen J (2011) Biochemical and molecular mechanisms of action of bisphosphonates. *Bone* 49:34–41
16. Bukata SV, Kaback LA, Reynolds DG, Keefe RJ, Rosier RN (2009) 1–34 PTH at physiologic doses in humans shows promise as a helpful adjuvant in difficult to heal fractures: an observational cohort of 145 patients. Proceedings of the 55th Annual Meeting of the Orthopaedic Research Society, February 22–25, Las Vegas
17. Aspenberg P, Genant HK, Johansson T, Nino AJ, See K et al (2010) Teriparatide for acceleration of fracture repair in humans: a prospective, randomized, double-blind study of 102 postmenopausal women with distal radial fractures. *J Bone Mineral Res* 25:404–414
18. Rubin C, Bolander M, Ryaby JP, Hadjiargyrou M (2001) The use of low intensity ultrasound to accelerate the healing of fractures. *J Bone Joint Surg Am* 83-A:259–270
19. Jingushi S, Mizuno K, Matsushita T, Itoman M (2007) Low-intensity pulsed ultrasound treatment for postoperative delayed union or non-union of long bone fractures. *J Orthop Sci* 12:35–41
20. De Das S, Setiobudi T, Shen L, De Das S (2010) A rational approach to management of alendronate-related subtrochanteric fractures. *J Bone Joint Surg Br* 92:679–686
21. Ha YC, Cho MR, Park KH, Kim SY, Koo KH (2010) Is surgery necessary for femoral insufficiency fractures after long-term bisphosphonate therapy? *Clin Orthop Relat Res* 468:3393–3398
22. Capeci CM, Tejwani NC (2009) Bilateral low-energy simultaneous or sequential femoral fractures in patients on long-term alendronate therapy. *J Bone Joint Surg Am* 91:2556–2561