

Recurrent Stent Thrombosis in a Patient with Antiphospholipid Syndrome and Dual Anti-Platelet Therapy Non-Responsiveness

You-Hong Lee, MD¹, Hyoung-Mo Yang, MD¹, Seung-Jea Tahk, MD¹, You-Sun Hong, MD², Jin-Sun Park, MD¹, Kyoung-Woo Seo, MD¹, Yong-Woo Choi, MD¹, and Choong-Kyun Noh, MD¹

¹Departments of Cardiology and ²Thoracic and Cardiovascular Surgery, Ajou University School of Medicine, Suwon, Korea

Antiphospholipid syndrome (APS), the most common acquired hypercoagulable condition, is diagnosed by persistent presence of antiphospholipid antibodies and episodes of vascular thrombosis. It may be an important predisposing factor for stent thrombosis, resulting in poor outcomes. Also, anti-platelet therapy non-responsiveness is associated with stent thrombosis. We report a case of a 39-year-old man who after undergoing successful percutaneous coronary intervention for significant coronary artery disease suffered repeated stent thrombosis events leading to ST-segment elevation myocardial infarction. Eventually, he underwent coronary artery bypass surgery because of uncontrolled thrombosis and was diagnosed as having APS and dual antiplatelet therapy non-responsiveness. (**Korean Circ J 2015;45(1):71-76**)

KEY WORDS: Antiphospholipid syndrome; Percutaneous coronary intervention; Stents; Thrombosis.

Introduction

Antiphospholipid syndrome (APS) is a multisystem disorder characterized by vascular thromboses or pregnancy morbidity such as fetal loss, and it occurs in patients who have persistent antiphospholipid antibodies (aPL).¹⁾ Cardiac manifestations of APS include valvular heart disease, coronary artery disease, intracardiac thrombosis, pulmonary hypertension, and dilated cardiomyopathy. Although uncommon, the risk of coronary artery disease and restenosis after percutaneous coronary intervention (PCI) increases in APS patients.^{2,3)} There is no definitive evidence on the relationship between APS and stent thrombosis. However, it seems likely that APS predisposes to stent thrombosis because of its propensity for thrombotic

complications. Aspirin and clopidogrel non-responsiveness is also one of the predictors of stent thrombosis.⁴⁾ Here, we report a case of recurrent stent thrombosis after coronary stent implantation in a patient diagnosed with APS and dual anti-platelet (aspirin and clopidogrel) therapy non-responsiveness.

Case

A 39-year-old man with a history of current smoking as a coronary artery disease risk factor and no other medical history was admitted for left-sided squeezing chest pain that was worse in the early morning after drinking alcohol and the duration of chest pain was 30 minutes. Initial blood pressure was 132/89 mm Hg and pulse rate was 98 beats/minute. Electrocardiogram (ECG) showed ST-segment depression in leads V 3-5 and flattened T wave in leads II, III, and aVF (Fig. 1). The initial laboratory findings were creatine kinase (CK) 118 U/L (58-348), CK-MB 1.7 ug/L (0-5.0), and elevated highly sensitive troponin-T 0.027 ng/mL (0-0.014). Echocardiography revealed normal-sized cardiac chambers with good left ventricular systolic function (ejection fraction of 61%), and no regional wall motion abnormality.

Clinical diagnosis of acute non-ST elevation myocardial infarction (MI) was made. We performed coronary angiography (CAG) with intravenous heparin infusion, and 300 mg of aspirin and 600 mg of clopidogrel were given. CAG revealed near total occlusion of the

Received: January 10, 2014

Revision Received: April 14, 2014

Accepted: June 9, 2014

Correspondence: Hyoung-Mo Yang, MD, Department of Cardiology, Ajou University School of Medicine, 164 Worldcup-ro, Yeongtong-gu, Suwon 443-721, Korea

Tel: 82-31-219-5712, Fax: 82-31-219-5708

E-mail: yhhm20@hanmail.net

• The authors have no financial conflicts of interest.

This is an Open Access article distributed under the terms of the Creative Commons Attribution Non-Commercial License (<http://creativecommons.org/licenses/by-nc/3.0>) which permits unrestricted non-commercial use, distribution, and reproduction in any medium, provided the original work is properly cited.

mid left anterior descending coronary artery (LAD) and significant stenosis of the mid right coronary artery (Fig. 2A and B). PCI was performed for revascularization of the mid LAD. Because the laboratory findings showed microcytic hypochromic anemia (Hb 9.8 g/dL), we decided to use the bare metal stent. After balloon predilation, a 2.75×23 mm Genous® stent (OrbusNeich, Hoelvelaken, The Netherlands) was placed in the mid LAD with adjunctive high pressure ballooning using Powered Lacrosse® 2.5×10 mm (Goodman, Nagoya, Japan). After high pressure ballooning, follow-up angiography and intravascular ultrasound (IVUS; Boston Scientific, MA, USA) showed minor dissection at the distal stent edge. We therefore performed additional overlapping stenting using a 2.5×23 mm Genous® stent; the procedure was successful without any angiographic complications

and final IVUS did not show dissection, or stent malapposition, or stent underexpansion (Fig. 2C and D).

On hospital day 2, after 4 hours of stopping intravenous heparin, the patient complained of acute chest pain. ECG showed ST-segment elevation in leads V 1–6, I, and aVL, and ST-segment depression in leads III and aVF (Fig. 3). We performed CAG immediately, and it showed that mid LAD at the previous stented site was totally occluded by thrombi, which indicated acute stent thrombosis (Fig. 4A). Aspiration thrombectomy was performed using a Thrombuster® catheter (Kaneka Medix, Osaka, Japan), and percutaneous transluminal coronary angioplasty (PTCA) with 2.5×20 mm Lacrosse® (Goodman) balloon was performed with intracoronary abciximab infusion. Final angiography showed Thrombolysis in Myocardial Infarction

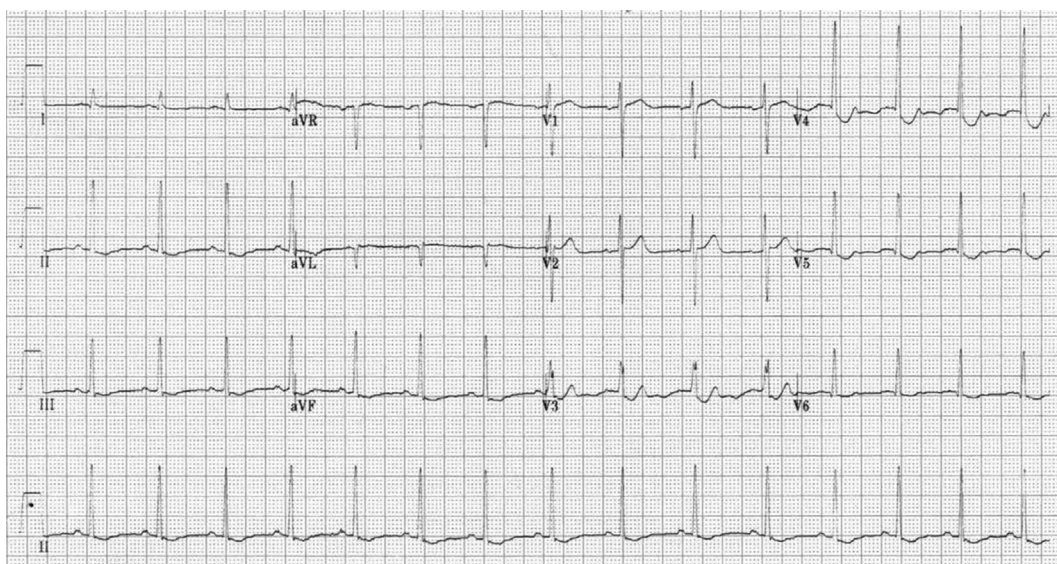


Fig. 1. Initial electrocardiogram. Electrocardiogram shows ST-segment depression in leads V 3–5 and flattened T wave in leads II, III, and aVF.

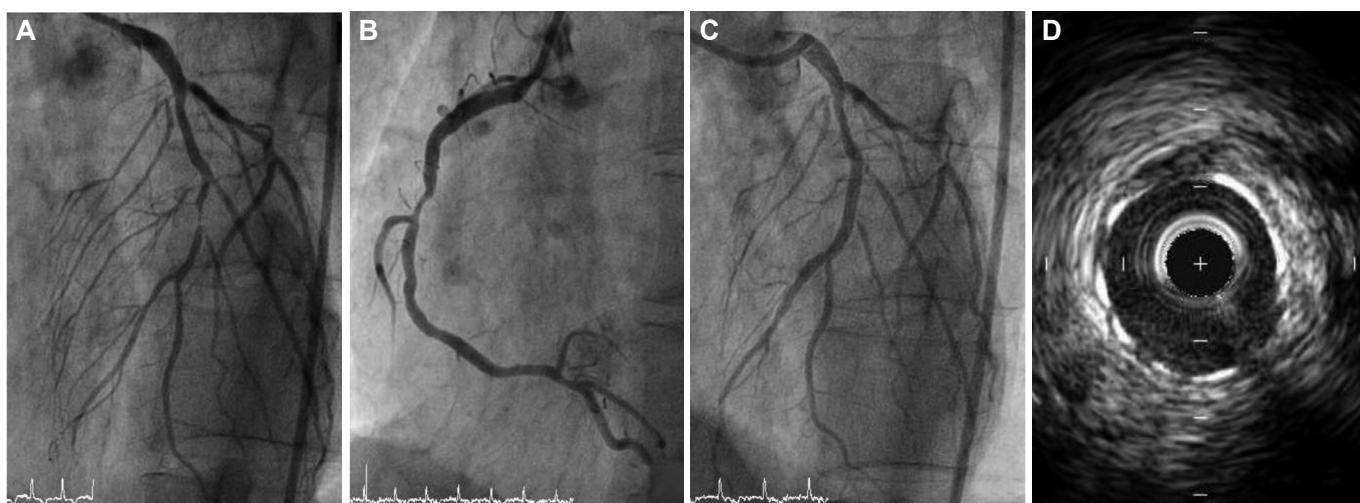


Fig. 2. Initial coronary angiography. A: left coronary angiography shows near total occlusion of the mid left anterior descending coronary artery and intermediate stenosis of the left circumflex coronary artery. B: right coronary artery shows significant stenosis at the mid portion. C: after stent implantation, coronary angiography shows a successful result. D: final intravascular ultrasound finding after overlapping stent does not show dissection, or stent malapposition, or stent underexpansion.

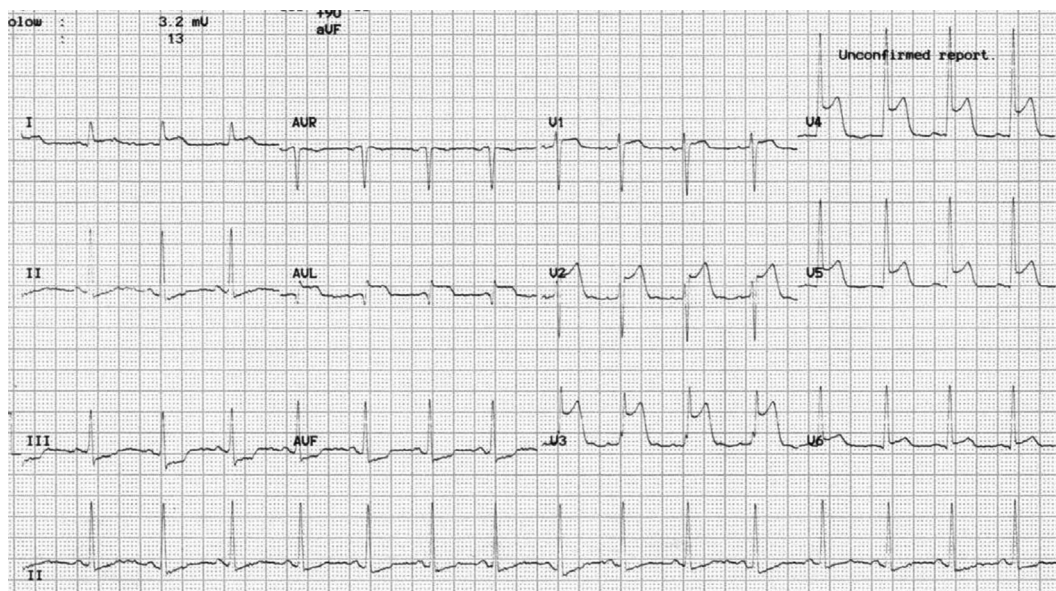


Fig. 3. Electrocardiogram during the first stent thrombosis event. Electrocardiogram showed ST-segment elevation in leads V 1–6, I, and aVL, and ST-segment depression in leads III and aVF.

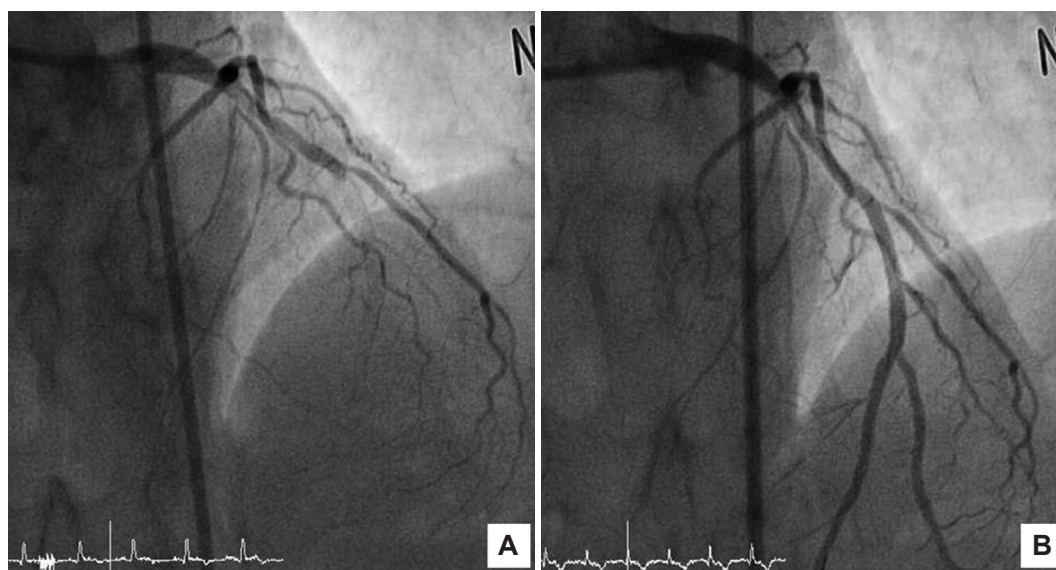


Fig. 4. Coronary angiography in the first acute stent thrombosis event. A: mid left anterior descending coronary artery at the previous stented site shows total occlusion by thrombi. B: after aspiration thrombectomy and balloon angioplasty, final angiography shows Thrombolysis in Myocardial Infarction grade 3 flow.

grade 3 flow (Fig. 4B).

After successful 2nd PCI, patient's chest pain subsided with resolution of ST-segment elevation. Because IVUS findings after overlapped stenting during the index procedure did not show any mechanical complications and the level of P2Y12 Reaction Units (PRU) after stent thrombosis indicated clopidogrel resistance (P2Y12 inhibition rate was 6%), we thought that the major contributing cause of stent thrombosis was clopidogrel resistance. We added cilostazol and continued intravenous heparin infusion for 5 days. On hospital day 7, intravenous heparin infusion was stopped for discharge

preparation. Approximately 4 hours after heparin discontinuation, the patient complained of similar chest pain as that he had experienced 5 days ago. ECG revealed ST-segment elevation in leads V 1–6, I, and aVL, and ST-segment depression in leads III and aVF. Repeated CAG revealed total occlusion of the stented mid LAD, with recurrent stent thrombosis (Fig. 5A). Even after thrombus aspiration and PTCA, the intraluminal filling defect persisted (Fig. 5B). We decided to perform coronary artery bypass graft (CABG) surgery because of recurrent and persistent thrombus formation. Before CABG, follow-up echocardiogram had demonstrated newly developed

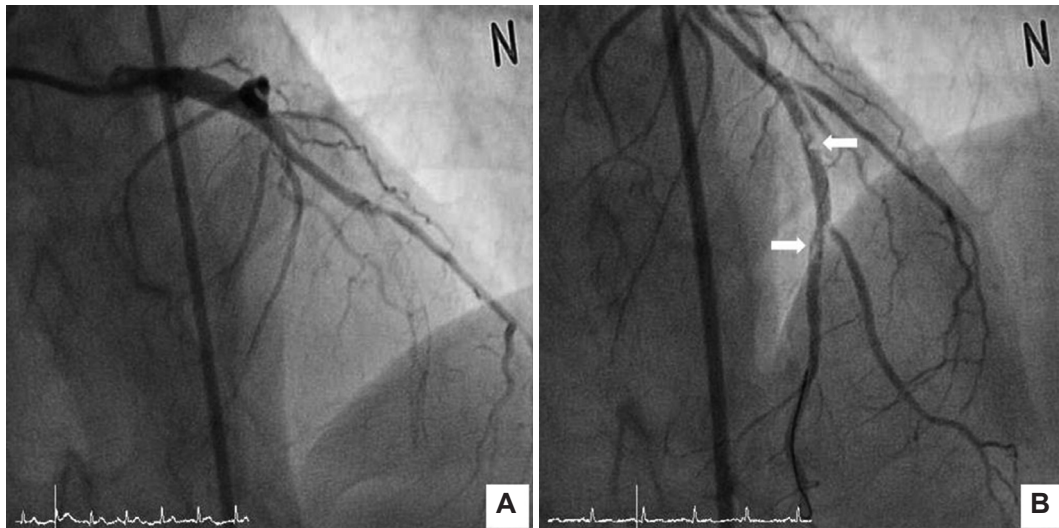


Fig. 5. Coronary angiography in the second stent thrombosis event. A: on hospital day 7, follow-up coronary angiography shows total occlusion of the mid left anterior descending coronary artery (the previously stented lesion). B: after aspiration thrombectomy and repeated balloon angioplasty, the intraluminal filling defects (arrows) with thrombus formations persist.

regional wall motion abnormalities (hypokinesia of the mid anterior septum). Emergent CABG was performed successfully by connecting the left internal mammary artery to the LAD, the saphenous vein graft to the diagonal branch, and the posterior descending artery.

Hypercoagulability laboratory study results after the second stent thrombosis event were as follows: positive (screen ratio: 1.5, confirm ratio: 1.3, normalized ratio: 1.2) lupus anticoagulant (LAC), which was reconfirmed after 9 months; aspirin reaction units (ARU): 633 (normal range: 0–549); and P2Y₁₂ inhibition rate of 0% (20–100%); while the other laboratory findings were normal {protein C activity of 85%, protein S activity of 105%, anti beta₂-glycoprotein 1 IgG level of 0.7 G units, factor V Leiden of the G/G pattern, homocysteine level of 9.5 μ mol/L, anti cardiolipin (aCL) IgG level below 9.4 GPLU/mL, anti cardiolipin IgM level below 9.4 MPLU/mL, and negative ANA}.

Therefore, we could make the confirmative diagnosis of APS because this patient had one clinical criterion of vascular thrombosis and one laboratory criterion of positive LAC according to the Sapporo criteria.⁵⁾ In addition, the patient also had resistance to dual antiplatelet therapy including aspirin and clopidogrel.

After successful bypass surgery, he was discharged on warfarin 6 mg qd, aspirin 100 mg qd, metoprolol 25 mg bid, isosorbide dinitrate 40 mg bid, hydroxychloroquine 300 mg, and the combination of ezetimibe (10 mg) and simvastatin (20 mg). He had no further episodes of chest pain or other complications during 3 months of outpatient follow-up.

Discussion

Stent thrombosis is a rare complication of PCI. The J-Cypher registry

showed that the incidence of Academic Research Consortium-defined definite stent thrombosis was 0.77% over 2 years of follow-up.⁶⁾ Although it is an uncommon complication, stent thrombosis is usually a fatal event that results in MI or sudden cardiac death.⁷⁾ There are many well-known predictors of stent thrombosis, which can be categorized into 4 groups: stent factors, patient factors, lesion characteristics, and procedural factors.⁴⁾ The patient factor such as aspirin and clopidogrel non-responsiveness, which could be one of the predisposing conditions for stent thrombosis, as well as APS, was also a potential cause of the thrombotic event.

Antiphospholipid syndrome is known as the most common acquired hypercoagulable clinical syndrome and its incidence is estimated to be up to 2%.⁸⁾ Diagnosis of APS can be confirmed based on one clinical criterion and one laboratory criterion.⁵⁾ Vascular (arterial or venous) thrombosis, or pregnancy morbidity are included in the clinical criteria and laboratory criteria include persistent positive aPL (LAC, aCL, anti-B₂-glycoprotein I antibody), at least 12 weeks apart.⁵⁾ Coronary artery disease and cerebrovascular disease are the major causes of mortality and morbidity in APS patients.^{2,9)} Perl et al.¹⁰⁾ reported that APS patients had higher rates of major adverse cardiac events driven by frequent target vessel revascularization. Because stent thrombosis and APS are rare, it is very difficult to demonstrate a relationship between these two conditions. But some case studies which have reported repeated stent thrombosis in patients with APS suggest that APS could be a strong contributing factor of stent thrombosis.^{11,12)}

This is the first case report of a patient with coexisting dual antiplatelet therapy non-responsiveness and APS. Although Middlebrooks et al.¹³⁾ reported a case of recurrent stent thrombosis with

co-existing clopidogrel resistance and increased anti-cardiolipin antibodies, the findings were not enough to confirm the diagnosis of APS because the level of anti-cardiolipin IgG did not meet the laboratory criteria (>40 GPL), but it was only slightly elevated (12 GPL).

The appropriate management of coronary artery disease in APS patients is controversial. There is no guideline for the optimal revascularization therapy (PCI or CABG), and efficacy and safety of drug eluting stents rather than bare metal stents in APS patients. Some case reports have documented successful PCI followed by aggressive anticoagulation therapy in APS patients presenting with acute MI.¹⁴⁾ Recurrent stent thrombosis after PCI in APS patients is often treated with CABG.¹²⁾ Therefore, the revascularization strategy in patients with APS should be individualized after taking into account the risk of thrombosis, restenosis, and bleeding. Aggressive control of risk factors such as hypertension, hyperlipidemia, smoking, diabetes mellitus, and obesity by both medical treatment and lifestyle modifications was strongly recommended. Hydroxychloroquine could be recommended for cardiac protection in APS patients by multifactorial mechanisms including benefit on active lupus, hyperlipidemia, anti-platelet effect, and reduction of aPL titers.¹⁵⁾

The optimal antithrombotic treatment for the first non-cerebral arterial thrombosis event such as MI in APS patients has not been well studied, while that for first ischemic stroke in patients with APS has been well documented in the Antiphospholipid Antibodies and Stroke Study.¹⁶⁾ Despite insufficient evidence, long-term warfarin therapy at a target International Normalized Ratio (INR) of 2–3 is empirically recommended in APS patients, particularly in those who are undergoing coronary revascularization or suffering from MI.¹⁵⁾¹⁷⁾ Increasing the intensity of warfarin to a higher target INR (2.5–3.5 or 3.0–4.0) or adding an antiplatelet agent to warfarin is recommended for the patient who has recurrent thrombosis despite optimal warfarin therapy for APS.¹⁷⁾ In the patients with catastrophic APS, which involves three or more organs, additional treatments such as high doses of steroids, intravenous immunoglobulin, and plasma exchange can be considered if the patient is in a life-threatening condition.¹⁷⁾

In this case, the patient had both APS and dual anti-platelet therapy non-responsiveness as predisposing factors for stent thrombosis. As well as APS, dual anti-platelet therapy non-responsiveness was another contributing factor for recurrent stent thrombosis. With respect to technical factors, overlapped long stent implantation could also be considered as one of the contributing factors of recurrent stent thrombosis with other thrombogenic conditions of APS and anti-platelet resistance. But, the use of Genous® stent (endothelial progenitor cell capturing stent) during the index procedure did not seem to be the contributing factor of stent thrombosis, because the recent negative results of the endothelial progenitor cell capturing stent were driven by the difference in target

lesion revascularization, and not by stent thrombosis.¹⁸⁾

This case report of recurrent stent thrombosis with APS and dual anti-platelet therapy non-responsiveness suggests that the evaluation of a stent thrombosis event should include evaluation for APS, beyond the well-documented predictors of stent thrombosis.

References

1. Wilson WA, Gharavi AE, Koike T, et al. International consensus statement on preliminary classification criteria for definite antiphospholipid syndrome: report of an international workshop. *Arthritis Rheum* 1999;42:1309-11.
2. Takeuchi S, Obayashi T, Toyama J. Primary antiphospholipid syndrome with acute myocardial infarction recanalised by PTCA. *Heart* 1998;79:96-8.
3. Ludia C, Domenico P, Monia C, et al. Antiphospholipid antibodies: a new risk factor for restenosis after percutaneous transluminal coronary angioplasty? *Autoimmunity* 1998;27:141-8.
4. van Werkum JW, Heestermans AA, Zomer AC, et al. Predictors of coronary stent thrombosis: the Dutch Stent Thrombosis Registry. *J Am Coll Cardiol* 2009;53:1399-409.
5. Miyakis S, Lockshin MD, Atsumi T, et al. International consensus statement on an update of the classification criteria for definite antiphospholipid syndrome (APS). *J Thromb Haemost* 2006;4:295-306.
6. Kimura T, Morimoto T, Nakagawa Y, et al. Antiplatelet therapy and stent thrombosis after sirolimus-eluting stent implantation. *Circulation* 2009;119:987-95.
7. Burzotta F, Parma A, Pristipino C, et al. Angiographic and clinical outcome of invasively managed patients with thrombosed coronary bare metal or drug-eluting stents: the OPTIMIST study. *Eur Heart J* 2008;29:3011-21.
8. Tripodi A, Chantarangkul V, Clerici M, Negri B, Galli M, Mannucci PM. Laboratory control of oral anticoagulant treatment by the INR system in patients with the antiphospholipid syndrome and lupus anticoagulant. Results of a collaborative study involving nine commercial thromboplastins. *Br J Haematol* 2001;115:672-8.
9. Cervera R, Piette JC, Font J, et al. Antiphospholipid syndrome: clinical and immunologic manifestations and patterns of disease expression in a cohort of 1,000 patients. *Arthritis Rheum* 2002;46:1019-27.
10. Perl L, Netzer A, Rechavia E, et al. Long-term outcome of patients with antiphospholipid syndrome who undergo percutaneous coronary intervention. *Cardiology* 2012;122:76-82.
11. Muir DF, Stevens A, Napier-Hemy RO, Fath-Ordoubadi F, Curzen N. Recurrent stent thrombosis associated with lupus anticoagulant due to renal cell carcinoma. *Int J Cardiovasc Intervent* 2003;5:44-6.
12. Weissman A, Coplan NL. Antiphospholipid antibody syndrome and acute stent thrombosis. *Rev Cardiovasc Med* 2006;7:244-6.
13. Middlebrooks EH, Panda M. Multiple recurrent stent thrombosis in a patient with coexisting clopidogrel resistance and increased anticardiolipin antibodies: a case report. *Case Rep Med* 2010;2010:974149.
14. Musuraca G, Imperadore F, Terraneo C, et al. Successful treatment of post-exertion acute myocardial infarction by primary angioplasty and

- stenting in a patient with antiphospholipid antibody syndrome. *Blood Coagul Fibrinolysis* 2004;15:95-8.
15. Lockshin M, Tenedios F, Petri M, et al. Cardiac disease in the antiphospholipid syndrome: recommendations for treatment. Committee consensus report. *Lupus* 2003;12:518-23.
 16. Levine SR, Brey RL, Tilley BC, et al. Antiphospholipid antibodies and subsequent thrombo-occlusive events in patients with ischemic stroke. *JAMA* 2004;291:576-84.
 17. Lim W, Crowther MA, Eikelboom JW. Management of antiphospholipid antibody syndrome: a systematic review. *JAMA* 2006;295:1050-7.
 18. Klomp M, Beijk MA, Varma C, et al. 1-year outcome of TRIAS HR (TRI-stent adjudication study-high risk of restenosis) a multicenter, randomized trial comparing genous endothelial progenitor cell capturing stents with drug-eluting stents. *JACC Cardiovasc Interv* 2011;4:896-904.