

Comparison of the McGrath videolaryngoscope and the Macintosh laryngoscope for double lumen endobronchial tube intubation in patients with manual in-line stabilization

A randomized controlled trial

Ji Young Yoo, MD^a, Sung Yong Park, MD^a, Jong Yeop Kim, MD^a, Myungseob Kim, MD^a, Seok Jin Haam, MD^b, Dae Hee Kim, MD^{a,*}

Abstract

Background: Double lumen endobronchial tube (DLT) intubation is commonly used for one-lung ventilation in thoracic surgery. However, because of its large size and shape, it is difficult to perform intubation compared with a single lumen tube. The aim of this randomized controlled trial was to determine whether the McGrath videolaryngoscope has any advantage over the direct Macintosh laryngoscope for DLT intubation in patients with a simulated difficult airway.

Methods: Forty-four patients (19–60 years of age); scheduled to undergo general anesthesia with one-lung ventilation were assigned to 1 of 2 groups: DLT intubation with the McGrath videolaryngoscope (ML group [n=22]); or conventional Macintosh laryngoscope (DL group [n=22]). After manual in-line stabilization was applied as a way of simulating a difficult airway, the time required for intubation and the quality of glottic view were evaluated.

Results: The time to successful intubation was not different between the 2 groups (ML group, 45 s [interquartile range, 38–52 s] versus DL group, 54 s [45–59 s]; $P = .089$). The McGrath videolaryngoscope, however, provided a significantly better glottic view. Modified Cormack and Lehane grade was better ($P < .001$), and the percentage of glottis opening score was higher in the ML group ($P < .001$). Overall intubation difficulty scale score was lower in the ML group (1 [0–2]) versus the DL group (3 [2–4]) ($P < .001$).

Conclusion: The McGrath videolaryngoscope improved glottic view and resulted in lower overall intubation difficulty scale score in patients with in-line stabilization.

Abbreviations: DLT = double lumen endobronchial tube, IDS = intubation difficulty scale, POGO = percentage of glottis opening.

Keywords: difficult intubation, double-lumen endobronchial tube, videolaryngoscope

1. Introduction

Difficulty in airway management represents 1 of the major problems in anesthesia practice. Recently, various types of the videolaryngoscope have been reported to play an important role

in patients with difficult intubation.^[1–3] The McGrath videolaryngoscope (Aircraft Medical, Edinburgh, Scotland), a portable device, provides a better laryngeal view than that obtained by direct Macintosh laryngoscopy, and several studies have reported that it provides improved laryngeal views and intubation conditions in patients with normal or difficult airways.^[4,5] Because truly difficult airways are very rare and dangerous, studies investigating intubation conditions of difficult airways are evaluated using “simulated difficult intubation” situations.^[6–12] One of the methods that has been proposed, manual in-line stabilization, can be applied as a way of simulating a difficult airway.^[12]

The double lumen endobronchial tube (DLT) is commonly used for one-lung ventilation in thoracic surgery. However, because of its large size and shape, it is difficult to intubate the trachea compared with a single lumen tube. Therefore, DLT intubation can be challenging and dangerous in patients with known or suspected difficult airways.^[13] Although applications of videolaryngoscopy for DLT placement have been reported, many studies have focused on the utility of videolaryngoscopy in patients with normal airway status.^[13–19] In patients with difficult airway, there are a few case reports describing the utility of videolaryngoscopy with placement of DLT.^[20,21] The aim of this randomized controlled trial was to determine whether the McGrath videolaryngoscope has any advantage over the

Editor: Helen Gharaei.

Clinical trial registration: KCT0002150

Funding: This research received no specific grants from any funding agencies in the public, commercial, or not-for-profit sectors.

The authors have no conflicts of interest to disclose.

^a Department of Anesthesiology and Pain Medicine, ^b Department of Cardiovascular and Thoracic Surgery, Ajou University School of Medicine, Suwon, Korea.

* Correspondence: Dae Hee Kim, Department of Anesthesiology and Pain Medicine, Ajou University School of Medicine, 164, Worldcup-ro, Yeongtong-gu, Suwon, 16499, Korea (e-mail: anekim@ajou.ac.kr).

Copyright © 2018 the Author(s). Published by Wolters Kluwer Health, Inc. This is an open access article distributed under the Creative Commons Attribution-NoDerivatives License 4.0, which allows for redistribution, commercial and non-commercial, as long as it is passed along unchanged and in whole, with credit to the author.

Medicine (2018) 97:10(e0081)

Received: 1 August 2017 / Received in final form: 17 January 2018 / Accepted: 13 February 2018

<http://dx.doi.org/10.1097/MD.00000000000010081>

direct Macintosh laryngoscope for DLT intubation in patients with a simulated difficult airway.

2. Methods

This study was a single center, prospective, open-label, randomized-controlled, superiority trial with 2 parallel groups. The study was approved by the Institutional Review Board of Ajou University Hospital (AJIRB-DEV-OBS-16-108) and internationally registered for clinical trials (KCT0002150). Written informed consent was obtained from each patient. Forty-four patients, 19 to 60 years of age, scheduled for thoracic surgery and requiring one-lung ventilation were included. They were randomly allocated to 1 of 2 groups using a computer-generated random number table: DLT intubation with conventional Macintosh laryngoscope (group DL [n=22]) and the McGrath videolaryngoscope (group ML [n=22]) (Fig. 1). Patients were excluded from the study if they required rapid-sequence intubation, had a history of difficult intubation, cervical spine instability or cervical myelopathy, or a tendency to bleed.

Patient characteristics, including age, sex, and American Society of Anesthesiologists physical status, were recorded. Routine airway assessment was performed including Mallampati scoring,^[22] and the measurement of thyromental distance, and mouth opening (inter-incisor distance).

No premedication was administered before surgery. Electrocardiogram, pulse oximetry, noninvasive blood pressure, and end-tidal CO₂ concentration were monitored at 1 to 5 minutes intervals. The depth of anesthesia was monitored using a bispectral index monitor (BIS VISTA monitor [4-electrode sensor], Aspect Medical Systems, Norwood, MA). Baseline measurements were obtained, and 1 minute of preoxygenation was performed before the induction of general anesthesia.

Anesthesia was induced using intravenous propofol (1.5 mg/kg) and effect-site target-controlled infusion of remifentanyl (effect-site concentration 2 ng/mL). Remifentanyl infusion began at the time of anesthetic induction. After patients stopped responding to verbal commands, rocuronium (0.6 mg/kg) was

administered intravenously. The patient's lungs were ventilated using 100% oxygen and 2% sevoflurane. After confirming a BIS value < 60 and neuromuscular blockade, manual in-line stabilization of the cervical spine was applied by an experienced study investigator (D.H.K.) in a standardized manner by grasping the patient's mastoid process and occiput, to limit movement of the head and the cervical spine during intubation.

Intubation was performed by 1 anesthetist (S.Y.P.) with experience in DLT (Mallinckrodt, Broncho-Cath, Covidien, Tullamore, Ireland [male: 37 Fr, female: 35 Fr]) placement using both McGrath and Macintosh laryngoscopes. The DLT was lubricated well, a stylet was inserted into the DLT to facilitate tracheal intubation, and the distal tip was bent immediately proximal to the cuff in all patients. Successful ventilation was confirmed by visible chest rise and capnograph confirmation. Intubation was defined as failed if it could not be performed within 120 seconds or in 2 attempts, esophageal intubation, or if the anesthetist believed that a repeat attempt would be unsafe. The operator was not blinded to the type of laryngoscope, and was not involved in the collection of data, except for Cormack and Lehane grade,^[23] and the percentage of glottis opening (POGO).^[24] In the event of failed intubation, manual in-line stabilization was terminated to facilitate tracheal intubation. In both groups, a flexible fiberoptic bronchoscope (PortaView LF-DP; Olympus Optical Company, Tokyo, Japan) with a diameter of 3.1 mm was used to confirm the correct positioning of the DLT in the left main bronchus. Blood pressure and heart rate were measured before and 1 minute after induction of anesthesia, and before and 1 minute after intubation. Sevoflurane (1–2%) and remifentanyl infusion was used for the maintenance of anesthesia.

The primary outcome measure of the study was intubation time with DLT, defined as the time from when the laryngoscope passed between the patient's lips to the confirmation of end-tidal carbon dioxide on the capnograph, estimated by an independent observer. If more than 1 intubation attempt was required, the duration of the subsequent attempt was added to that of the first attempt without including the time interval between attempts. In the data analyses, only intubation time for successful tracheal

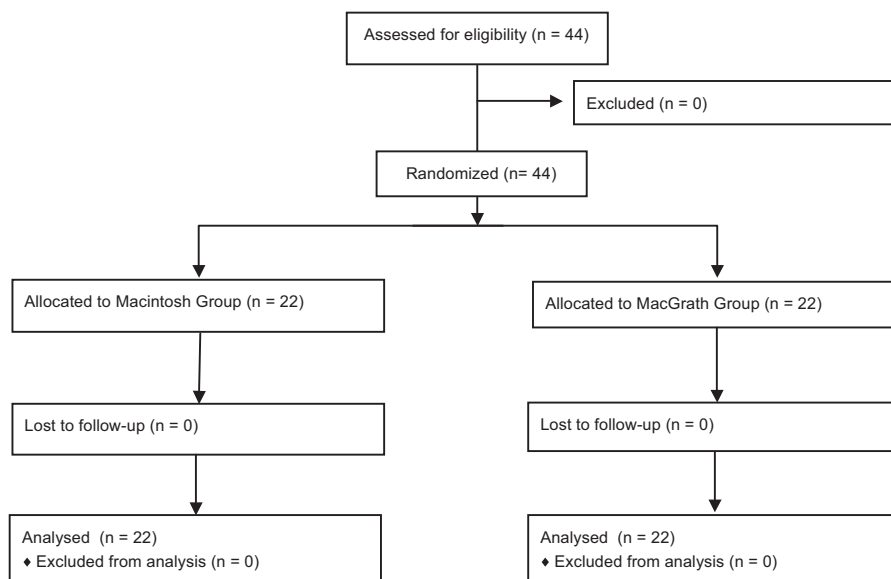


Figure 1. CONSORT flow diagram of recruitment and assessment of study participants.

intubations was analyzed. The secondary outcomes were glottis view (Cormack and Lehane grade), rate of successful intubation, POGO, the use of external laryngeal manipulation, intubation difficulty scale (IDS),^[25] and oral mucosal bleeding by a blinded anesthetist.

The results of a preliminary study involving 10 patients demonstrated that the mean time to intubation using the McGrath videolaryngoscope was 49.8 ± 11.5 seconds, whereas that with the Macintosh laryngoscopes was 69.5 ± 23.3 seconds. To detect differences with 80% power at a 5% significance level, 20 patients would be necessary in each group. Therefore, the plan was to recruit 22 patients for each group considering the drop out.

Statistical analysis was performed using SPSS version 13.0 (SPSS Inc., Chicago, IL), and R (version 3.0.1, Foundation for Statistical Computing, Vienna, Austria) for Windows (Microsoft Corporation, Redmond, WA). The Mann-Whitney *U* test was used to assess intubation time, POGO score, and IDS. The Fisher's exact test was used to assess the number of failed intubations, Cormack and Lehane classification, the use of external laryngeal manipulation, oral bleeding. Continuous and categorical data are expressed as median [interquartile range] and number of patients, respectively; $P < .05$ was considered to be statistically significant.

3. Results

A total of 44 patients were randomly assigned to 1 of the 2 groups. Patient characteristics and assessment of airway measurements are summarized in Table 1. There was no significant difference in patient age, sex, body weight, height, American Society of Anesthesiologists physical status, thyromental distance, mouth opening, and Mallampati score between the 2 groups.

Factors related to airway management in each group are summarized in Table 2. The intubation time was not different between the 2 groups (group ML, 45 s [IQR 38–52 s] vs group DL, 54 s [IQR 45–59 s]; $P = .089$). Successful intubation was performed for 21 (95.5%) patients in group ML and 17 (77.3%) in group DL ($P = .19$). In group ML, 1 patient failed tracheal intubation, with duration > 120 seconds. There were 5 failed patients in the DL group, with duration > 120 seconds in 4 patients and esophageal intubation in 1 patient.

There was a significantly better view of the glottis in group ML. Cormack and Lehane grade was better ($P < .001$) and POGO score was higher ($P < .001$) in group ML. External laryngeal

Table 1
Patient characteristics and airway assessments.

	Group DL	Group ML
Age	47 [43–53]	48 [46–55]
Sex, male/female	14/8	14/8
Height, cm	164 [161–170]	167 [163–170]
Body weight, kg	67 [62–72]	63 [58–73]
ASA PS, 1/2/3/4	17/5/0/0	19/3/0/0
Thyromental distance, cm	9.0 [8.0–9.8]	7.8 [7.0–9.4]
Mouth opening, cm	5.0 [4.0–6.0]	5.0 [4.5–6.0]
Mallampati score, 1/2/3/4	12/7/3/0	13/4/4/1

Values are median [interquartile range] or number. No differences were observed between the 2 groups. Group DL, double lumen endobronchial tube intubation with conventional Macintosh laryngoscope; group ML, double lumen endobronchial tube intubation with McGrath videolaryngoscope; ASA PS: American Society of Anesthesiologists Physical Status.

Table 2
Comparison of factors related to airway management.

	Group DL	Group ML	<i>P</i> value
Intubation time, seconds	54 [45–59]	45 [38–52]	.089
Success/Fail	17/5	21/1	.188
C-L grade, 1/2/3/4	3/9/10/0	15/6/1/0	$< .001^*$
POGO score	30 [10–68]	80 [63–100]	$< .001^*$
IDS	3 [2–4]	1 [0–2]	$< .001^*$
ELM	13	1	$< .001^*$
Oral bleeding	3	1	.607

Values are median [interquartile range] or number. group DL, double lumen endobronchial tube intubation with conventional Macintosh laryngoscope; group ML, double lumen endobronchial tube intubation with McGrath videolaryngoscope; C-L grade, modified Cormack–Lehane grade; POGO, percentage of glottis opening; IDS, intubation difficulty scale; ELM, external laryngeal manipulation. $^*P < .05$ was considered significant.

manipulation for tracheal intubation was necessary in 13 patients (59%) in group DL and 1 patient (4.5%) in group ML ($P < .001$). IDS was lower in group ML (1 [IQR 0–2]) than in group DL (3 [IQR 2–4]) ($P < .001$). There were no differences in the incidence of oral bleeding ($P = .607$).

The hemodynamic variables were comparable between the 2 groups and are summarized in Table 3. There were no episodes of hypoxia ($\text{SaO}_2 < 95\%$) during the procedure.

4. Discussion

This study demonstrated that the McGrath videolaryngoscope improved glottic view and decreased the needs for external laryngeal manipulation for DLT tracheal intubation, resulting in an overall lower IDS score in patients with in-line stabilization compared with conventional Macintosh laryngoscope.

Although the time to successful intubation was shorter when using the McGrath videolaryngoscope, this difference was not

Table 3
Hemodynamic data.

	Group DL	Group ML	<i>P</i> value
SBP, mm Hg			
Baseline	141 [137–151]	136 [128–160]	.557
After 1 minute	124 [109–131]	113 [96–116]	.019
Before intubation	107 [97–115]	104 [88–114]	.627
After intubation	160 [146–176]	141 [134–170]	.116
DBP, mm Hg			
Baseline	83 [76–92]	83 [79–89]	.742
After 1 min	78 [66–85]	71 [63–75]	.177
Before intubation	66 [54–71]	64 [50–74]	.662
After intubation	100 [94–107]	98 [86–104]	.307
MBP, mm Hg			
Baseline	98 [90–104]	95 [92–104]	.972
After 1 minute	88 [78–95]	81 [67–85]	.091
Before intubation	74 [66–80]	73 [61–81]	.798
After intubation	113 [106–126]	109 [92–123]	.301
HR, beat/min			
Baseline	77 [70–90]	82 [71–94]	.438
After 1 minute	73 [66–84]	76 [69–85]	.474
Before intubation	71 [64–79]	77 [67–82]	.268
After intubation	87 [83–98]	92 [80–103]	.431

Values are median [interquartile range]. Group DL, double lumen endobronchial tube intubation with conventional Macintosh laryngoscope; group ML, double lumen endobronchial tube intubation with McGrath videolaryngoscope; SBP, systolic blood pressure; DBP, diastolic blood pressure; MBP, mean blood pressure; Baseline, before induction of anesthesia; After 1 minute: 1 minute after induction of anesthesia; After intubation: 1 minute after intubation.

statistically significant. It is possible that our results underestimated the intubation time in the DL group,^[12] because the intubation times for the 5 failures in group DL were excluded from data analysis. Intuitively, it is predictable that more time is required for endotracheal intubation in patients with failed or difficult intubation. In fact, in this study, the time required for intubation, including patients who failed tracheal intubation, was significantly shorter in the ML group compared with the DL group (group ML, 46 s [IQR 39–53 s] vs group DL, 57 s [IQR 47–84 s]; $P = .016$).

Because suboptimal visualization of the glottis often leads to difficult tube placement, a complete view of the glottis is required for successful intubation.^[26] In this respect, videolaryngoscopy has an advantage compared with conventional Macintosh laryngoscopy. Several studies have demonstrated the superiority of videolaryngoscopy for providing intubating conditions,^[4,5] and this benefit is more pronounced in conditions of difficult airway.^[27,28] However, according to some studies, a satisfactory laryngeal view does not always guarantee successful intubation.^[12,28–30] In studies comparing videolaryngoscopy with conventional Macintosh laryngoscopy for tracheal intubation, the videolaryngeal view quality was superior in videolaryngoscopy; however, intubation time and difficulty were controversial. Taylor et al^[12] found that the McGrath laryngoscope improved laryngeal view and success rate in intubation of simulated difficult airway but delayed time to intubation (McGrath, 35.8 ± 20.4 s vs Macintosh, 21.7 ± 9.4 s). The reason for this discrepancy is the geometrical mismatch between the blade and the laryngeal anatomy of the patient.^[30] The McGrath videolaryngoscope incorporates a more acute angulated blade than the conventional Macintosh blade, in an attempt to optimize the view of the glottis. A common problem is that the tip of endotracheal tube can be located posterior to the glottis.^[31] To overcome difficulties with tube manipulation, specific maneuvers could help: the addition of a stylet; and manipulation of the tube angle before insertion essentially compensates for the geometrical shortcoming of the blade design.^[30] In our study, the tube was shaped using a malleable stylet (Mallinckrodt, Mansfield, MA) to replicate the curve of the Macintosh or McGrath laryngoscope, as appropriate. With this manipulation, advancing the DLT bronchial tip until it reaches the vocal cord was significantly easier. However, in another study, a satisfactory glottis view resulted in decreased intubation time and a high success rate. Kido et al^[16] found that the intubation success rate and laryngeal view were superior; consequently, the intubation time was shorter in the McGrath group (17.1 ± 4.6 s) versus the Macintosh group (20.8 ± 5.9 s) ($P = .026$).

Difficulty in passing the angulated endotracheal tube through the glottis has been also reported.^[1,32] In the present study, 1 patient in the ML group failed tracheal intubation at the first attempt, with duration > 120 seconds. The Cormack Lehane glottic grade was 2 and POGO score was 40 in this patient; however, we experienced difficulty in passing a DLT through the glottis because the tip of the DLT impinged on the anterior wall of the trachea because of the stylet's angle. In this case, withdrawal of the stylet, approximately 3 to 4 cm and slight rotation of the tube, facilitated the tube's passage into the trachea.^[1,33]

Recently, many videolaryngoscopes have been proposed as promising alternatives to the conventional laryngoscope.^[34] However, difficult DLT endobronchial intubation using videolaryngoscopes was only documented in case series and a retrospective study.^[17,20,21] For the present prospective randomized controlled study, we applied in-line stabilization as a simulated difficult airway. Manual in-line stabilization was used to simulate 1 type of difficult direct laryngoscope scenario,

because it increases rates of failed intubation, secondary to adverse impact on the laryngeal view during direct laryngoscopy.^[12,35–37] To our knowledge, this was the first study to evaluate the utility of videolaryngoscopy for intubation of DLT in patients with simulated difficult airway.

This study had several limitations. First, a difficult airway situation cannot be generalized to manual in-line stabilization. This situation was used to simulate only limited head and neck movement.^[12] Another maneuver creating difficult-to-intubate situations is cervical collars.^[6,9–11] Cervical collars restrict neck movement and also limit mouth opening, thus leading to far more difficult intubation conditions than manual in-line stabilization.^[7,9] Second, the operator was not blinded to the laryngoscope device used; consequently, the potential for bias exists. Third, the DLT endobronchial intubation was only performed by 1 experienced anesthetist; this may, therefore, not be translatable to less experienced anesthesia providers.

In conclusion, compared with direct Macintosh laryngoscope, the McGrath videolaryngoscope provided a better laryngeal view and easier conditions for DLT intubation in simulated difficult intubation scenarios. These findings suggest that the McGrath videolaryngoscope may be a feasible option for DLT intubation in patients with predicted or actual difficult airway conditions.

References

- Rai MR, Dering A, Verghese C. The Glidescope system: a clinical assessment of performance. *Anaesthesia* 2005;60:60–4.
- Asai T. Videolaryngoscopes: do they truly have roles in difficult airways? *Anesthesiology* 2012;116:515–7.
- Asai T, Muraio K, Shingu K. Training method of applying pressure on the neck for laryngoscopy: use of a videolaryngoscope. *Anaesthesia* 2003;58:602–3.
- Shippey B, Ray D, McKeown D. Case series: the McGrath videolaryngoscope—an initial clinical evaluation. *Can J Anaesth* 2007;54:307–13.
- Shippey B, Ray D, McKeown D. Use of the McGrath videolaryngoscope in the management of difficult and failed tracheal intubation. *Br J Anaesth* 2008;100:116–9.
- Byhahn C, Iber T, Zacharowski K, et al. Tracheal intubation using the mobile C-MAC video laryngoscope or direct laryngoscopy for patients with a simulated difficult airway. *Minerva Anestesiol* 2010;76:577–83.
- Enomoto Y, Asai T, Arai T, et al. Pentax-AWS, a new videolaryngoscope, is more effective than the Macintosh laryngoscope for tracheal intubation in patients with restricted neck movements: a randomized comparative study. *Br J Anaesth* 2008;100:544–8.
- McElwain J, Laffey JG. Comparison of the C-MAC(R), Airtraq(R), and Macintosh laryngoscopes in patients undergoing tracheal intubation with cervical spine immobilization. *Br J Anaesth* 2011;107:258–64.
- Liu EH, Goy RW, Tan BH, et al. Tracheal intubation with videolaryngoscopes in patients with cervical spine immobilization: a randomized trial of the Airway Scope and the GlideScope. *Br J Anaesth* 2009;103:446–51.
- Theiler L, Hermann K, Schoettker P, et al. SWIVIT—Swiss video-intubation trial evaluating video-laryngoscopes in a simulated difficult airway scenario: study protocol for a multicenter prospective randomized controlled trial in Switzerland. *Trials* 2013;14:94.
- Bathory I, Frascarolo P, Kern C, et al. Evaluation of the GlideScope for tracheal intubation in patients with cervical spine immobilisation by a semi-rigid collar. *Anaesthesia* 2009;64:1337–41.
- Taylor AM, Peck M, Launcelott S, et al. The McGrath(R) Series 5 videolaryngoscope vs the Macintosh laryngoscope: a randomised, controlled trial in patients with a simulated difficult airway. *Anaesthesia* 2013;68:142–7.
- Yao WL, Wan L, Xu H, et al. A comparison of the McGrath(R) Series 5 videolaryngoscope and Macintosh laryngoscope for double-lumen tracheal tube placement in patients with a good glottic view at direct laryngoscopy. *Anaesthesia* 2015;70:810–7.
- Yang M, Kim JA, Ahn HJ, et al. Double-lumen tube tracheal intubation using a rigid video-stylet: a randomized controlled comparison with the Macintosh laryngoscope. *Br J Anaesth* 2013;111:990–5.

- [15] Hsu HT, Chou SH, Chen CL, et al. Left endobronchial intubation with a double-lumen tube using direct laryngoscopy or the Trachway(R) video stylet. *Anaesthesia* 2013;68:851–5.
- [16] Kido H, Komazawa N, Matsunami S, et al. Comparison of McGrATH MAC and Macintosh laryngoscopes for double-lumen endotracheal tube intubation by anesthesia residents: a prospective randomized clinical trial. *J Clin Anesth* 2015;27:476–80.
- [17] Purugganan RV, Jackson TA, Heir JS, et al. Video laryngoscopy versus direct laryngoscopy for double-lumen endotracheal tube intubation: a retrospective analysis. *J Cardiothorac Vasc Anesth* 2012;26:845–8.
- [18] Lin W, Li H, Liu W, et al. A randomised trial comparing the CEL-100 videolaryngoscope(TM) with the Macintosh laryngoscope blade for insertion of double-lumen tubes. *Anaesthesia* 2012;67:771–6.
- [19] Russell T, Slinger P, Roscoe A, et al. A randomised controlled trial comparing the GlideScope(R) and the Macintosh laryngoscope for double-lumen endobronchial intubation. *Anaesthesia* 2013;68:1253–8.
- [20] Poon KH, Liu EH. The Airway Scope for difficult double-lumen tube intubation. *J Clin Anesth* 2008;20:319.
- [21] Hughes CG, Mathews L, Easdown J, et al. The McGrath video laryngoscope in unstable cervical spine surgery: a case series. *J Clin Anesth* 2010;22:575–6.
- [22] Mallampati SR, Gatt SP, Gugino LD, et al. A clinical sign to predict difficult tracheal intubation: a prospective study. *Can Anaesth Soc J* 1985;32:429–34.
- [23] Yentis SM, Lee DJ. Evaluation of an improved scoring system for the grading of direct laryngoscopy. *Anaesthesia* 1998;53:1041–4.
- [24] Ochroch EA, Hollander JE, Kush S, et al. Assessment of laryngeal view: percentage of glottic opening score vs Cormack and Lehane grading. *Can J Anaesth* 1999;46:987–90.
- [25] Adnet F, Borron SW, Racine SX, et al. The intubation difficulty scale (IDS): proposal and evaluation of a new score characterizing the complexity of endotracheal intubation. *Anesthesiology* 1997;87:1290–7.
- [26] Campos JH, Hallam EA, Van Natta T, et al. Devices for lung isolation used by anesthesiologists with limited thoracic experience: comparison of double-lumen endotracheal tube, Univent torque control blocker, and Arndt wire-guided endobronchial blocker. *Anesthesiology* 2006;104:261–6. discussion 5A.
- [27] O'Leary AM, Sandison MR, Myneni N, et al. Preliminary evaluation of a novel videolaryngoscope, the McGrath series 5, in the management of difficult and challenging endotracheal intubation. *J Clin Anesth* 2008;20:320–1.
- [28] Noppens RR, Mobus S, Heid F, et al. Evaluation of the McGrath Series 5 videolaryngoscope after failed direct laryngoscopy. *Anaesthesia* 2010;65:716–20.
- [29] Sun DA, Warriner CB, Parsons DG, et al. The GlideScope Video Laryngoscope: randomized clinical trial in 200 patients. *Br J Anaesth* 2005;94:381–4.
- [30] van Zundert A, Maassen R, Lee R, et al. A Macintosh laryngoscope blade for videolaryngoscopy reduces stylet use in patients with normal airways. *Anesth Analg* 2009;109:825–31.
- [31] Niforopoulou P, Pantazopoulos I, Demestihia T, et al. Video-laryngoscopes in the adult airway management: a topical review of the literature. *Acta Anaesthesiol Scand* 2010;54:1050–61.
- [32] Xue FS, Zhang GH, Liu J, et al. The clinical assessment of glidescope in orotracheal intubation under general anesthesia. *Minerva Anesthesiol* 2007;73:451–7.
- [33] Pott LM, Murray WB. Review of video laryngoscopy and rigid fiberoptic laryngoscopy. *Curr Opin Anaesthesiol* 2008;21:750–8.
- [34] Thong SY, Lim Y. Video and optic laryngoscopy assisted tracheal intubation—the new era. *Anaesth Intensive Care* 2009;37:219–33.
- [35] Nolan JP, Wilson ME. Orotracheal intubation in patients with potential cervical spine injuries. An indication for the gum elastic bougie. *Anaesthesia* 1993;48:630–3.
- [36] Thiboutot F, Nicole PC, Trepanier CA, et al. Effect of manual in-line stabilization of the cervical spine in adults on the rate of difficult orotracheal intubation by direct laryngoscopy: a randomized controlled trial. *Can J Anaesth* 2009;56:412–8.
- [37] Wood PR. Direct laryngoscopy and cervical spine stabilisation. *Anaesthesia* 1994;49:77–8.