

- Armed Forces Institute of Pathology, in honor of Franz M. Enzinger, MD. *Ann Diagn Pathol* 2007;11:313-319.
4. Taher A, Pushpanathan C. Plexiform fibrohistiocytic tumor: a brief review. *Arch Pathol Lab Med* 2007;131:1135-1138.
5. Shido K, Fujimura T, Kakizaki A, Furudate S, Asano M, Aiba S. Plexiform fibrohistiocytic tumor on the ear: case report and immunohistochemical investigation of stromal factor. *Case Rep Dermatol* 2016;8:26-30.

<https://doi.org/10.5021/ad.2018.30.3.375>



Decreased Galectin-3 and -7 Expressions in Old-Aged Skin and Their Differential Expression in Skin Equivalents

Jee Woong Choi, Kyung Mi Nam¹, Hye Ryung Choi¹, Dong Hun Lee², Chang Hun Huh¹, Kyung Chan Park¹

Department of Dermatology, Ajou University School of Medicine, Suwon, ¹*Department of Dermatology, Seoul National University Bundang Hospital, Seoul National University College of Medicine, Seongnam,* ²*Department of Dermatology, Seoul National University Hospital, Seoul National University College of Medicine, Seoul, Korea*

Dear Editor:

Galectins are a family of soluble β -galactoside-binding lectins that share a unique carbohydrate recognition domain. Among the various galectins, galectin-3 and galectin-7 are of great interest in the field of cutaneous biology. These galectins are found abundantly in the cytoplasm of epidermal keratinocytes and are associated with cutaneous wound healing through the promotion of reepithelialization¹.

Given the relationship between wound healing process and galectins, we studied the expression patterns of galectin-3 and -7 in human skin of different ages and two distinct skin equivalent (SE) models. Because aging affects the wound healing and repair processes, we assume that their expression patterns vary with respect to age and characteristics of SEs.

Nine healthy individuals of different ages (6~80 years old) were enrolled. All skin samples were from the non-exposed areas (buttocks) to rule out the effects of ultraviolet

exposure on galectin expression². Additionally, two different SE models were reconstructed according to the method as described previously³. Human keratinocytes and fibroblasts were isolated from human foreskins obtained during circumcision. Keratinocytes were cultured in two distinct dermal equivalents, one prepared by standard stock solutions and the other by standard stock solutions and adjuvants (hyaluronic acid and Cervi cornus Colla). We previously reported that these adjuvants are helpful by enhancing the formation of epidermis and basement membranes³. This study was approved by Seoul National University Bundang Hospital Institutional Review Board (IRB no. 1305/202-004 and 1207/164-003).

Immunohistochemical staining was performed on paraffin sections. For immunofluorescence study, the sections were incubated overnight at 4°C with an antibody directed against galectin-3 (B2C10; Santa Cruz Biotechnology, Santa Cruz, CA, USA) and galectin-7 (G-3; Santa Cruz Bio-

Received March 10, 2017, Revised May 24, 2017, Accepted for publication June 11, 2017

Corresponding author: Kyung Chan Park, Department of Dermatology, Seoul National University Bundang Hospital, 82 Gumi-ro 173beon-gil, Bundang-gu, Seongnam 13620, Korea. Tel: 82-31-787-7311, Fax: 82-31-787-4058, E-mail: gcpark@snu.ac.kr
ORCID: <https://orcid.org/0000-0002-8994-8038>

This is an Open Access article distributed under the terms of the Creative Commons Attribution Non-Commercial License (<http://creativecommons.org/licenses/by-nc/4.0>) which permits unrestricted non-commercial use, distribution, and reproduction in any medium, provided the original work is properly cited.

Copyright © The Korean Dermatological Association and The Korean Society for Investigative Dermatology

technology). After washing, the samples were incubated with secondary antibodies for 2 hours and then stained with 4,6-diamino-2-phenylindole (DAPI) at 1 μ g/ml for 10 minutes. In confocal microscope images, galectin-3 and -7 were shown as the green and the red color, respectively. Cell nuclei were also counterstained with DAPI. For each sample on a slide, three non-overlapping areas with similar cell numbers were captured with the same magnification. Photomicrographs were acquired using the same illumination and exposure time for every section. Image analysis was performed in the two areas of interest, whole epidermis and the basal layer using Image Pro-Plus 6.0 (MediaCybernetics Inc., Rockville, MD, USA). To quanti-

fy the galectin expression of the area, we used the intensity analysis methods previously described by Arqués et al.⁴. The signal intensity was calculated and noted as relative units (RUs).

In immunofluorescence images, galectin-3 and -7 were mainly stained in the cytoplasm rather than the nucleus of the cells. These galectins were observed throughout the epidermis, and staining intensity became more intense in the upper layers of the epidermis. With respect to age, fluorescence intensities of both galectins were stronger in young skin than in old skin. In the dermis, there were scattered foci of positive staining of galectin-3; however, galectin-7 was not detected at all (Fig. 1).

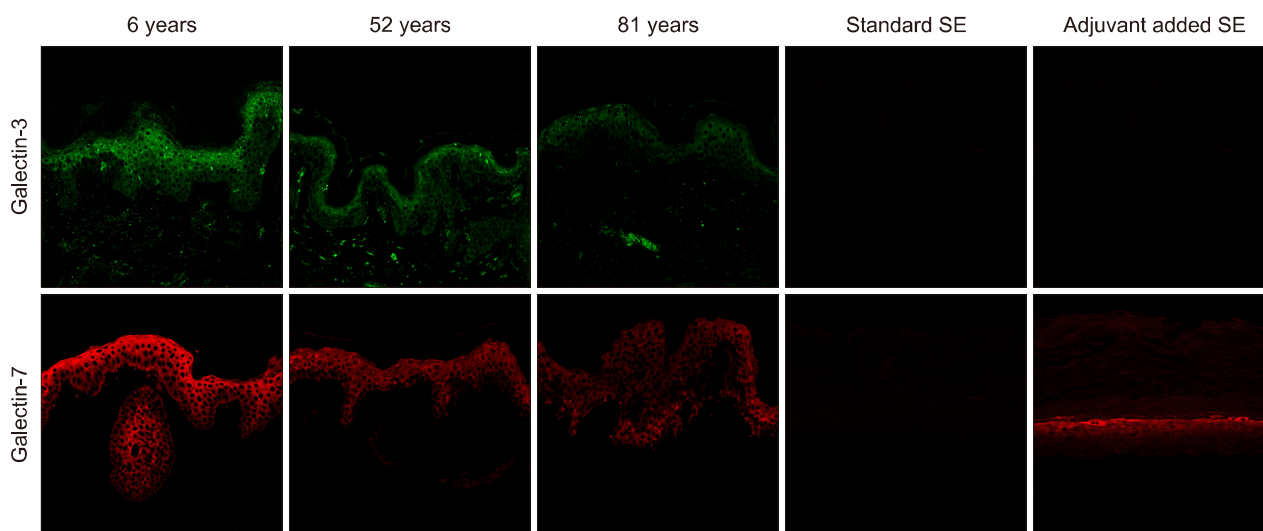


Fig. 1. Expression of galectin-3 and -7 in human normal skin according to age and skin equivalents (SEs). Expression of galectin-3 and -7 was dependent on the differentiation status as well as age in normal keratinocytes. Galectin-7 is only expressed in the adjuvant added SE model.

Table 1. The level of galectin expression per keratinocyte in human normal skin according to age and skin equivalents

Age (yr)	Galectin-3		Galectin-7	
	Per epidermal keratinocyte (RU)	Per basal keratinocyte (RU)	Per epidermal keratinocyte (RU)	Per basal keratinocyte (RU)
6	31,879 ± 3,132	13,059 ± 3,200	75,542 ± 4,611	36,697 ± 4,610
13	29,944 ± 2,500	11,552 ± 1,894	52,835 ± 9,472	24,223 ± 2,135
29	23,992 ± 2,395	8,039 ± 558	42,673 ± 3,580	15,975 ± 2,762
45	20,369 ± 1,813	7,962 ± 1,348	41,192 ± 3,794	15,471 ± 2,208
58	14,604 ± 2,023	5,137 ± 1,146	38,979 ± 2,597	14,369 ± 1,917
60	15,387 ± 3,002	5,810 ± 1,569	39,919 ± 4,876	12,007 ± 4,029
66	12,335 ± 1,229	3,990 ± 490	33,856 ± 1,748	9,657 ± 2,336
69	12,438 ± 2,330	5,109 ± 604	33,669 ± 2,907	9,792 ± 1,743
80	11,366 ± 2,277	3,142 ± 558	22,818 ± 4,046	6,388 ± 1,503
Standard SE model	ND	ND	ND	ND
Adjuvant added SE model	ND	ND	38,760 ± 4,561	11,751 ± 2,254

Values are presented as mean ± standard deviation. RU: relative unit, SE: skin equivalent, ND: not detected.

The level of expression for galectin-3 (or galectin-7) per keratinocyte in the epidermis were calculated as shown in Table 1. Data represent the mean RU \pm standard deviation from three different fields of each sample slide. In normal skin, RUs of basal keratinocytes were as low as about one-half to one-third that of epidermal keratinocytes. This suggests that there were more galectin expressions as there were more differentiated keratinocytes. In addition, RUs of both galectin-3 and -7 also decreased with aging. Decreasing trends of RUs were similar for both galectins. In immunofluorescence images of SEs, both models of SEs were not stained with galectin-3. However, adjuvant added SEs were strongly stained with galectin-7 (Fig. 1), and the expression patterns of galectin-7 in SEs were similar to those of human skin samples in 60s (Table 1).

Our results showed that there was an age-dependent decrease in the level of galectin-3 and -7 expressions in keratinocytes and basal keratinocytes. Recent studies revealed a close association of galectin-3 and -7 with the cutaneous wound repair process regarding their effects on migration and regeneration of basal keratinocyte⁵⁻⁸. These galectins can be secreted by keratinocytes that are either proliferative, quiescent, or differentiable. Once secreted, the galectins can autocrinely or paracrinely modulate the early phases of wound healing by cross-linking the galectin ligands on various cells¹. Although most of the epidermal stem cells with replicative potential exist within the basal layer—where both galectins are found in small amounts—the galectins secreted from the upper epidermal layers can paracrinely affect the basal epidermal stem cells, as well as the differentiable keratinocytes when a cutaneous wound has occurred^{9,10}. Thus, galectin may have an important role in wound healing through not only promoting epidermal stem cell replication, but also accelerating keratinocyte migration. Through a combination of intrinsic and extrinsic aging, human skin undergoes several age-related epidermal changes, including increased time for keratinocyte migration and diminished replicative capacity of basal keratinocytes. These changes can potentially affect the process of wound healing. Therefore, we propose that a low level of galectin-3 and -7 expressions in the skin of aged subjects may likely be a contributing factor for delayed wound healing.

The present study also showed that the expression of galectin-3 and -7 is dependent on the differentiation status in normal keratinocytes. We also found a high level of galectin-3 expression in the dermis whereas galectin-7 expression was not observed. Interestingly, only adjuvant added SE model was stained with galectin-7. Because our group showed that these adjuvants are helpful for the reconstruction of SEs with good basal cell activity and epi-

dermal differentiation³, these findings suggest that galectin-7 is a more sensitive marker for good basal keratinocyte activity and epidermal differentiation than galectin-3.

In conclusion, this study has demonstrated that galectin-3 and -7 in the epidermis are decreased in an age-dependent manner, possible association with impaired wound healing of the old. In addition, galectin-7 seems to be a more sensitive marker for differentiated and active keratinocytes.

ACKNOWLEDGMENT

This study was supported by a grant from the Korean Health Technology R&D Project, Ministry of Health & Welfare, Korea (grant number: HN14C0094). This work was also supported by the Technology Innovation Program 10053020, Development of In Situ 3D Bioprinting System for Wound-Tailored Skin Regeneration funded By the Ministry of Trade, Industry & Energy (M/I, Korea).

CONFLICTS OF INTEREST

The authors have nothing to disclose.

REFERENCES

1. Panjwani N. Role of galectins in re-epithelialization of wounds. *Ann Transl Med* 2014;2:89.
2. Bernerd F, Sarasin A, Magnaldo T. Galectin-7 overexpression is associated with the apoptotic process in UVB-induced sunburn keratinocytes. *Proc Natl Acad Sci U S A* 1999;96:11329-11334.
3. Kim J, Jeong HS, Li H, Baek KJ, Kwon NS, Yun HY, et al. Effects of Cervi cornus Colla (deer antler glue) in the reconstruction of a skin equivalent model. *Arch Dermatol Res* 2013;305:85-89.
4. Arqués O, Chicote I, Tenbaum S, Puig I, Palmer HG. Standardized relative quantification of immunofluorescence tissue staining. *Protoc Exch* 2012. doi: 10.1038/protex.2012.008.
5. Liu W, Hsu DK, Chen HY, Yang RY, Carraway KL 3rd, Isseroff RR, et al. Galectin-3 regulates intracellular trafficking of EGFR through Alix and promotes keratinocyte migration. *J Invest Dermatol* 2012;132:2828-2837.
6. Gendronneau G, Sidhu SS, Delacour D, Dang T, Calonne C, Houzelstein D, et al. Galectin-7 in the control of epidermal homeostasis after injury. *Mol Biol Cell* 2008;19:5541-5549.
7. Chen HL, Chiang PC, Lo CH, Lo YH, Hsu DK, Chen HY, et al. Galectin-7 Regulates Keratinocyte Proliferation and Differentiation through JNK-miR-203-p63 Signaling. *J Invest Dermatol* 2016;136:182-191.

8. Argüeso P, Mauris J, Uchino Y. Galectin-3 as a regulator of the epithelial junction: implications to wound repair and cancer. *Tissue Barriers* 2015;3:e1026505.
9. Dumic J, Dabelic S, Flögel M. Galectin-3: an open-ended story. *Biochim Biophys Acta* 2006;1760:616-635.
10. Saussez S, Kiss R. Galectin-7. *Cell Mol Life Sci* 2006; 63:686-697.

<https://doi.org/10.5021/ad.2018.30.3.378>



Unique Case of Postural Acquired Lymphangiectasia of the Scrotum Exacerbated by an Erect Position

Yoon Seob Kim, Yu Mee Song, Chul Hwan Bang, Hyun-Min Seo¹, Ji Hyun Lee, Jun Young Lee, Young Min Park

Department of Dermatology, Seoul St. Mary's Hospital, College of Medicine, The Catholic University of Korea, Seoul, ¹Department of Dermatology, Hanyang University Guri Hospital, Guri, Korea

Dear Editor:

Acquired lymphangiectasia (AL) is thought to arise from lymphatic occlusion¹. AL appears as thin-walled, translucent, white, or skin-colored papules and vesicles². AL on the scrotum is rare and may present as a congenital condition or, rarely, develop secondary to radiotherapy, infection, or surgery³. Herein, we report an interesting case of postural AL of the scrotum, which became more prominent with the erect position.

A 10-year-old boy presented with multiple skin-colored papules on the scrotum for 6 months. On physical examination, the skin lesions became more prominent with the erect position (Fig. 1A, B). The size of each lesion had recently increased abruptly without oozing. Eight years before presentation, he had orchiopexy of the right testis due to cryptorchidism. He denied any skin lesions on the scrotum at that time. On ultrasonography at the time of presentation, right testis was found to be orchiopexy state, whereas left one was cryptorchidism in high sacral area, and there was no evidence of lymphatic malformation.

Histopathological examination of a representative lesion revealed multiple dilated channels on the upper dermis. Endothelial cells lining the dilated channels showed positivity in D2-40 immunohistochemistry (Fig. 1C, D). Therefore, we confirmed the dilated channels in the upper dermis to be lymphatics. Based on these clinical and histological findings, he was diagnosed with AL. Because there was little cosmetic concern or complication at presentation, we decided to observe. We recommended magnetic resonance imaging for further evaluation, if symptoms develop later.

AL usually results from lymphatic obstruction caused by a spectrum of scarring processes often due to surgery⁴. Postsurgical fibrosis occludes the normal lymphatics, causing subsequent dilatation of the dermal lymphatics leading to AL². Our patient had a history of orchiopexy due to cryptorchidism, so we suspected that AL occurred due to operation. Our case is unique since the lesions were more prominent with the patient in an erect position. Lymph flow within the skin depends on tissue movement caused

Received November 25, 2016, Revised June 25, 2017, Accepted for publication July 1, 2017

Corresponding author: Young Min Park, Department of Dermatology, Seoul St. Mary's Hospital, College of Medicine, The Catholic University of Korea, 222 Banpo-daero, Seocho-gu, Seoul 06591, Korea. Tel: 82-2-2258- 6223, Fax: 82-2-599-9950, E-mail: ymmpark6301@hotmail.com
ORCID: <https://orcid.org/0000-0002-3631-0807>

This is an Open Access article distributed under the terms of the Creative Commons Attribution Non-Commercial License (<http://creativecommons.org/licenses/by-nc/4.0>) which permits unrestricted non-commercial use, distribution, and reproduction in any medium, provided the original work is properly cited.

Copyright © The Korean Dermatological Association and The Korean Society for Investigative Dermatology