

# Nationwide survey of partial fundoplication in Korea: comparison with total fundoplication

Chang Min Lee<sup>1</sup>, Joong-Min Park<sup>2</sup>, Han Hong Lee<sup>3</sup>, Kyong Hwa Jun<sup>3</sup>, Sungsoo Kim<sup>4</sup>, Kyung Won Seo<sup>5</sup>, Sungsoo Park<sup>1</sup>, Jong-Han Kim<sup>1</sup>, Jin-Jo Kim<sup>3</sup>, Sang-Uk Han<sup>6</sup>; for the Korean Anti-Reflux Surgery (KARS) study group

<sup>1</sup>Department of Surgery, Korea University College of Medicine, Seoul, Korea

<sup>2</sup>Department of Surgery, Chung-Ang University College of Medicine, Seoul, Korea

<sup>3</sup>Department of Surgery, College of Medicine, The Catholic University of Korea, Seoul, Korea

<sup>4</sup>Department of Surgery, Chosun University College of Medicine, Gwangju, Korea

<sup>5</sup>Department of Surgery, Kosin University College of Medicine, Busan, Korea

<sup>6</sup>Department of Surgery, Ajou University School of Medicine, Suwon, Korea

**Purpose:** Laparoscopic total fundoplication is the standard surgery for gastroesophageal reflux disease. However, partial fundoplication may be a viable alternative. Here, we conducted a nationwide survey of partial fundoplication in Korea.

**Methods:** The Korean Anti-Reflux Surgery study group recorded 32 cases of partial fundoplication at eight hospitals between September 2009 and January 2016. The surgical outcomes and postoperative adverse symptoms in these cases were evaluated and compared with 86 cases of total fundoplication.

**Results:** Anterior partial fundoplication was performed in 20 cases (62.5%) and posterior in 12 (37.5%). In most cases, partial fundoplication was a secondary procedure after operations for other conditions. Half of patients who underwent partial fundoplication had typical symptoms at the time of initial diagnosis, and most of them showed excellent (68.8%), good (25.0%), or fair (6.3%) symptom resolution at discharge. Compared to total fundoplication, partial fundoplication showed no difference in the resolution rate of typical and atypical symptoms. However, adverse symptoms such as dysphagia, difficult belching, gas bloating and flatulence were less common after partial fundoplication.

**Conclusion:** Although antireflux surgery is not popular in Korea and total fundoplication is the primary surgical choice for gastroesophageal reflux disease, partial fundoplication may be useful in certain conditions because it has less postoperative adverse symptoms but similar efficacy to total fundoplication.

[Ann Surg Treat Res 2018;94(6):298-305]

**Key Words:** Fundoplication, Partial fundoplication, Gastroesophageal reflux

## INTRODUCTION

Although the prevalence of gastroesophageal reflux disease (GERD) is relatively low in Korea, it is rapidly increasing. GERD has recently been recognized as a significant health concern in Korea, and the use of proton pump inhibitor (PPI) is

consequently on the rise [1].

However, antireflux surgery has not been widely adopted as a treatment for GERD in Korea, and few Korean studies have reported the use of this operation. Therefore, the surgical options for GERD are not well known, even among surgeons [2,3].

Since laparoscopic Nissen fundoplication (LNF) for GERD was

Received July 7, 2017, Revised September 18, 2017,

Accepted October 10, 2017

Corresponding Author: Jong-Han Kim

Department of Surgery, Korea University Ansan Hospital, Korea University College of Medicine, 123 Jeokgeum-ro, Danwon-gu, Ansan 15355, Korea

Tel: +82-31-412-5957, Fax: +82-31-413-4829

E-mail: ppongttai@gmail.com

ORCID code: https://orcid.org/0000-0002-3862-8501

Copyright © 2018, the Korean Surgical Society

© Annals of Surgical Treatment and Research is an Open Access Journal. All articles are distributed under the terms of the Creative Commons Attribution Non-Commercial License (<http://creativecommons.org/licenses/by-nc/4.0/>) which permits unrestricted non-commercial use, distribution, and reproduction in any medium, provided the original work is properly cited.

first advocated [4], laparoscopic total fundoplication has been regarded as an alternative treatment modality for GERD. Several randomized studies have found that its effect is similar to those of long-term treatment with a PPI, improving the symptoms in 85%–90% of patients [5,6].

LNF with a total wrap that completely surrounds the esophagus is the most commonly used gold standard technique worldwide for antireflux surgery [7]. However, it is associated with a high incidence of postoperative dysphagia and gas-bloat syndrome [8,9]. Therefore, partial fundoplications including the Toupet (posterior 270°) and Dor (anterior 180°) methods were introduced to avoid these adverse outcomes [10-12].

Recently, the Korean Anti-Reflux Surgery (KARS) study group performed a nationwide survey of antireflux surgery in Korea. Furthermore, they announced their plans to investigate partial fundoplication to fore-gut surgeons. Here, we evaluate the short-term surgical outcomes and postoperative adverse outcomes of partial fundoplication in Korea and compared the data with corresponding data for total LNF.

## METHODS

The nationwide survey of KARS study group identified 32 cases of partial fundoplication from 8 hospitals including Incheon St. Mary's Hospital (16 cases), Ajou University Medical Center (4 cases), Chung-Ang University Hospital (3 cases), St. Vincent's Hospital (2 cases), Kosin University Gospel Hospital (2 cases), Chosun University Hospital (2 cases), Uijeonbu St. Mary's Hospital (1 case), and Korea University Ansan Hospital (2 case). All operations were performed between September 2009 and January 2016. Approval to perform research on human subjects in this survey was provided by the Institutional Review Board of each Hospital.

Survey data included patient characteristics, duration of typical and atypical symptoms, responses to PPIs, preoperative endoscopic findings, and presence of hiatal hernia. Among operative findings, the reason for partial fundoplication or combination with other procedure was assessed. Among postoperative findings, short-term surgical outcomes including the operation time, time to start liquid diet, time to start soft diet, hospital stay, and the morbidity at the time of discharge and 3-month postoperative follow-up data were recorded.

GERD symptoms were categorized as typical and atypical. The former included heartburn, regurgitation, and epigastric pain, while the latter included cough, globus sensation, and throat pain. Postoperative symptom resolution was graded as poor, fair, good, or excellent. "Poor" indicated treatment failure, while "fair" implied partial symptom control. "Good" and "excellent" indicated complete symptom control. Postoperative adverse outcomes such as dysphagia, difficult belching, gas bloating, and flatulence were graded with 5-point scores (no

symptom, 0; mild, 1; moderate, 2; severe, 3; very severe, 4).

Partial fundoplication data were compared with previous data collected by KARS regarding 86 total fundoplications. Short-term outcomes and symptom resolution (at the time of discharge and at 3 months postoperatively) were compared between the groups using chi-square and Student t-test. In addition, postoperative adverse outcome scores were compared between the 2 groups.

IBM SPSS ver. 18.0 (IBM Co., Armonk, NY, USA) were used for statistical analysis. For all data analyses,  $P < 0.05$  was considered statistically significant.

**Table 1.** Characteristics of patients who underwent partial fundoplication (n = 32)

Characteristic	Value
Age (yr)	56.3 ± 16.5 (19–88)
Sex ratio (male:female)	0.8:1
Body mass index (kg/m <sup>2</sup> )	23.9 ± 3.9 (17.4–33.8)
Previous intra-abdominal surgery	11 (34.4)
History of GERD symptoms (mo)	6 (0–480)
Features of GERD symptoms	
Typical symptom	16 (50)
Atypical symptom	7 (21.9)
Response to PPI treatment	
No response	19 (59.4)
Poor	8 (25.0)
Fair	2 (6.3)
Good	3 (9.4)
Excellent	0 (0)
Los Angeles grade of esophagitis	
No esophagitis	20 (62.5)
M	5 (15.6)
A	3 (9.4)
B	2 (6.3)
C	0 (0)
D	0 (0)
Hiatal hernia	
No hiatal hernia	24 (75.0)
Type 1	3 (9.4)
Type 2	0 (0.0)
Type 3	4 (12.5)
Types of partial wrap	
Anterior	20 (62.5)
Posterior	12 (37.5)
Reasons for partial fundoplication	
Giant hiatal hernia	7 (21.9)
Myotomy for achalasia	10 (31.3)
Surgery for GEJ tumor	12 (37.5)
Others	3 (9.4)

Values are presented as mean ± standard deviation (range), number (%), or median (range).

GERD, gastroesophageal reflux disease; PPI, proton pump inhibitor; GEJ, gastroesophageal junction.

## RESULTS

### Patient characteristics of partial fundoplication cases

A total of 32 patients underwent partial fundoplication between September 2009 and January 2016 (Table 1). The mean age was  $56.3 \pm 16.5$  years (range, 19–88 years), and the ratio of male to female was 0.8:1. The mean body mass index was  $23.9 \pm 3.9$  kg/m<sup>2</sup> (range, 17.4–33.8 kg/m<sup>2</sup>).

Of these patients, 11 (34.4%) had undergone other intra-abdominal surgeries before partial fundoplication.

The median duration of GERD symptoms was 6 months (range, 0–480 months). One half of GERD symptoms were typical, and 19 of 32 patients (59.4%) did not respond to PPIs. More than half of patients (62.5%) did not have esophagitis based on the Los Angeles grade of esophagitis. In addition, most patients (75%) did not have an associated hiatal hernia.

The anterior (Dor) procedure was used in 20 cases (62.5%) and the posterior (Toupet) procedure was used in 12 cases (37.5%). They were almost secondary procedures after operations for other conditions, such as gastroesophageal junction tumor (12 cases, 37.5%), achalasia (10 cases, 31.3%), and giant hiatal hernia (7 cases, 21.9%).

### Total versus partial fundoplication: short-term outcomes

In terms of short-term outcomes (Table 2), partial fundoplication showed longer operation time and hospital stay than total fundoplication (median operation time, 157.5 and 109.0 minutes, respectively,  $P < 0.001$ ; median hospital stay, 6.0 and 3.0 days, respectively,  $P = 0.003$ ). In addition, partial fundoplication was also associated with a significant delay in diet initiation compared to total fundoplication (median time to start liquid diet, 3.0 and 1.0 days, respectively,  $P = 0.042$ ; median

**Table 2.** Comparison of short-term outcomes between total and partial fundoplication

Variable	Total fundoplication (n = 86)	Partial fundoplication (n = 32)	P-value
Operation time (min)	109.0 (47–290)	157.5 (55–320)	<0.001
Time to start LD (day)	1.0 (1–9)	3.0 (1–34)	0.042
Time to start SD (day)	2.0 (1–12)	4.0 (2–34)	0.040
Hospital stay (day)	3.0 (2–16)	6.0 (3–68)	0.003
Morbidity	1/86 (1.2)	1/32 (3.1)	0.463

Values are presented as median (range) or number (%). LD, liquid diet; SD, soft diet.

**Table 3.** Incidence of postoperative symptom resolution

Postoperative symptom	Total wrap	Partial wrap	P-value
Typical symptom at the time of discharge	70/81 (86.4)	15/16 (93.8)	0.784
Excellent	55/81 (67.9)	11/16 (68.8)	
Good	15/81 (18.5)	4/16 (25.0)	
Fair	8/81 (9.9)	1/16 (6.3)	
Poor	3/81 (3.7)	0 (0)	
Persistent	0 (0)	0 (0)	
Typical symptom at the postoperative 3 months	44/51 (86.3)	13/16 (81.3)	0.477
Excellent	35/51 (68.6)	8/16 (50.0)	
Good	9/51 (17.6)	5/16 (31.3)	
Fair	6/51 (11.85)	3/16 (18.8)	
Poor	1/51 (2.0)	0 (0)	
Persistent	0 (0)	0 (0)	
Atypical symptom at the time of discharge	37/53 (69.8)	9/9 (100)	0.406
Excellent	20/53 (37.7)	4/9 (44.4)	
Good	17/53 (32.1)	5/9 (55.6)	
Fair	11/53 (20.85)	0 (0)	
Poor	4/53 (7.5)	0 (0)	
Persistent	1/53 (1.9)	0 (0)	
Atypical symptom at the postoperative 3 months	23/31 (74.2)	7/9 (77.8)	0.328
Excellent	14/31 (45.2)	4/9 (44.4)	
Good	8/31 (25.8)	3/9 (33.3)	
Fair	7/31 (22.6)	1/9 (11.1)	
Poor	2/31 (6.5)	0 (0)	
Persistent	0 (0)	1/9 (11.1)	

The cases that initially showed no symptom was excluded from this comparison. Therefore, these values are expressed as the number of patients undergoing symptom resolution divided by the number of initially symptomatic patients. In this comparative analysis, 'excellent' or 'good' resolution was regarded as postoperative symptom resolution.

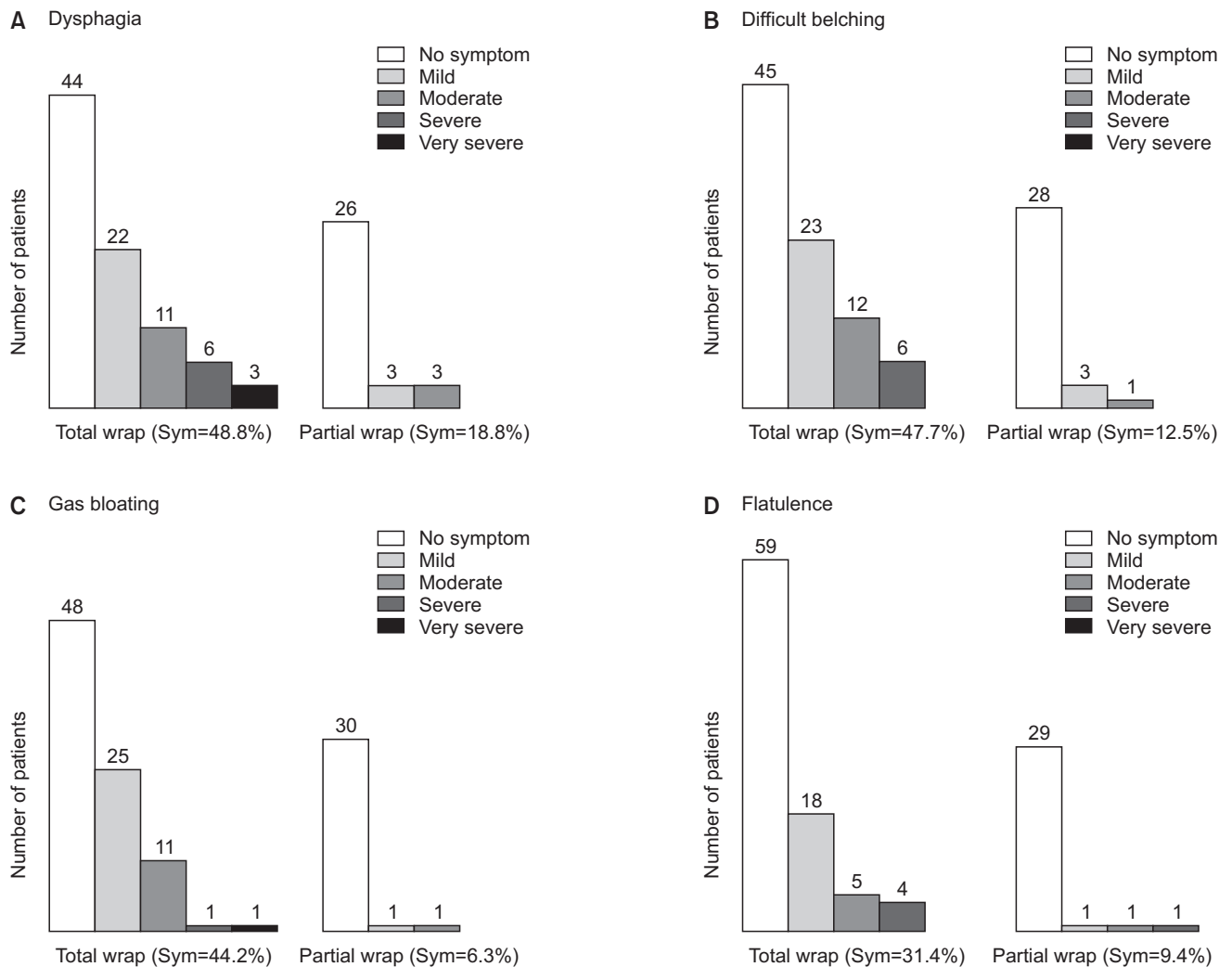
time to start soft diet, 4.0 and 2.0 days, respectively,  $P = 0.040$ ). However, no significant difference was found between the 2 procedures in terms of morbidity (3.1 and 1.2 %, respectively,  $P = 0.463$ ).

### Total versus partial fundoplication: symptom resolutions

The symptom resolution rates were showed in Table 3. The postoperative typical symptom resolution rate at the time of discharge was excellent (68.8%), good (25.0%), and fair (6.3%) in 16 patients who initially had typical symptoms. Therefore, the total symptom resolution rate was 93.8% (15 of 16) in partial fundoplication cases. However, the typical symptom resolution rate decreased to 81.3% (13 of 16) after 3 months.

Nine patients (29.1% of partial fundoplication cases) had atypical symptoms at the time of initial diagnosis. All of these patients (100%) showed atypical symptom resolution at the time of discharge. Two of them showed atypical symptoms after 3 months. Therefore, the atypical symptom resolution rate decreased to 77.8% (7 of 9).

No significant difference was found between total and partial fundoplication in terms of the resolution rate of typical symptoms, either at the time of discharge or 3 months after the operation ( $P = 0.784$  and  $P = 0.477$ , respectively). The resolution rate of atypical symptoms also did not differ between total and partial fundoplication cases at the time of discharge or 3 months postoperatively ( $P = 0.406$  and  $P = 0.328$ , respectively).



**Fig. 1.** Comparison of postoperative adverse symptoms at the time of discharge. (A) Dysphagia was more frequent after total fundoplication than partial (Incidence was 48.8% and 18.8%, respectively,  $P = 0.040$ ). (B) Difficult belching was more frequent after total fundoplication than partial (Incidence was 47.7% and 12.5%, respectively,  $P = 0.006$ ). (C) Gas bloating was more frequent after total fundoplication than partial (Incidence was 44.2% and 6.3%, respectively,  $P = 0.005$ ). (D) Flatulence was more frequent after total fundoplication than partial (Incidence was 31.4% and 9.4%, respectively,  $P = 0.087$ ). Sym, incidence of symptoms.

### Total versus partial fundoplication: postoperative adverse symptoms

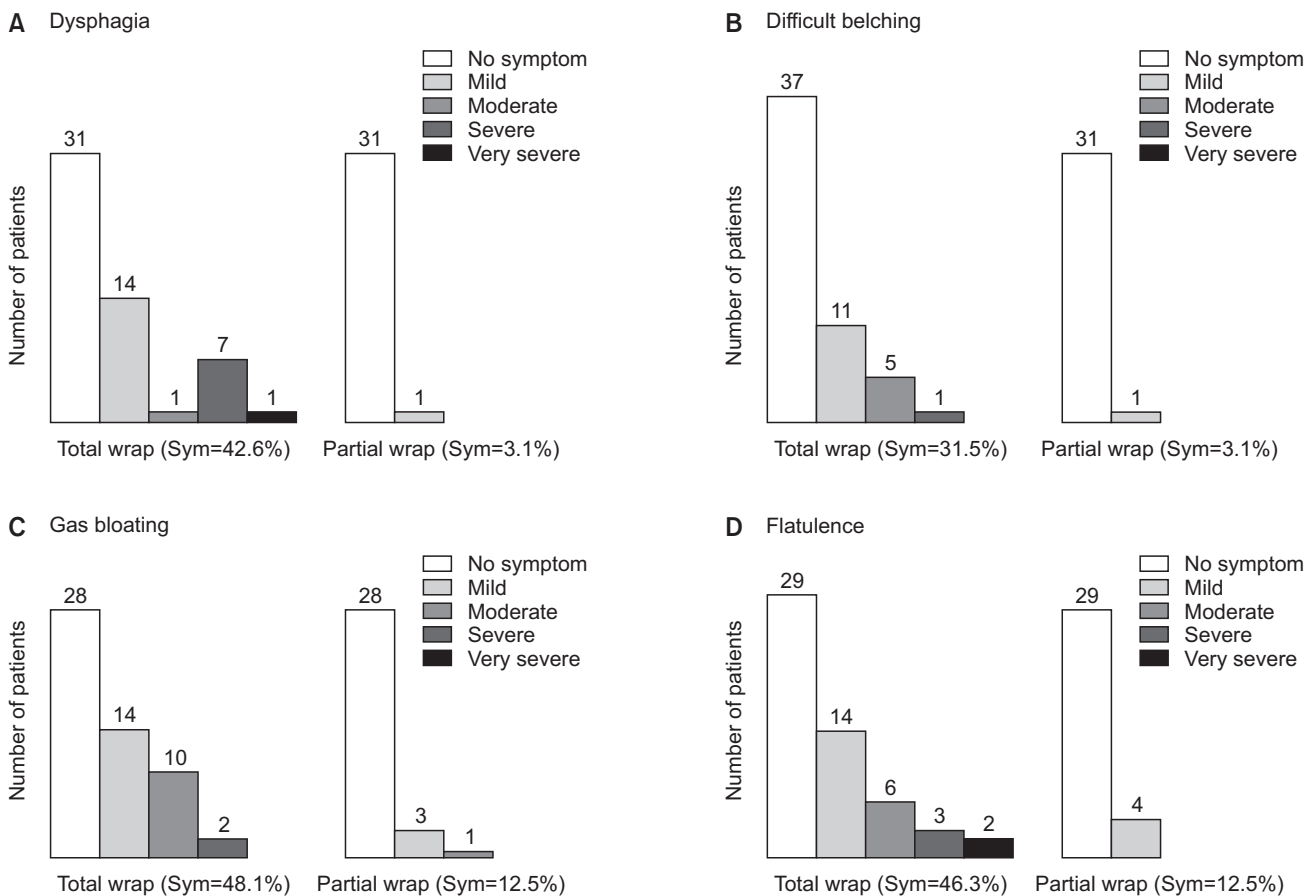
In terms of postoperative adverse symptoms, total fundoplication was associated with higher rates of all 4 adverse symptoms at the time of discharge than partial fundoplication (dysphagia, 48.8% and 18.8%, respectively,  $P = 0.040$ ; difficult belching, 47.7% and 12.5%, respectively,  $P = 0.006$ ; gas bloating, 44.2% and 6.3%, respectively,  $P = 0.005$ ; and flatulence, 31.4% and 9.4%, respectively,  $P = 0.087$ ) (Fig. 1).

After 3 months, adverse outcome rates did not improve, and between-group differences showed similar trends (dysphagia, 42.6% and 3.1%, respectively,  $P = 0.004$ ; difficult belching, 31.5% and 3.1%, respectively,  $P = 0.020$ ; gas bloating, 48.1% and 12.5%, respectively,  $P = 0.009$ ; and flatulence, 46.3% and 12.5%, respectively,  $P = 0.020$ ) (Fig. 2).

### DISCUSSION

Recently, as the use of upper gastrointestinal endoscopic examination has increased rapidly in Korea, the detection of benign pathologic conditions related to the gastroesophageal junction has consequently increased. Furthermore, minimally invasive approaches such as laparoscopic wedge resection have become the standard approach for benign gastroesophageal junctional tumors, and functional problems including gastroesophageal reflux due to destruction of anatomical reflux barriers in junctional areas are now a matter of concern [13].

Esophageal achalasia, an esophageal motility disorder involving the smooth muscle layer of the esophagus and the lower esophageal sphincter (LES) [14], should be treated surgically with laparoscopic Heller's myotomy in patients for whom medical management or endoscopic pneumatic dilatation is ineffective [15,16]. Myotomy involves a lengthwise cut along the esophagus, starting above the LES and extending



**Fig. 2.** Comparison of postoperative adverse symptoms at the postoperative 3 months. (A) Dysphagia was more frequent after total fundoplication than partial (Incidence was 42.6% and 3.1%, respectively,  $P = 0.004$ ). (B) Difficult belching was more frequent after total fundoplication than partial (Incidence was 31.5% and 3.1%, respectively,  $P = 0.020$ ). (C) Gas bloating was more frequent after total fundoplication than partial (Incidence was 48.1% and 12.5%, respectively,  $P = 0.009$ ). (D) Flatulence was more frequent after total fundoplication than partial (Incidence was 46.3% and 12.5%, respectively,  $P = 0.020$ ). Sym, incidence of symptoms.

down slightly into the stomach. After this procedure, a partial fundoplication or "wrap" is generally added to prevent excessive reflux, which can cause serious damage to the esophagus over time. The most commonly recommended fundoplication with Heller's myotomy is Dor's fundoplication, which consists of a 180° to 200° anterior wrap around the esophagus. It provides substantially better results than Nissen fundoplication, which is associated with a higher incidence of dysphagia [17].

Giant hiatal hernia is a type III combined sliding and paraesophageal hernia that is accompanied by dysphagia, regurgitation, epigastric pain, and intermittent mucosal bleeding [18]. Surgical treatment is recommended for paraesophageal hiatal hernia that manifests with significant obstructive and reflux symptoms [19,20]. This treatment involves 3 basic principles. The first is complete reduction of the hiatal hernia with sac excision and tension free crural repair, the second is appropriate use of esophageal lengthening procedures, and the third is an antireflux procedure for GERD management [18,21]. Most recent reports of paraesophageal hiatal hernia repair describe fundoplication as a step in the repair process, and this procedure is thought to aid in preventing postoperative gastroesophageal reflux and recurrence [22,23]. There is no consensus regarding the type and degree of fundoplication needed after hiatal hernia repair to prevent reflux. However, one Korean study suggests partial fundoplication as a suitable substitute for total fundoplication, especially when esophageal motility is not mandatory [24].

In the present nationwide survey, we found that partial fundoplication was additionally performed when other pathologic conditions related to the gastroesophageal junctional area were present, such as gastroesophageal junctional tumor (12 cases), achalasia (10 cases), and giant hiatal hernia (7 cases). Simultaneous operations performed in these 29 cases might be why partial fundoplication had a longer operation time than total fundoplication in our results. Therefore, one limitation of the present survey is that the actual operation times of partial fundoplication could not be acquired.

Various types of partial fundoplication have been attempted thus far, but the 2 types typically used are anterior (Dor) and posterior (Toupet) partial fundoplication. The type of fundoplication generally depends on the surgeon's preference or the primary operation. For example, Dor fundoplication is preferred after myotomy or excision of gastroesophageal junction tumors, but Nissen or Toupet fundoplication is usually adopted after giant paraesophageal hiatal hernia repair. Actually, Dor fundoplication is appropriate procedure for protecting the myotomy operation field or preventing postoperative GERD after tumor excision; its antireflux effect has not yet been widely accepted. On the other hand, Toupet fundoplication is not inferior to Nissen procedure in terms of anti-reflux effect. In our survey, anterior Dor fundoplication

was the most commonly performed procedure (19 patients; 61.3%), and it was mostly performed after myotomy for achalasia (8 cases) or resection of gastroesophageal junction tumors (11 cases).

Diet after foregut surgery usually depends on the aggressiveness and invasiveness of the operative procedure and the presence of organ resection and anastomosis. The original antireflux surgical procedure has no invasive component, and a regular diet can be started 1 or 2 days after the operation. However, since cases of partial fundoplication in the present study were associated with other surgical procedures, the start of a liquid or soft diet was delayed and the hospital stay was extended.

More than half of patients in the present study had no preoperative reflux symptoms because the other conditions they had, including gastroesophageal junction tumors and achalasia, were not associated with any anatomical pathologic abnormality of the LES that could give rise to gastroesophageal reflux symptoms. Generally, patients with giant hiatal hernia had reflux or obstructive symptoms and showed excellent and good postoperative symptom resolution after hernia repair and partial fundoplication in our survey. In a previous KARS survey of total fundoplication cases, the complete typical symptom resolution rate was about 86.3% [25]. Among cases of partial fundoplication in the present study, about 90% of patients with reflux symptoms showed complete resolution postoperatively.

The most remarkable findings in this study were the disappearance of adverse symptoms after partial fundoplication for antireflux procedures. A tight gastric wrap in total fundoplication can induce typical adverse symptoms, including dysphasia, difficult belching, gas bloating, and flatulence. A partial anterior or posterior wrap may reduce tightness along the entire circumference of the gastric fold around the gastroesophageal junction. In patients who underwent total fundoplication, the incidence rates of postoperative adverse outcomes, including mild, moderate, severe, and very severe cases, were 30%–50% in the early postoperative period (Fig. 1). The present survey found that they were below 20% after partial fundoplication.

Several randomized controlled trials have compared symptom resolution and postoperative adverse outcomes between total and partial fundoplication for GERD [26-30]. In most reports, the operative time, perioperative complications, postoperative satisfaction, recurrence, and rates of medication or reoperation due to recurrence did not significantly differ between the 2 methods, although many surgeons are concerned that partial fundoplication does not result in a life-long standing solid wrap. However, the rates of adverse results, including dysphagia, gas-bloat syndrome, inability to belch, and reoperation due to severe dysphasia, were significantly higher after laparoscopic total fundoplication than partial fundoplication. Therefore, laparoscopic partial fundoplication may be a better surgical

approach for GERD because it has a lower rate of postoperative adverse results and equal efficacy compared to laparoscopic total fundoplication.

## CONFLICTS OF INTEREST

No potential conflict of interest relevant to this article was reported.

## REFERENCES

- Kim KM, Cho YK, Bae SJ, Kim DS, Shim KN, Kim JH, et al. Prevalence of gastroesophageal reflux disease in Korea and associated health-care utilization: a national population-based study. *J Gastroenterol Hepatol* 2012;27:741-5.
- Lee SK, Kim EK. Laparoscopic Nissen fundoplication in Korean patients with gastroesophageal reflux disease. *Yonsei Med J* 2009;50:89-94.
- Lee SB, Jeon KM, Kim BS, Kim KC, Jung HY, Choi YB. Early experiences of minimally invasive surgery to treat gastroesophageal reflux disease. *J Korean Surg Soc* 2013;84:330-7.
- Dallemagne B, Weerts JM, Jehaes C, Markiewicz S, Lombard R. Laparoscopic Nissen fundoplication: preliminary report. *Surg Laparosc Endosc* 1991;1:138-43.
- Mahon D, Rhodes M, Decadt B, Hindmarsh A, Lowndes R, Beckingham I, et al. Randomized clinical trial of laparoscopic Nissen fundoplication compared with proton-pump inhibitors for treatment of chronic gastro-oesophageal reflux. *Br J Surg* 2005;92:695-9.
- Galmiche JP, Hatlebakk J, Attwood S, Ell C, Fiocca R, Eklund S, et al. Laparoscopic antireflux surgery vs esomeprazole treatment for chronic GERD: the LOTUS randomized clinical trial. *JAMA* 2011;305:1969-77.
- Salminen P. The laparoscopic Nissen fundoplication: a better operation? *Surgeon* 2009;7:224-7.
- Hunter JG, Swanstrom L, Waring JP. Dysphagia after laparoscopic antireflux surgery. The impact of operative technique. *Ann Surg* 1996;224:51-7.
- Rantanen TK, Salo JA, Salminen JT, Kellokumpu IH. Functional outcome after laparoscopic or open Nissen fundoplication: a follow-up study. *Arch Surg* 1999;134:240-4.
- Tupet A. Technique d'oesophago-gastroplastie avec phreno-gastropexie appliquee dans la cure radicale des hernies hiatales et comme complement de l'operation d'Heller dans les cardiospasmes. *Mem Acad Chir* 1963;89:394-9.
- Broeders JA, Broeders EA, Watson DI, Devitt PG, Holloway RH, Jamieson GG. Objective outcomes 14 years after laparoscopic anterior 180-degree partial versus nissen fundoplication: results from a randomized trial. *Ann Surg* 2013;258:233-9.
- Broeders JA, Roks DJ, Ahmed Ali U, Watson DI, Baigrie RJ, Cao Z, et al. Laparoscopic anterior 180-degree versus nissen fundoplication for gastroesophageal reflux disease: systematic review and meta-analysis of randomized clinical trials. *Ann Surg* 2013;257:850-9.
- Singaporewalla RM, Baladas GH, Lee TD. Laparoendoscopic removal of a benign gastric stromal tumor at the cardia. *JSLA* 2006;10:117-21.
- Park W, Vaezi MF. Etiology and pathogenesis of achalasia: the current understanding. *Am J Gastroenterol* 2005;100:1404-14.
- Wang L, Li YM, Li L. Meta-analysis of randomized and controlled treatment trials for achalasia. *Dig Dis Sci* 2009;54:2303-11.
- Boeckxstaens GE, Annese V, des Varannes SB, Chaussade S, Costantini M, Cuttitta A, et al. Pneumatic dilation versus laparoscopic Heller's myotomy for idiopathic achalasia. *N Engl J Med* 2011;364:1807-16.
- Rebecchi F, Giaccone C, Farinella E, Campaci R, Morino M. Randomized controlled trial of laparoscopic Heller myotomy plus Dor fundoplication versus Nissen fundoplication for achalasia: long-term results. *Ann Surg* 2008;248:1023-30.
- Mitiek MO, Andrade RS. Giant hiatal hernia. *Ann Thorac Surg* 2010;89:S2168-73.
- Morino M, Giaccone C, Pellegrino L, Rebecchi F. Laparoscopic management of giant hiatal hernia: factors influencing long-term outcome. *Surg Endosc* 2006;20:1011-6.
- Stylopoulos N, Gazelle GS, Rattner DW. Paraesophageal hernias: operation or observation? *Ann Surg* 2002;236:492-500.
- Lal DR, Pellegrini CA, Oelschlager BK. Laparoscopic repair of paraesophageal hernia. *Surg Clin North Am* 2005;85:105-18, x.
- Swanstrom LL, Jobe BA, Kinzie LR, Horvath KD. Esophageal motility and outcomes following laparoscopic paraesophageal hernia repair and fundoplication. *Am J Surg* 1999;177:359-63.
- Fuller CB, Hagen JA, DeMeester TR, Peters JH, Ritter M, Bremmer CG. The role of fundoplication in the treatment of type II paraesophageal hernia. *J Thorac Cardiovasc Surg* 1996;111:655-61.
- Seo KW, Park MI, Yoon KY, Park SJ, Kim SE. Laparoscopic partial fundoplication in case of gastroesophageal reflux disease patient with absent esophageal motility. *J Gastric Cancer* 2015;15:127-31.
- Lee JH, Park JM, Han SU, Kim JJ, Song KY, Ryu SW, et al. Antireflux surgery in Korea: a nationwide study from 2011 to 2014. *Gut Liver* 2016;10:726-30.
- Laws HL, Clements RH, Swillie CM. A

- randomized, prospective comparison of the Nissen fundoplication versus the Toupet fundoplication for gastroesophageal reflux disease. *Ann Surg* 1997;225:647-53.
27. Chrysos E, Tsiaoussis J, Zoras OJ, Athanakis E, Mantides A, Katsamouris A, et al. Laparoscopic surgery for gastroesophageal reflux disease patients with impaired esophageal peristalsis: total or partial fundoplication? *J Am Coll Surg* 2003;197:8-15.
28. Guerin E, Betroune K, Closset J, Mehdi A, Lefebvre JC, Houben JJ, et al. Nissen versus Toupet fundoplication: results of a randomized and multicenter trial. *Surg Endosc* 2007;21:1985-90.
29. Booth MI, Stratford J, Jones L, Dehn TC. Randomized clinical trial of laparoscopic total (Nissen) versus posterior partial (Toupet) fundoplication for gastro-oesophageal reflux disease based on preoperative oesophageal manometry. *Br J Surg* 2008;95:57-63.
30. Shaw JM, Bornman PC, Callanan MD, Beckingham IJ, Metz DC. Long-term outcome of laparoscopic Nissen and laparoscopic Toupet fundoplication for gastroesophageal reflux disease: a prospective, randomized trial. *Surg Endosc* 2010;24:924-32.