



## Case Report

## Lateral approach of exploratory laparotomy through the open chest wall injury

Jonghwan Moon, Byung Hee Kang\*

Division of Trauma Surgery, Department of Surgery, Ajou University School of Medicine, Republic of Korea

## ARTICLE INFO

## Keywords:

Wounds and injuries  
Laparotomy  
Diaphragm  
Thorax

## ABSTRACT

A combined laparotomy and thoracotomy is required in a few trauma patients. The anterior approach is a standard procedure used in such cases; however, a different approach may be required. Recently, we managed a patient who presented with a crush injury to the left side of his chest with associated bowel herniation. We performed the operation with the lateral approach, and even the laparotomy was performed through the rupture wound in the diaphragm. The operation could be successfully completed without changing the patient's position or creating an additional incision. Although the patient recovered well postoperatively, lateral approach for laparotomy had some limitations.

## Introduction

In blunt trauma, an exploratory laparotomy is performed to identify organ or vascular injuries, which might not be detected using imaging modality. The anterior approach through a long midline incision is the standard method even in patients presenting with open wounds. The lateral or posterior approach is rarely utilized because it is not suitable for exploration. However, in the field of thoracic surgery, the lateral position is preferred because it provides easy access to the hilum. Performing simultaneous abdominal and thoracic surgery is often necessary in a few severely injured patients, and usually the supine position is preferred. However, we report the use of the lateral approach through an open wound in the absence of any other option.

## Case report

A 40-year-old man was transferred to our trauma center by helicopter after being injured in an explosion in a factory. He presented with unstable vital signs and a Glasgow Coma Scale of 11. His left arm was nearly amputated, and his left lung was visible because of a crush injury to his chest wall. After intubation and blood transfusion, a log rolling maneuver was performed for inspection of his back. Bowel evisceration was noted at the posterolateral area of the thoracic cavity, and diaphragmatic rupture was suspected (Fig. 1). After wrapping the wound, the patient was moved to the operating room without undergoing any imaging study. We ligated the brachial vessels that had already been transected, and performed amputation of his arm. Because the bowel was observed to have already eviscerated through the wound in his lateral chest wall, we decided to perform exploration using the lateral position/approach. The left diaphragm showed complete rupture, and the intra-abdominal organs were visible through the ruptured diaphragm (Fig. 2). The spleen was also observed to have ruptured, and splenic vessel ligation was performed (Fig. 3). The

\* Corresponding author at: Division of Trauma Surgery, Department of Surgery, Ajou University School of Medicine, 206 Worldcup-ro, Yeongtong-gu, Suwon-si, Gyeonggi-do, Republic of Korea.

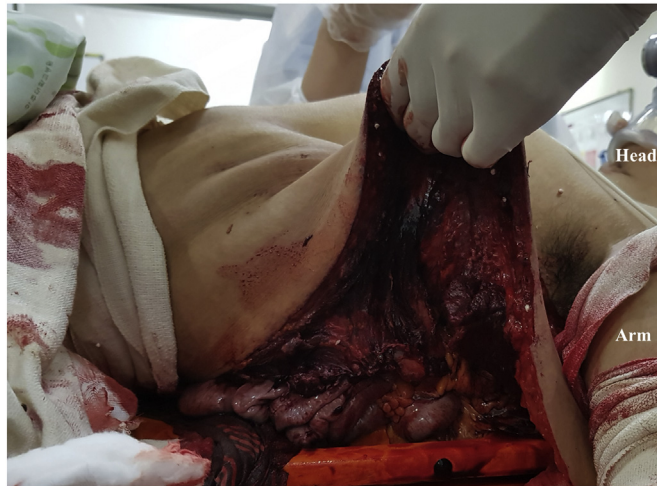E-mail address: [kbhname@aumc.ac.kr](mailto:kbhname@aumc.ac.kr) (B.H. Kang).

<https://doi.org/10.1016/j.tcr.2018.11.012>

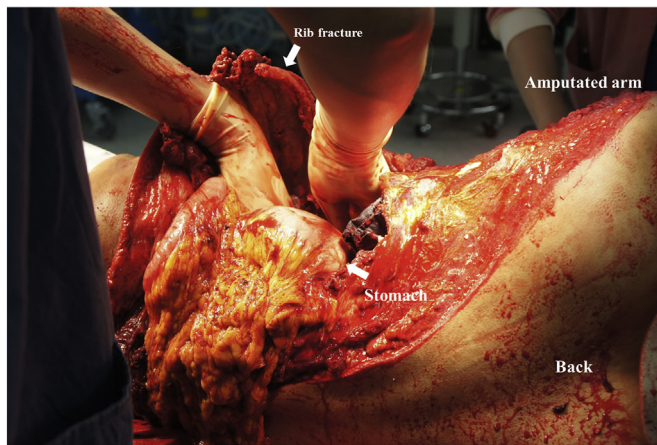
Accepted 23 November 2018

Available online 28 November 2018

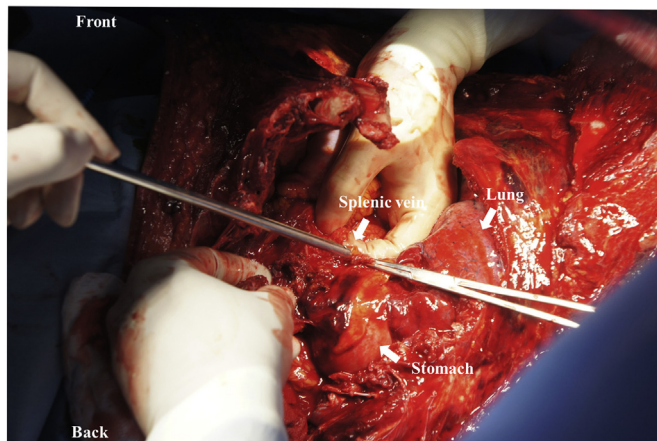
2352-6440/ © 2018 The Authors. Published by Elsevier Ltd. This is an open access article under the CC BY-NC-ND license (<http://creativecommons.org/licenses/by-nc-nd/4.0/>).



**Fig. 1.** Bowel evisceration was identified through ruptured chest wall in trauma bay.



**Fig. 2.** Because open chest wall was large, lateral approach of laparotomy was possible. Ligation of splenic artery was done before drape because of massive bleeding was identified.



**Fig. 3.** Ligation of splenic vein. Lung was visible near ligation site.

splenectomy was much easier than the anterior approach, but the ligament of Treitz was not easily accessible. Inspection of the small bowel revealed small bowel injury, and primary repair was performed. Approaching the right-sided colon and the liver was

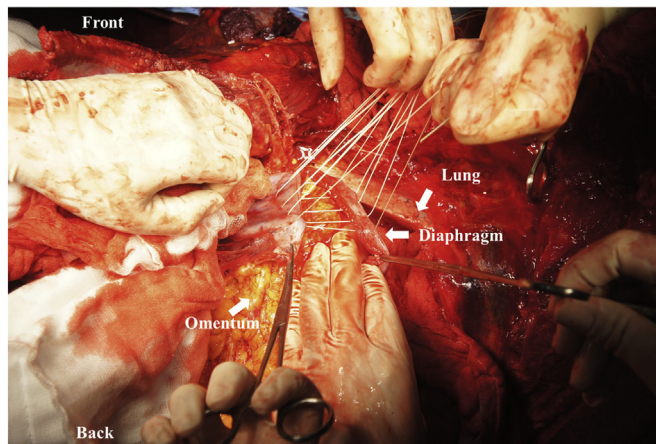


Fig. 4. Suture of the ruptured diaphragm.

impossible—we had to rely on tactile sensation for the procedure. A closed drain could be inserted through the lateral abdominal wall, although we had to rely upon tactile sensation to confirm the position of this drain. After the abdominal procedure had been completed, we inspected the thoracic area and identified lung laceration and air leakage. Stapler sutures were placed, and plates were used for fixation of multiple ribs. The diaphragm was repaired using 1-0 Vicryl sutures via a supra-diaphragmatic approach (Fig. 4). We closed the chest wall after the amputated lesion had been inspected by an orthopedic surgeon (Fig. 5). The patient developed an acute kidney injury secondary to rhabdomyolysis, and continuous renal replacement therapy was needed. Several plastic surgery procedures were required to manage necrosis observed in a part of the chest wall. However, the patient did not need to undergo further abdominal or thoracic surgery and was discharged without complications.

## Discussion

A midline incision has been widely used as the most common approach for abdominal surgery because it is easy, associated with lesser bleeding, and provides rapid and good exposure of the operative field [1]. Thus, a midline incision performed in a patient in a supine position is suitable for an exploratory laparotomy. However, a decubitus position is preferred to perform a unilateral thoracotomy if thoracic injuries are suspected [2]. A lateral thoracotomy offers the advantage of providing a better view and easy access to the posterolateral area of the thoracic cavity in which rib fractures are commonly known to occur. If a combined abdominal and thoracic operation needs to be performed, the supine position is preferred because while an anterior thoracotomy is possible, a lateral laparotomy is almost impossible to perform in such cases.

Chest wall disruption and lung herniation are rare complications; however, surgical repair should be considered to restore physiological pulmonary function and to restore the volume of the chest wall [3]. Additionally, diaphragmatic rupture requires surgical treatment, and a thoracotomy should be performed in those with concomitant lung injuries [4]. In this case, the fracture site and the diaphragm were well exposed using the lateral approach/position. Therefore, the diaphragm could be adequately repaired even though the entire left diaphragm was observed to have ruptured. It might be difficult to approach the posterolateral diaphragm

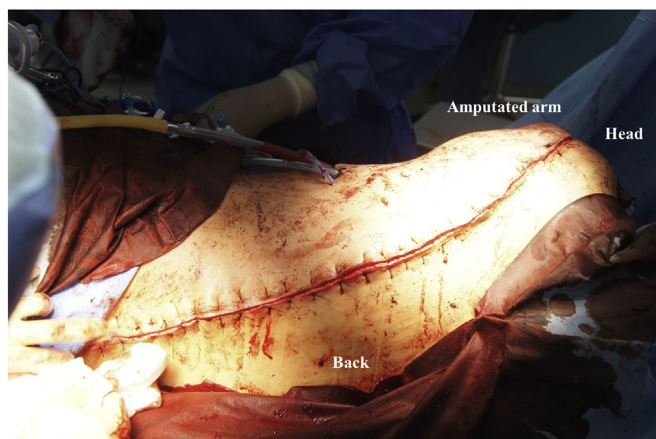

Fig. 5. Closure of the wound. Necrosis of skin and muscle was progressed, additional plastic surgery was required.

during a laparotomy performed in a patient in a supine position. Moreover, in this case, the spleen, the kidneys and the colon were easily visible without the need for further dissection.

Fortunately, this patient recovered well. Of note, using the lateral approach to perform a laparotomy is associated with several limitations: First, approaching the right side was impossible. Therefore, a gauze or tactile sensation had to be utilized to accurately identify the injuries. Relying upon tactile sensation could be useful in the context of solid organs; however, it is not a reliable method in procedures requiring bowel manipulation. Second, limited irrigation and drainage were performed. During the operation, it was difficult to drain all the fluid collected in the paracolic gutter and suprahepatic fossa. Third, extension of the incision was limited. If the open wound was not large enough, lengthening the wound was difficult. Fourth, the surgeon who performed the operation was not familiar with this approach. The splenic fossa was better exposed using this approach than with the use of an anterior approach; however, the anatomical terrain was often confusing. For these reasons, we considered a laparotomy after performing a thoracotomy. Notably, in patients presenting with unstable vital signs, the surgical procedure needs to be short; thus, we planned a secondary operation if the patient developed any peritoneal irritation signs or persistent unstable vital signs. Although an additional laparotomy was not needed, the lateral approach is not recommended to perform a laparotomy.

### Conflict of interest

All authors have no conflict of interest.

### References

- [1] J.W. Burger, M. van't Riet, J. Jeekel, Abdominal incisions: techniques and postoperative complications, *Scand. J. Surg.* 91 (2002) 315–321.
- [2] R.L. Mitchell, The lateral limited thoracotomy incision: standard for pulmonary operations, *J. Thorac. Cardiovasc. Surg.* 99 (1990) 590–595 (discussion 5-6).
- [3] L. Kiraly, M. Schreiber, Management of the crushed chest, *Crit. Care Med.* 38 (2010) S469–S477.
- [4] J.D. Lewis, S.L. Starnes, P.K. Pandalai, L.C. Huffman, C.F. Bulcao, T.A. Pritts, et al., Traumatic diaphragmatic injury: experience from a level I trauma center, *Surgery* 146 (2009) 578–583 (discussion 83-4).