

Brief Communication



Intraoperative Specimen Mammography for Margin Assessment in Breast-Conserving Surgery

Ming Jin ^{1,*}, Ji Young Kim ^{1,*}, Tae Hee Kim ², Doo Kyung Kang ²,
Se Hwan Han ¹, Yongsik Jung ¹

OPEN ACCESS

Received: Mar 20, 2019

Accepted: Dec 5, 2019

Correspondence to

Yongsik Jung

Department of Surgery, Ajou University
Hospital Breast Cancer Center, Ajou University
School of Medicine, 164 World cup-ro,
Yeongtong-gu, Suwon 16499, Korea.
E-mail: smartblade@gmail.com

*These authors contributed equally to this work.

© 2019 Korean Breast Cancer Society
This is an Open Access article distributed
under the terms of the Creative Commons
Attribution Non-Commercial License (<https://creativecommons.org/licenses/by-nc/4.0/>)
which permits unrestricted non-commercial
use, distribution, and reproduction in any
medium, provided the original work is properly
cited.

ORCID iDs

Ming Jin
<https://orcid.org/0000-0003-0414-4506>
Ji Young Kim
<https://orcid.org/0000-0001-5539-7269>
Tae Hee Kim
<https://orcid.org/0000-0002-0520-2395>
Doo Kyung Kang
<https://orcid.org/0000-0002-5397-9334>
Se Hwan Han
<https://orcid.org/0000-0002-0520-2395>
Yongsik Jung
<https://orcid.org/0000-0002-2011-1459>

Conflict of Interest

The authors declare that they have no competing interests.

¹Department of Surgery, Ajou University Hospital, Suwon, Korea

²Department of Radiology, Ajou University Hospital, Suwon, Korea

ABSTRACT

The purpose of this study aimed to determine whether intraoperative specimen mammography is an effective margin assessment method in Asian women. Thus, 182 patients who underwent breast-conserving surgery (BCS) were evaluated. After wide excision, intraoperative specimen mammography was used to assess margin adequacy. The control group comprised 84 patients who underwent BCS and were evaluated for margin of frozen section during surgery. 61.6% patients had dense breasts and 85.7% of dense breasts could margin assess by intraoperative specimen mammography. There were no significant differences in the incidence of extremely close margins ($p = 0.421$) and second operation ($p = 0.252$) between both groups. Significant correlations were found between radiological and histological margins ($R^2 = 0.222$, $p < 0.05$). The frozen section analysis group had longer operative time than the specimen mammography group. The study results show that intraoperative specimen mammography of breast lesions in BCS is useful in identifying margin clearance.

Keywords: Breast neoplasm; Mammography; Margins of excision

Breast cancer treatment with breast-conserving surgery (BCS) requires the establishment of adequate margins to reduce the risk of local recurrence, which can be achieved through several methods. Intraoperative assessment of margin status is commonly performed using frozen section analysis (FSA). However, this technique lacks a standardized sampling method for relatively rounded breast specimens, which is not always practical in a busy unit. Intraoperative specimen mammography has been found useful to identify margin involvement, especially in cases with microcalcification or nonpalpable lesions. Although surgical margin analysis has been acknowledged as a critical component of BCS, the best assessment technique has yet to be determined [1]. Proponents of specimen mammography report that this radiologic procedure allows surgeons to assess excision adequacy and reduce the number of metachronous re-excisions required to achieve margin-negative resection [2].

In patients with dense breast, it is especially difficult to define breast lesions using mammography. Nevertheless, intraoperative specimen mammography may be useful in assessing the margin status of visible or nonvisible lesions on preoperative mammography.

Author Contributions

Data curation: Jin M, Kim JY; Formal analysis: Jin M, Kim JY; Investigation: Kim TH, Kang DK; Methodology: Kim JY; Supervision: Han SH, Jung Y; Validation: Kim TH, Han SH, Jung Y; Writing - review & editing: Jung Y.

To date, no studies have evaluated the effectiveness of specimen mammography in dense breasts. The proportion of Korean women with dense breasts is higher than their Western counterpart [3].

In the present study, we evaluated the influence of preoperative mammography density in specimen mammography analysis. The value of intraoperative specimen mammography in determining the margin status of excised palpable or nonpalpable breast lesions was evaluated. Additionally, the level of agreement between the radiologic and final pathologic interpretations of margin status was analyzed.

Between October 2015 and September 2017, we evaluated 182 patients with breast cancer who underwent intraoperative specimen mammography after BCS at the Ajou University Hospital. Patients with bilateral breast cancer or neoadjuvant chemotherapy or diffuse microcalcifications were excluded. The control group consisted of 84 patients who underwent BCS between January 2014 and December 2014 with the same inclusion criteria and were evaluated for the margin of the frozen section during surgery. We compared the operative time, margin status, and frequency of a second operation for further resection between the 2 groups. The mammogram reports were based on visual analysis by two radiologists. The mammographic findings of breast density were classified according to the following categories, based on the American College of Radiology Breast Imaging Reporting and Data System [4]. The lesions were pathologically confirmed as ductal carcinoma *in situ* (DCIS), invasive ductal carcinoma, lobular carcinoma *in situ*, invasive lobular carcinoma, and other malignant neoplasms. Histologic margins were measured as the closest distance between the specimen's edge and cancer cell location. This study was approved by the Ajou University Hospital Institutional Review Board (IRB No. MED-OBS-11-361). For this type of study, informed consent from the patients was not required.

All surgical procedures were performed by 2 specialized breast cancer surgeons. Preoperatively, nonpalpable lesions with microcalcifications were marked by wire-guided localization, which was performed with a hooked wire through an 18-G spinal needle. Following wire insertion, mediolateral oblique view mammography was performed to identify the wire location. One metallic clip was placed on the superior surface, and 2 metallic clips were placed on the lateral margin. Based on the histopathological results obtained from the first surgery, a second operation was performed in patients exhibiting ink on the tumor surface.

Direction-oriented specimens were sent to the mammography unit. Single-image standard compression magnification radiographs were obtained. Specimen mammography was immediately identified, and if mass or calcifications were near the specimen's margins, further resection was performed upon the surgeons' decision.

Statistical analyses were performed using SPSS version 19.0 (IBM Corp., Armonk, USA). Categorical variables were evaluated using the chi-square test. A p -value < 0.05 was considered statistically significant. Linear regression results are presented as the coefficient with confidence intervals and R^2 values. Univariate and multivariate analyses were performed using logistic regression.

The clinicopathologic characteristics of 182 patients with specimen mammography and 84 patients who underwent FSA after BCS are presented in **Table 1**. After confirmation of margin

Table 1. Comparison of clinicopathological characteristics between patients with specimen mammography versus frozen section analysis

Characteristics	Specimen mammography (n=182)	Frozen section analysis (n=84)	p-value
Mean age (yr)	48.9 (29–81)	44.5 (32–79)	0.414
Menopausal status			0.368
Pre-menopause	106 (58.2)	55 (65.5)	
Post-menopause	76 (41.8)	29 (34.5)	
Histologic findings			0.021
IDC	116 (63.7)	55 (65.5)	
IDC + DCIS	24 (13.2)	19 (22.6)	
DCIS	38 (20.9)	4 (4.8)	
ILC	1 (0.5)	6 (7.1)	
ILC + LCIS	1 (0.5)	0 (0)	
Others	2 (1.2)	0 (0)	
T stage			0.212
Tis	38 (20.9)	4 (4.8)	
T1	119 (65.4)	59 (70.2)	
≥ T2	25 (13.7)	21 (25.0)	
Axillary LN metastasis			0.001
Yes	36 (19.8)	31 (36.9)	
No	146 (80.2)	53 (63.1)	
Further resection			0.467
Intra-operative	24 (13.2)	13 (15.5)	
2nd operation	16 (8.8)	8 (9.5)	
Operation time (min)	85.2 (20–175)	108.4 (45–215)	0.026
Very-close margin* (%)	39 (21.4)	12 (14.3)	0.421
Positive margin† (%)	19 (10.4)	7 (8.3)	0.196
2nd operation (%)	16 (8.8)	8 (9.5)	0.252

Values are presented as mean (range) or number of patients (%).

IDC = invasive ductal carcinoma; DCIS = ductal carcinoma *in situ*; ILC = invasive lobular carcinoma; LCIS = lobular carcinoma *in situ*; LN = lymph node.

*Histological nearest distance from lesion < 1 mm; †Ink on tumor surface.

Table 2. Relationship of preoperative mammographic density and possibility of margin assessment of specimen mammography

Preoperative mammography density	Cases (n=182)	Margin assessment (n=164)	p-value
< 25%	19 (10.4)	19 (100.0)	0.003
25%–50%	51 (28.0)	49 (96.1)	
50%–75%	80 (44.0)	74 (92.5)	
> 75%	32 (17.6)	22 (68.8)	

Values are presented as number of patients (%).

status by two methods, there were no statistical difference in the proportion of further resection (22.0% vs. 25.0%, $p = 0.467$).

Two different intraoperative margin assessment methods were compared in terms of mean operative time, narrowest margin from the lesion, and need of a second operation for further resection. The operative time was significantly shorter in the specimen mammography group than that in the FSA group (85.2 vs. 108.4 minutes, $p = 0.026$). There were no significant differences in the incidence of extremely close margins (< 1 mm) ($p = 0.421$) and second operation ($p = 0.252$) between the 2 groups. A significant difference was found between the preoperative mammographic density and possibility of margin assessment, regardless of lesion status. The comparison is shown in **Table 2**. All patients' specimens with < 25% density in preoperative mammography allowed lesion identification, whereas lesions were confirmed in only 68.8% of patients with specimens with > 75% density. The results indicated that the difficulty in determining the margin status increases with breast density ($p = 0.003$). The correlation between radiological and histological margins is shown in **Figure 1**. A significant

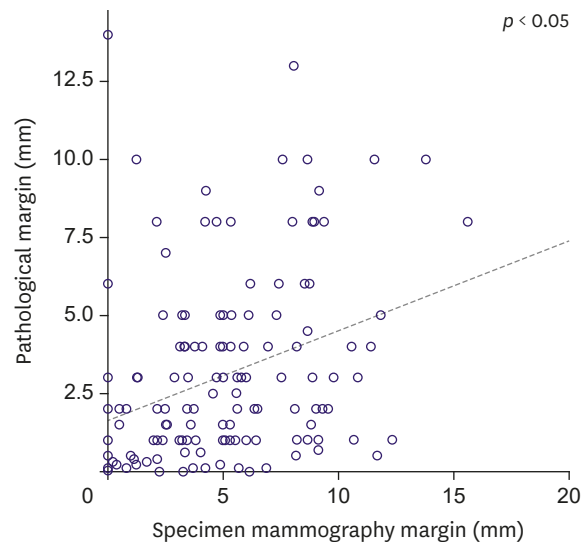


Figure 1. Correlation between the intraoperative specimen radiological margins and the histological margins nearest distance lesion ($R^2 = 0.222$, $p < 0.05$).

correlation was found between intraoperative specimen mammography and histological nearest distance from lesions ($p < 0.05$).

As the use of BCS in oncoplastic surgery expands worldwide, greater efforts are needed to achieve cancer-free margins, which are associated with local recurrence of breast cancer. The reported rates of margin positivity at the initial BCS range from 10% to 27% [5-8]. Furthermore, in the second operation after oncoplastic surgery, it is difficult to find margins with remaining cancer cells, which led several studies to establish the most effective method for intraoperative surgical margin assessment.

Several studies have reported intraoperative methods for pathological evaluation, such as FSA and touch smear and imprint cytology. The re-excision rate of FSA ranges from 3% to 10%, whereas that of imprint cytology ranges from 0% to 33%. Both are significantly lower than that achieved without intraoperative pathological assessment [9,10]. However, FSA has several limitations, such as loss of tissue for permanent pathology, technical difficulties caused by a large amount of adipose tissue, significantly longer operative time, and lower accuracy for nonpalpable lesions and/or those containing microcalcifications [11,12]. Several other radio-guided surgery (RGS) techniques have been proposed to improve margin clearance, including radio-guided occult lesion localization (ROLL) and radioactive seed localization (RSL). ROLL involves an intratumoral injection of a radioactive tracer under ultrasound or stereotactic guidance. The surgical excision range can be detected with a handheld gamma probe. RSL uses a small titanium seed containing ^{125}I , which can be detected in mammography. A recent meta-analysis of 7 randomized control trials (RCTs) demonstrated that RGS reduces operative time but increases excised volume. Moreover, no significant differences were found between RGS and wire-guided localization in terms of positive margin and reoperation rate [13].

Intraoperative specimen radiography can be used in both nonpalpable lesions with calcifications and palpable lesions visible on mammograms. However, few data are available in the literature concerning the accuracy, sensitivity, and specificity of specimen

mammography. Several previous RCTs reported a 15.7% positive margin rate and 5.7% reoperation rate [14-16].

The present study found a significant correlation between radiological and histological margins. However, there are several limitations regarding the data about radiological and histological margins. First, the radiological margins was measured as the closest distance between the resection borders on two-dimensional mammography, whereas the histological margin was microscopically measured as the closest distance from the 6-direction surface of the specimen, Therefore, a mismatch might have occurred between the radiological and histological margin status. Second, after specimen compression in the mammography unit, the direction and margin might have been distorted. A previous retrospective study revealed a significant association between specimen radiographs and histological results [17].

Several factors may affect mammographic breast density, such as age, body mass index, parity, menstrual status, and race [18]. Asian women more frequently have dense breasts on mammography [19,20]. Therefore, the mammographic sensitivity to breast masses rather than calcification might be lower in Asian women than in Western women due to the high frequency of dense breasts. We evaluated the possibility of identifying the lesion on specimen mammography regardless of the initial mammographic density. Based on our results, margin status was confirmed in 97.1% of lesions with < 50% mammographic density and 85.7% of other lesions. Therefore, mammographic density was found to affect margin status identification on specimen mammography.

Therefore, this study suggests that specimen mammography can be useful in assessing margin status, especially in Asian patients with breast cancer who have denser breasts than Western patients. Moreover, preoperative mammographic density can affect margin assessment on specimen mammography. Further RCTs with larger sample sizes are needed to confirm the significant advantage compared with other methods of intraoperative margin assessment.

REFERENCES

1. Weber WP, Engelberger S, Viehl CT, Zanetti-Dallenbach R, Kuster S, Dirnhofner S, et al. Accuracy of frozen section analysis versus specimen radiography during breast-conserving surgery for nonpalpable lesions. *World J Surg* 2008;32:2599-606.
[PUBMED](#) | [CROSSREF](#)
2. Bimston DN, Bebb GG, Wagman LD. Is specimen mammography beneficial? *Arch Surg* 2000;135:1083-6.
[PUBMED](#) | [CROSSREF](#)
3. Kim SH, Kim MH, Oh KK. Analysis and comparison of breast density according to age on mammogram between Korea and western women. *J Korean Radiol Soc* 2000;42:1009-14.
[CROSSREF](#)
4. American College of Radiology. *ACR BI-RADS® Atlas*. 5th edition. Reston (VA): American College of Radiology; 2013.
5. Gajdos C, Tartter PI, Bleiweiss JJ, Hermann G, de Csepe J, Estabrook A, et al. Mammographic appearance of nonpalpable breast cancer reflects pathologic characteristics. *Ann Surg* 2002;235:246-51.
[PUBMED](#) | [CROSSREF](#)
6. Papa MZ, Klein E, Davidson B, Karni T, Sperber F, Koller M, et al. The effect of anesthesia type on needle localization breast biopsy: another point of view. *Am J Surg* 1996;171:242-3.
[PUBMED](#) | [CROSSREF](#)
7. Mullen R, Macaskill EJ, Khalil A, Elseedawy E, Brown DC, Lee AC, et al. Involved anterior margins after breast conserving surgery: is re-excision required? *Eur J Surg Oncol* 2012;38:302-6.
[PUBMED](#) | [CROSSREF](#)

8. Jung W, Kang E, Kim SM, Kim D, Hwang Y, Sun Y, et al. Factors associated with re-excision after breast-conserving surgery for early-stage breast cancer. *J Breast Cancer* 2012;15:412-9.
[PUBMED](#) | [CROSSREF](#)
9. Esbona K, Li Z, Wilke LG. Intraoperative imprint cytology and frozen section pathology for margin assessment in breast conservation surgery: a systematic review. *Ann Surg Oncol* 2012;19:3236-45.
[PUBMED](#) | [CROSSREF](#)
10. Osborn JB, Keeney GL, Jakub JW, Degnim AC, Boughey JC. Cost-effectiveness analysis of routine frozen-section analysis of breast margins compared with reoperation for positive margins. *Ann Surg Oncol* 2011;18:3204-9.
[PUBMED](#) | [CROSSREF](#)
11. Riedl O, Fitzal F, Mader N, Dubsky P, Rudas M, Mittlboeck M, et al. Intraoperative frozen section analysis for breast-conserving therapy in 1016 patients with breast cancer. *Eur J Surg Oncol* 2009;35:264-70.
[PUBMED](#) | [CROSSREF](#)
12. Cendán JC, Coco D, Copeland EM 3rd. Accuracy of intraoperative frozen-section analysis of breast cancer lumpectomy-bed margins. *J Am Coll Surg* 2005;201:194-8.
[PUBMED](#) | [CROSSREF](#)
13. Ahmed M, van Hemelrijck M, Douek M. Systematic review of radioguided versus wire-guided localization in the treatment of non-palpable breast cancers. *Breast Cancer Res Treat* 2013;140:241-52.
[PUBMED](#) | [CROSSREF](#)
14. Bathla L, Harris A, Davey M, Sharma P, Silva E. High resolution intra-operative two-dimensional specimen mammography and its impact on second operation for re-excision of positive margins at final pathology after breast conservation surgery. *Am J Surg* 2011;202:387-94.
[PUBMED](#) | [CROSSREF](#)
15. Layfield DM, May DJ, Cutress RI, Richardson C, Agrawal A, Wise M, et al. The effect of introducing an in-theatre intra-operative specimen radiography (IOSR) system on the management of palpable breast cancer within a single unit. *Breast* 2012;21:459-63.
[PUBMED](#) | [CROSSREF](#)
16. Allweis TM, Kaufman Z, Lelcuk S, Pappo I, Karni T, Schneebaum S, et al. A prospective, randomized, controlled, multicenter study of a real-time, intraoperative probe for positive margin detection in breast-conserving surgery. *Am J Surg* 2008;196:483-9.
[PUBMED](#) | [CROSSREF](#)
17. Mazouni C, Rouzier R, Balleyguier C, Sideris L, Rochard F, Delaloge S, et al. Specimen radiography as predictor of resection margin status in non-palpable breast lesions. *Clin Radiol* 2006;61:789-96.
[PUBMED](#) | [CROSSREF](#)
18. Martin LJ, Boyd NF. Mammographic density. Potential mechanisms of breast cancer risk associated with mammographic density: hypotheses based on epidemiological evidence. *Breast Cancer Res* 2008;10:201.
[PUBMED](#) | [CROSSREF](#)
19. Habel LA, Capra AM, Oestreicher N, Greendale GA, Cauley JA, Bromberger J, et al. Mammographic density in a multiethnic cohort. *Menopause* 2007;14:891-9.
[PUBMED](#) | [CROSSREF](#)
20. El-Bastawissi AY, White E, Mandelson MT, Taplin S. Variation in mammographic breast density by race. *Ann Epidemiol* 2001;11:257-63.
[PUBMED](#) | [CROSSREF](#)