



OPEN

## Establishment of an *Acanthamoeba* keratitis mouse model confirmed by amoebic DNA amplification

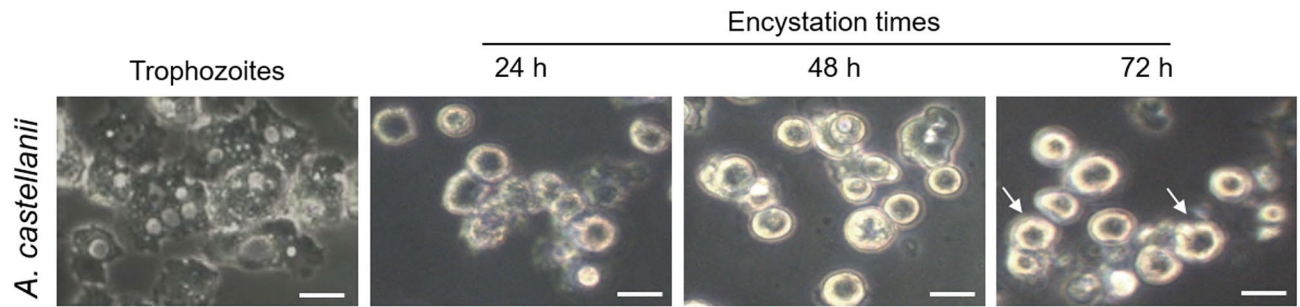
Heekyoung Kang<sup>1,2,6,7</sup>, Hae-Jin Sohn<sup>1,2,7</sup>, A-Young Park<sup>1,2</sup>, A-Jeong Ham<sup>1,2</sup>, Jeong-Heon Lee<sup>1,2</sup>, Young-Hwan Oh<sup>1,2</sup>, Yong-Joon Chwae<sup>1,2</sup>, Kyongmin Kim<sup>1,2</sup>, Sun Park<sup>1,2</sup>, Hongseok Yang<sup>3</sup>, Suk-Yul Jung<sup>4</sup>, Jong-Hyun Kim<sup>5</sup>✉ & Ho-Joon Shin<sup>1,2</sup>✉

*Acanthamoeba castellanii*, the causative agent of *Acanthamoeba* keratitis (AK), occurs mainly in contact lens users with poor eye hygiene. The findings of many in vitro studies of AK, as well as the testing of therapeutic drugs, need validation in in vivo experiments. BALB/c mice were used in this study to establish in vivo AK model. *A. castellanii* cell suspensions (equal mixtures of trophozoites and cysts) were loaded onto 2-mm contact lens pieces and inserted into mouse eyes that were scratched using an ophthalmic surgical blade under anesthesia and the eyelids of the mice were sutured. The AK signs were grossly observed and PCR was performed using P-FLA primers to amplify the *Acanthamoeba* 18S-rRNA gene from mouse ocular tissue. The experimental AK mouse model was characterized by typical hazy blurring and melting of the mouse cornea established on day 1 post-inoculation. AK was induced with at least  $0.3 \times 10^5$  *A. castellanii* cells (optimal number,  $5 \times 10^4$ ), and the infection persisted for two months. The PCR products amplified from the extracted mouse eye DNA confirmed the development of *Acanthamoeba*-induced keratitis during the infection periods. In conclusion, the present AK mouse model may serve as an important in vivo model for the development of various therapeutic drugs against AK.

*Acanthamoeba castellanii*, pathogenic free-living amoebae, are found ubiquitously in a variety of habitats such as freshwater, air conditioner cooling towers, and domestic tap water. *A. castellanii* also exists as a contaminant on contact lenses and lens containers, thus causing *Acanthamoeba* keratitis (AK)<sup>1–3</sup>. Risk factors related to AK include the extended wearing of contact lenses, lack of personal hygiene, contact lens contamination, and exposure to *Acanthamoeba*-contaminated water. Furthermore, non-contact lens users can be infected with AK due to corneal injury, eye surgery, and contaminated water<sup>4–6</sup>. It is thought that the number of AK patients worldwide has increased over the past twenty years due to increased contact lens use and the infections in over 80% of the AK patients were closely related to contact lens wear<sup>7–10</sup>.

In AK, the amoebae infiltrate the corneal stroma and epithelial cells, and this process is accompanied by the progressive infiltration of inflammatory cells. *Acanthamoeba* trophozoites adhere to mannose binding protein on the corneal surface or epithelium and penetrate Bowman's membrane and enter the collagenous stroma. The amoebae continue to produce protease that contribute to the dissolution of the corneal stroma<sup>11</sup>. The signs of infection are a unilateral red eye; severe, unbearable pain; blurred vision; ring-shaped stromal infiltrates; and photophobia. These signs can be initially misdiagnosed as a herpes simplex virus infection or bacterial or fungal keratitis. However, once the disease develops, it is difficult to treat and eventually progresses to a chronic infection. Chronic AK can threaten vision. Early diagnosis and laboratory tests for AK are important for early treatment and preventing irreversible corneal damage. If a diagnosis is delayed or the infection is not treated

<sup>1</sup>Department of Microbiology, Ajou University School of Medicine, Suwon 16499, Republic of Korea. <sup>2</sup>Department of Biomedical Science, Graduate School of Ajou University, Suwon 16499, Republic of Korea. <sup>3</sup>Yonsei Eye Clinic, Yeongtong-gu Bongyeong-ro 1606, Suwon 16704, Republic of Korea. <sup>4</sup>Department of Biomedical Laboratory Science, Molecular Diagnostics Research Institute, School of Health and Medicine, Namseoul University, Cheonan 31020, Republic of Korea. <sup>5</sup>Institute of Animal Medicine, College of Veterinary Medicine, Gyeongsang National University, Jinju 52828, Republic of Korea. <sup>6</sup>Present address: Department of Tropical Medicine and Parasitology, Institute of Endemic Diseases, Seoul National University College of Medicine, Seoul 03080, Republic of Korea. <sup>7</sup>These authors contributed equally: Heekyoung Kang and Hae-Jin Sohn. ✉email: jkim@gnu.ac.kr; hshin@ajou.ac.kr



**Figure 1.** Morphological changes of *A. castellanii* trophozoites into pre-cysts and cysts. *A. castellanii* trophozoites were cultured in encystation medium for 24, 48, and 72 h. The arrows indicate polygonal cysts. Scale bar, 20  $\mu\text{m}$ .

quickly, the amoebae penetrate deeply into the corneal stroma and this can lead to corneal ulcers and the loss of vision<sup>5,12,13</sup>.

With regard to the diagnosis of AK, the use of in vivo confocal microscopy has emerged as a valuable non-invasive tool for the highly sensitive clinical diagnosis of severe infectious keratitis<sup>14,15</sup>. However, the direct detection of amoebae in a corneal scraping specimen is the only reliable method for the diagnosis of AK. Infection confirmation involves the detection of amoebae by culturing *Acanthamoeba* cells from a corneal tissue biopsy sample, contact lenses, and their case. Immunofluorescence assays and several PCR-based methods are also well-established diagnostic methods<sup>16</sup>.

Currently, there are no efficient methods or a single drug that can eliminate both acanthamoeba cysts and trophozoites. AK patients are often treated with disinfectants and antifungal agents, including propamidine isethionate, polyhexamethylene biguanide, neomycin, chlorhexidine, polymyxin B, miconazole, itraconazole, brolene, diamidine compounds, and chlorhexidine gluconate, although corneal opacity or scarring may sometimes occur after treatment<sup>16</sup>. Recently, Hendiger et al.<sup>17</sup> reported silver nanoparticles as a novel potential preventive agent against AK. Many efforts have been made to use silver nanoparticles to treat AK, but there are no effective agents for the treatment of AK. For this reason, a rapid diagnosis and treatment of AK are more effective in suppressing the severity of this disease.

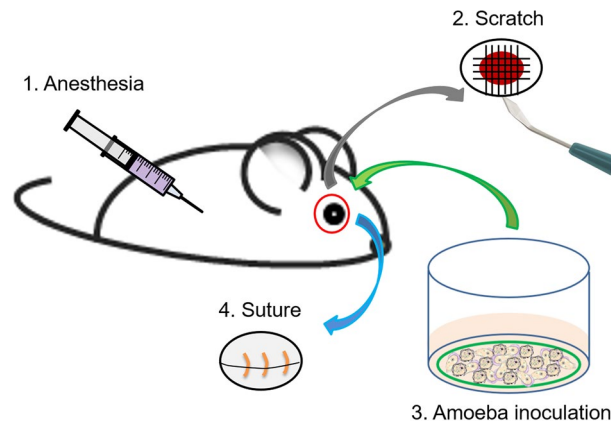
To develop a method for the rapid diagnosis and effective treatment of AK, an AK in vivo model using an appropriate animal model must be established. Primarily, experimental animals, such as rabbits, rats, and hamsters, have been used for AK studies<sup>18–22</sup>. In this study, we aimed to develop an AK-induced in vivo model using mice, which are smaller and more convenient than the experimental animals commonly used. We determined the optimal numbers of *A. castellanii* cells needed in eye inoculation for an AK-induced mouse model. Then, for the effective identification of *A. castellanii* in the AK-induced mouse, the *Acanthamoeba* 18S-rRNA gene was amplified from eye tissue samples by PCR. This AK mouse model may be useful for the development of preventive or therapeutic agents as well as in vivo molecular biologic, pathologic, and immunologic AK studies.

## Materials and methods

**Experimental animal.** Eight-week-old female BALB/c mice (Orient, Seongnam, Korea) were maintained in the specific pathogen free (SPF) facility accredited by the Association for Assessment and Accreditation of Laboratory Animal Care (AAALAC). A total of 81 animals were employed. The study was carried out in compliance with the Animal Research: Reporting of In Vivo Experiments (ARRIVE) guidelines. All the mouse experiments were approved by the Institutional Animal Care and Use Committee of the Ajou University Medical Center (AUMC-IACUC-2016-0009, approval number AJ-IBC-2020-0002). And all methods were carried out in accordance with relevant guidelines and regulations.

**Cultivation and encystation of *A. castellanii*.** *A. castellanii* (AK/AJ1; clinical isolate from an AK patient at Ajou Medical Center) trophozoites were axenically cultured in 75-cm<sup>2</sup> culture flasks using PYG medium at 30 °C<sup>23</sup>. The formation of *A. castellanii* cysts was induced by cultivating the organism in encystment solution (95 mM NaCl, 5 mM KCl, 8 mM MgSO<sub>4</sub>, 0.4 mM CaCl<sub>2</sub>, 1 mM NaHCO<sub>3</sub>, and 20 mM Tris-HCl; pH 9.0), according to previous reports<sup>24,25</sup>. First, *A. castellanii* trophozoites were harvested, washed twice with phosphate-buffered saline (PBS, pH 7.4), and centrifuged. After the final step, the trophozoites were added to 75-cm<sup>2</sup> culture flasks (concentration adjusted to  $1 \times 10^6$  cells/ml) and treated with 10 ml of encystment solution for 72 h at 30 °C (Fig. 1). To confirm the formation of cysts, morphological changes were observed using an inverted microscope (Olympus, Shinjuku, Tokyo, Japan).

**Inoculation of *A. castellanii* into the mouse eyes.** To establish the AK mouse model, a mixture of *A. castellanii* trophozoites and cysts, or only *A. castellanii* trophozoites were inoculated into the mouse eyes. Briefly, the harvested *A. castellanii* trophozoites and cysts were mixed in equal amounts at a concentration of  $5 \times 10^5$  cells/ml. A total of  $1 \times 10^6$  cells/ml were placed in a 1-ml tube, followed by centrifugation at 1500 rpm for 3 min. Commercial contact lenses (Proclear 1-day lens, Cooper Vision, Inc., NY, USA) were cut into 2-mm per slide using a punch and placed in a 24-well plate containing 10  $\mu\text{l}$  of PBS (pH 7.4). The pellet from centrifugation was



**Figure 2.** Procedures for the development of the experimental AK model mouse. 1. The mice were anesthetized. 2. The eyeballs of the mice were scratched. 3. *A. castellanii* trophozoites and cysts were cultivated on the contact lenses and inoculated into the mouse eyes. 4. The eyelids of the mice were sutured. The other eye of each mouse was used for sham-infection (control). The figure was prepared by H-J Sohn using Adobe photoshop (version 7.0.1, <https://www.adobe.com/>).

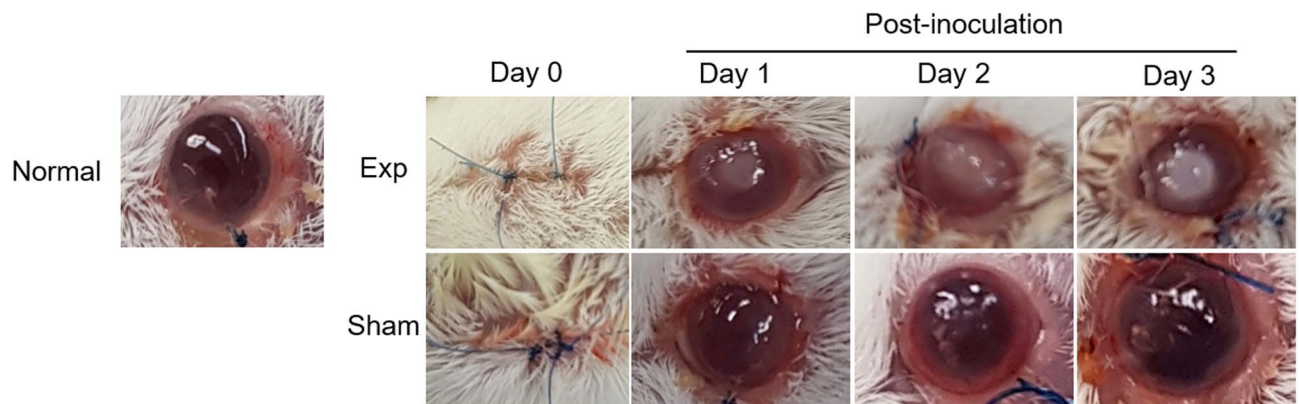
applied onto a 2-mm contact lens piece and incubated at 30 °C for 1 h (Fig. 1). Eight-week-old female BALB/c mice were anesthetized using Ketamine and Xylazine solution (5 mg/ml Ketamine combined with 1 mg/ml Xylazine; 0.3 ml/20 g of body weight)<sup>24</sup>. After administering corneal anesthesia to the mice using 0.5% Proparacaine eye drops (Alcaine, Alcon, TX, USA), the eyeballs were scratched with a syringe needle and an ophthalmic blade. The *A. castellanii*-inoculated lens was placed onto the mouse eyelid, and the eyelid was sutured with 6/0 nylon sutures (Woorimedical, Namyangju, Korea) for complete contact of *A. castellanii* with the eyes (Fig. 2). Sham-infection was carried out by placing only a clear, uninoculated lens onto the mouse eyes and the subsequent procedures were performed as mentioned above.

**Observation of experimental mouse keratitis signs.** To observe the development of keratitis, the mouse eyelid sutures were sequentially removed at intervals from day 1 to day 3 or day 1 to day 7. The experiments to determine the optimal number of *Acanthamoeba* cells for the development of AK in mice were performed from day 1 to day 3, and the experiments to establish the AK mouse model were performed from day 1 to day 7. The eyeballs were observed with the naked eye for signs such as white ring corneal infections, circular edema with increased central corneal thickness, and possible keratitis.

**Confirmation of *A. castellanii*-induced keratitis in mice by PCR.** To extract ocular DNA from the keratitis-induced mice, the mouse eyeballs were removed under anesthesia/euthanasia methods during each observation period. The eyeball tissue was chopped with a pair of surgical scissors in 100 µl of PBS (pH 7.4) in a 1-ml tube. Tissue lysis buffer and proteinase K were added to the eyeball tissue-containing tubes, according to the instructions of DNA Extraction Kit (cat. No. 51304, Qiagen, France). After lysis at 56 °C, DNA extraction was performed.

To amplify the *A. castellanii* 18S-rRNA gene from the eyeballs of the keratitis-induced mice, PCR was performed using specific P-FLA primers: forward 5'-CGCGGTAATCCAGCTCCAATAGC-3' and reverse 5'-CAG GTTAAGGTCTCGTTCGTTA AC-3', as described previously<sup>26,27</sup>. A total of 2 ng of genomic DNA was used as a template and 10 µl of Noblezyme PCR Plus Premix 2× (Noble Bioscience Inc., Suwon, Korea) was added to the PCR tubes. The PCR conditions using the P-FLA primers were as follows: 95 °C for 5 min, 40 cycles of 94 °C for 1 min, 60 °C for 1 min, 72 °C for 3.5 min, and a final extension step at 72 °C for 10 min. The PCR products were electrophoresed on 1% agarose gel and the image was analyzed using the Gel Doc system (Bio-Rad, CA, USA). Subsequently, 18S-rDNA sequencing was performed to confirm whether the amplified PCR products matched published *Acanthamoeba* 18S-rDNA sequences by comparison to the sequences for *Acanthamoeba* 18-rDNA in the GenBank (no. KT185626.1) database.

**Determination of the optimal number of *A. castellanii* cells for the development of mouse keratitis.** To determine the optimal number of *A. castellanii* cells required for the development of AK in mice, suspensions containing *A. castellanii* trophozoites and cysts (mixed in equal number) were serially diluted to yield the following concentrations:  $5 \times 10^5$ ,  $2.5 \times 10^5$ ,  $1.25 \times 10^5$ ,  $0.625 \times 10^5$ ,  $0.3125 \times 10^5$ , and  $0.1 \times 10^5$  cells/ml. The subsequent procedures were the same as those described for the development of the experimental AK mouse model.



**Figure 3.** Induction and observation of AK in the experimental mouse model. To induce keratitis,  $1 \times 10^6$  *A. castellanii* cells (trophozoites and cysts mixed in equal numbers) were cultivated on the lenses and inoculated into the mouse eyes. The AK signs were observed from day 1 to day 3. Normal, untreated healthy mouse; Sham, sham-infection groups; Exp, experiment groups.

## Results

**Morphological confirmation of *A. castellanii* cyst formation.** To induce cyst formation in *A. castellanii* cells, the trophozoites were cultured for 24, 48, and 72 h and observed using an inverted microscope. After 24 h inducing cyst formation, half of the amoebae transformed into round-shaped pre-cysts with a single cell wall. Most of the amoebae were found to pre-cysts form after 48 h induction. After 72 h of cyst induction, various forms of polygonal double-walled cysts were observed (Fig. 1).

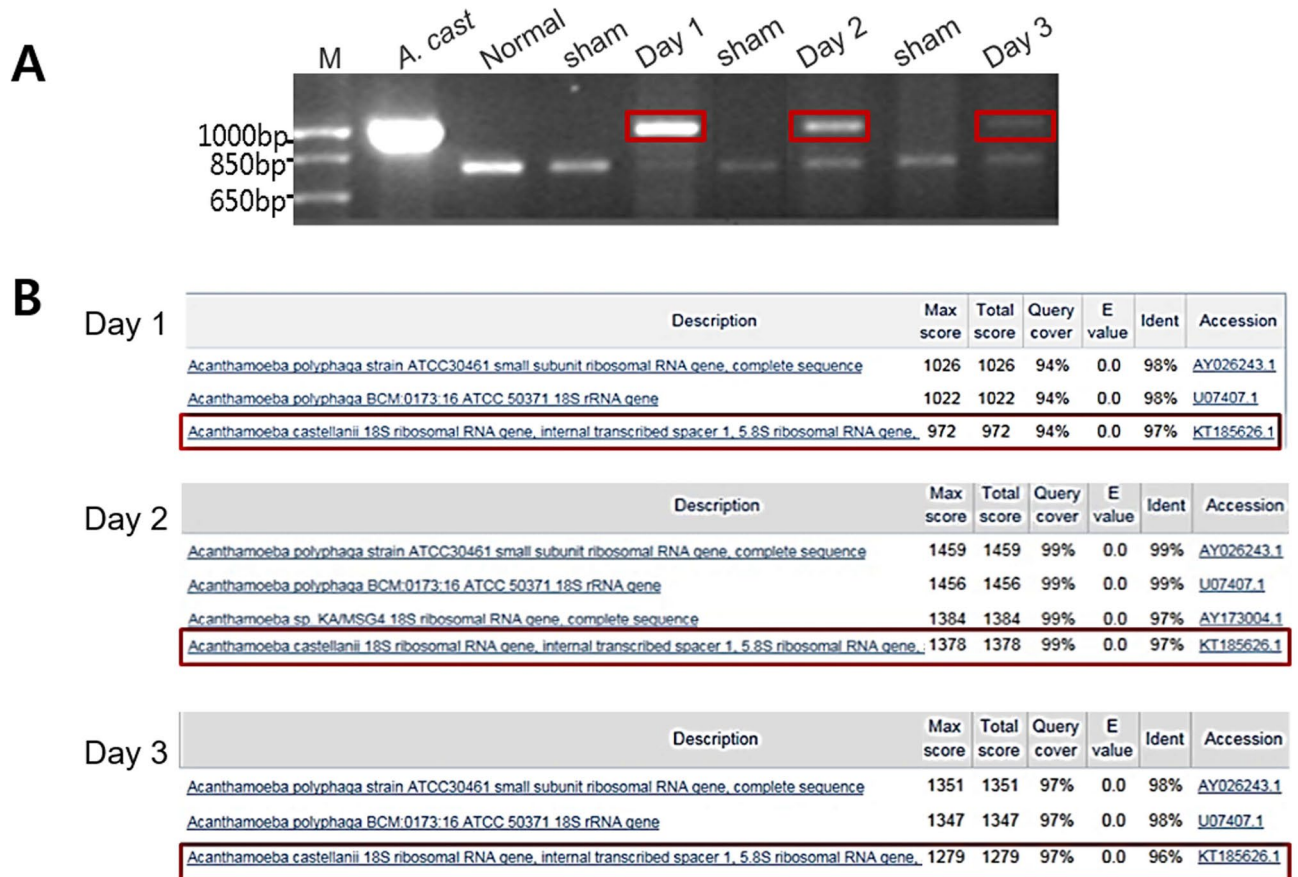**Occurrence of AK in mouse eyes.** To preferentially induce AK, 2-mm lenses inoculated with  $1 \times 10^6$  *A. castellanii* cells (trophozoites and cysts mixed in equal number) were inserted into the mouse eyes (Fig. 2). According to previous study of Ren and Wu<sup>22</sup>, keratitis signs were observed in the mouse eyes between days 1 and 3. On the first day of AK induction, small, white, round edema was observed in the mouse eyes and typical round edema was observed on days 2 and 3. In contrast, following sham-infection, no AK signs were seen (Fig. 3).

***A. castellanii* DNA identification from the ocular tissues of AK mice.** To identify the cause of AK development in mice, the genomic DNA samples from mouse eye tissues were subjected to PCR analysis using P-FLA primers for the amplification of the *A. castellanii* 18S-rRNA gene. Amplification of the DNA samples obtained from the infected mouse eyeballs on days 1, 2, and 3 yielded amplicons 1080 bp in size, the same size as that obtained from an *A. castellanii* positive control. In contrast, the same size amplicon was not obtained from normal or sham-infection mouse DNA (Fig. 4A). The PCR products amplified with the P-FLA primers were subjected to DNA sequence analysis and a gene homology search. A comparison of the results with the 18S-rDNA of *A. castellanii* showed that the amplified products obtained from the DNA extracted on days 1, 2, and 3 were 97, 96, and 97% homologous, respectively (Fig. 4B).

**Optimal number of *A. castellanii* cells required for keratitis development in mice.** To determine the optimal number of *A. castellanii* cells for the development of AK in mice, serially diluted *A. castellanii* cell suspensions (mixtures of equal amounts of trophozoites and cysts) were inoculated into the mouse eyes. When  $5$ ,  $2.5$ ,  $1.25$ , and  $0.625 \times 10^5$  *A. castellanii* cells were used for inoculation, keratitis signs were observed in the eyes of all mice between days 1 and 3. On the first day of AK induction, weak infections, characterized by cloudy eyeballs, were observed in the eyes of all mice, along with progressive corneal infections on days 2 and 3. In contrast, the sham-infection mice did not show any apparent keratitis signs (Fig. 5). The results of the PCR 18S-rDNA amplification revealed that the DNA samples from keratitis-induced mouse eyeballs obtained on days 1, 2, and 3 yielded 1,080-bp amplicons, the same size amplicon as that obtained when *A. castellanii* was used as a positive control (Fig. 5).

When  $0.3125 \times 10^5$  (Fig. 5E) or  $0.1 \times 10^5$  (Fig. 5F) *A. castellanii* cells were inoculated, no apparent keratitis induction was observed in the mouse eyes on day 1. Subsequently, white circular ulcers with increased central corneal infections of the mouse eyes were observed on days 2 and 3 (Fig. 5E, F). In contrast, the sham-infection eyes did not show any signs (Fig. 5E, F). The 18S-rDNA identification revealed that the DNA samples obtained on day 1 and day 3 from mouse eyeballs inoculated with  $0.3125 \times 10^5$  and  $0.1 \times 10^5$  *A. castellanii* cells did not yield 1080-bp amplicons corresponding to the 18S-rRNA gene (Fig. 5K, L). As shown Fig. 5K and L, the mouse inoculated with  $0.3125 \times 10^5$  and  $0.1 \times 10^5$  *A. castellanii* cells did not induced AK. In the result, we decided the optimal number of  $0.5 \times 10^5$  *A. castellanii* between  $0.3125 \times 10^5$  and  $0.625 \times 10^5$  to induce AK in mice.

**AK development following the treatment of mouse eyes with *A. castellanii* trophozoites alone.** To determine whether amebic trophozoites alone could induce AK development in mice to the same extent as treatment with the trophozoite and cyst mixtures,  $0.5 \times 10^5$  *A. castellanii* trophozoites were inoculated



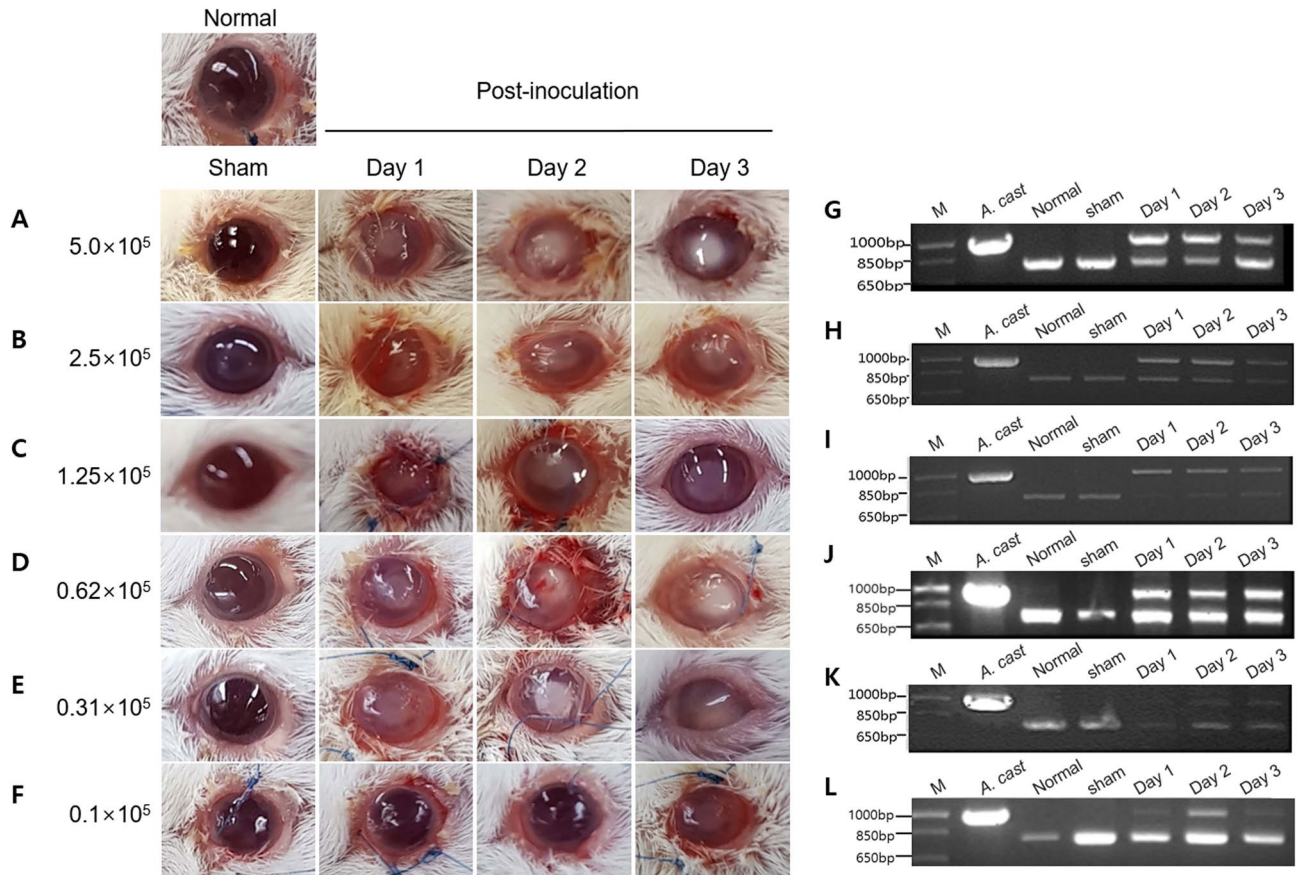
**Figure 4.** Identification of *A. castellanii* 18S-rDNA from AK mouse eye tissues. When the AK signs appeared, genomic DNA was extracted from ocular tissues on days 1, 2, and 3. (A) PCR was performed using P-FLA primers for the amplification of the *A. castellanii* 18S-rRNA gene. PCR products (amplicon with a size of 1,080 bp marked in red box) obtained on days 1, 2, and 3 post-inoculation were sequenced. *A. cast.*, genomic DNA of *A. castellanii* trophozoites ( $1 \times 10^6$ ) used as a positive control; Normal, DNA extracted from normal mouse eye tissues used as a negative control; Sham, DNA extracted from tissues of sham-infection mice on days 1, 2, and 3 used as a negative control; M, size marker. (B) Their homology to the 18S-rDNA of *A. castellanii* was confirmed by an NCBI BLAST search. Bands of about 800 bp in size were identified as mouse DNA by DNA sequencing.

into the mouse eyes, as in the previous method. Keratitis signs were observed in the eyes of all mice between days 1 and 7. On the first day of AK induction, weak infections with cloudy eyeballs were observed in the eyes of all mice, along with progressive corneal infections (Fig. 6). The results of 18S-rDNA amplification by PCR revealed that the DNA samples of keratitis-induced mouse eyeballs obtained between days 1 and 7 yielded 1080-bp amplicons, the same as that observed when *A. castellanii* was used as a positive control (Fig. 6).

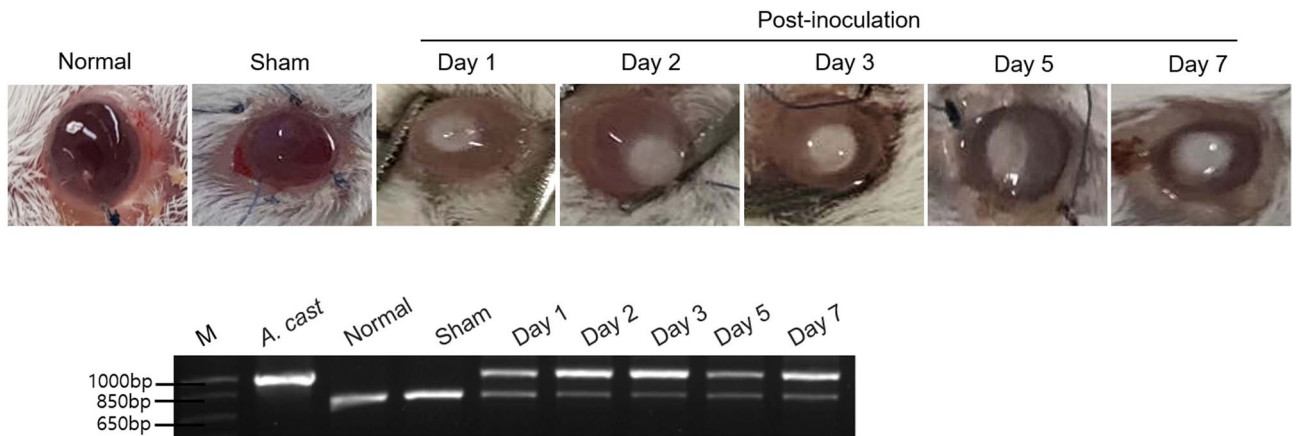
**Establishment of an AK mouse model.** The optimal number of *A. castellanii* cells that could cause keratitis in mouse eyes was found to be  $0.5 \times 10^5$ . Finally,  $0.5 \times 10^5$  cells were loaded onto 2-mm lens pieces and inoculated into mouse eyes, and keratitis signs were observed from day 1 to 7 post-inoculation (Fig. 7). On day 1, white ring corneal infections and circular edema were observed in the mouse eyes. This progressed to corneal infections on day 2 until day 7. In contrast, the sham-infection mice did not show keratitis signs (Fig. 7A). To confirm the cause of AK development in mice, PCR products from mouse eyeball DNA samples extracted on days 1–7 post-inoculation were obtained. The samples yielded 1,080-bp amplicons corresponding to the *A. castellanii* 18S-rRNA gene, which was the same as that obtained when *A. castellanii* was used as a positive control (Fig. 7B). The amplified DNA bands obtained from DNA samples extracted on days 1, 2, 3, 5, and 7 showed 91–97% homology with the 18S-rDNA of *A. castellanii* (Fig. 8).

## Discussion

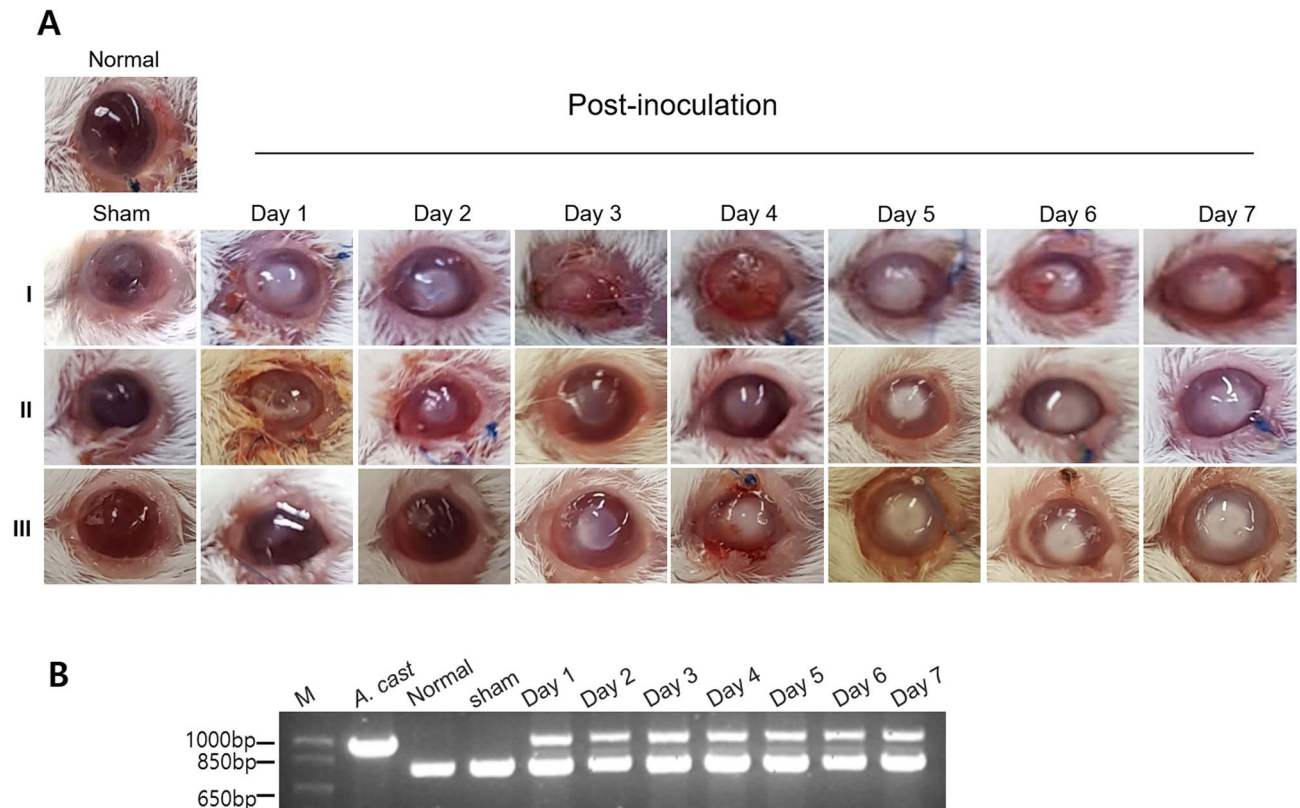
The ubiquitous, free-living amoebae *A. castellanii* and *A. polyphaga* can cause AK in animals and humans and 85–88% of the patients with AK use contact lenses. *Acanthamoeba* spp. have been isolated from the contact lens cases of AK patients, and it is widely believed that contact lenses serve as vectors for transmitting infectious *Acanthamoeba* trophozoites to the eye. *Acanthamoeba* spp. can attach themselves to the soft surfaces of contact



**Figure 5.** Observation of AK development in mice inoculated with serially diluted *A. castellanii* suspensions. (A-F) *A. castellanii* cell suspensions (equal mixtures of trophozoites and cysts) were serially diluted to concentrations of 5, 2.5, 1.25, 0.625, 0.3125, and 0.1 × 10<sup>5</sup> cells and inoculated into the mouse eyes. AK signs were observed from day 1 to 3 (Normal: untreated healthy mouse, Sham: sham-infection group). Regardless of the occurrence of keratitis signs, genomic DNA was extracted from all mouse tissues on days 1, 2, and 3. (G-L) The genomic DNA samples obtained from the mouse eye tissues were subjected to PCR using P-FLA primers to amplify the *A. castellanii* 18S-rRNA gene (right for figures). *A. cast*, genomic DNA of *A. castellanii* trophozoites (1 × 10<sup>6</sup>), used as a positive control; Normal, DNA extracted from normal mouse eye tissue, used as a negative control; Sham, DNA extracted from sham-infection mouse tissue, used as a negative control. M, size marker.



**Figure 6.** Observation of AK induced by *A. castellanii* trophozoites alone in the experimental mouse model. *A. castellanii* trophozoites (0.5 × 10<sup>5</sup>) were added onto lenses, which were then inoculated into the mouse eyes. The AK signs were observed from day 1 to 7. PCR using P-FLA primers for the amplification of the *A. castellanii* 18S-rRNA gene was performed. *A. cast*, genomic DNA of *A. castellanii* trophozoites (1 × 10<sup>6</sup>) used as a positive control; Sham, sham-infection; Normal, untreated healthy mouse eye; M, size marker.




**Figure 7.** Observation of AK and 18S-rDNA amplification in mice inoculated with  $5 \times 10^4$  *A. castellanii* cells. A total of  $0.5 \times 10^5$  *A. castellanii* cells (a mixture of equal amounts of trophozoites and cysts) were loaded onto contact lenses, which were inoculated into the mouse eyes. The AK signs were observed from day 1 to 7. To confirm the causative agent of AK, genomic DNA extracted from the ocular tissues on days 1, 2, 3, 4, 5, 6, and 7 were subjected to PCR using P-FLA primers to amplify the *A. castellanii* 18S-rRNA gene. All experiments were performed triplicate (I, II and III). *A. cast*, genomic DNA of *A. castellanii* trophozoites ( $1 \times 10^6$ ) used as a positive control; Normal, untreated healthy mouse eye; Sham, sham-infection; M, size marker.

lenses and the cornea, progressing the infection. The signs of AK include photophobia, ring-like stromal infiltrates, ulcerations, retinal lesions, epithelial defects, lid edema, and severe pain<sup>1,14,28,29</sup>.

Since AK is mostly chronic, early diagnosis and treatment of the disease are important. Sometimes, AK is misdiagnosed as a fungal or herpes simplex infection, which only coinfects with 10–23% of the *Acanthamoeba* infections<sup>30,31</sup>. Furthermore, preventing AK infection is important. This can be done by keeping contact lens cases clean and not wearing lenses while swimming or showering. In addition, exposure to contaminated water and injury to the cornea should be avoided<sup>32</sup>.

Although there has been some progress in the research regarding the infection mechanism of AK in vitro, in vivo studies using animal models, such as rabbits and rats, have rarely been performed. Ren and Wu<sup>22</sup> evaluated clinically, histologically and statistically rat and mouse models of AK in three different ways. They reported that the intrastromal injection of *Acanthamoeba* was the most effective way to establish the rat or mice models of AK. In our study, the mouse was infected by inserting a lens cultured with *Acanthamoeba* trophozoites and cysts and we confirmed complete infection signs after 3 days. The *Acanthamoeba* 18S-rRNA gene was amplified from eye tissue samples using PCR for the effective identification of *A. castellanii*. In addition, in previous mouse studies, AK was induced by the direct intrastromal injection of amoebae into mouse corneas using a microneedle<sup>33</sup>. However, this procedure is complicated because the amoebae need to be injected precisely into the intrastromal cornea, a procedure for which ophthalmologists are required. Moreover, this method of inducing keratitis is artificial. Therefore, in this study, we attempted to construct an animal model of AK that could be produced easily and quickly. Previously, Ge et al.<sup>34</sup> performed similar study to our AK model. However, the infection method is different, using only *Acanthamoeba* trophozoites on filter paper, not contact lenses. The signs gradually weakened after showing the most severe signs on the 5th day. In our model, the signs gradually progressed to chronic after the infection. Therefore, it is expected that our model will be more useful in the chronic symptomatic AK mouse model. In addition, some experiments require a large number of animals for statistical significance. In this model, AK can be induced in mice using contact lenses in a manner that is relatively similar to natural infections.

Other previous studies have used pigs, rabbits, and rats as animal models for AK<sup>20,35,36</sup>. As a preliminary experiment in our study, the AK experiments were first performed using rats. However, the rats were difficult to handle, only a limited number of animals were available, and their corneas were too thick for AK induction (data not shown). Therefore, this experiment was conducted with mice, which are widely used, cheap, easy to handle, and can be used in large numbers in experiments.



**Figure 8.** The nucleotide sequence and homology analysis of 18S-rDNA obtained from the eyes of keratitis-induced mice. DNA samples extracted on days 1 to 7 post-inoculation were sequenced. After DNA alignment was performed and homology was analyzed using an NCBI BLAST search.

In this study, we mainly constructed an AK mouse model by mixing the trophozoite and cyst forms of *A. castellanii* because, in natural AK infections, both these forms of *A. castellanii* have been detected in contact lenses. Of course, we also induced AK by inoculating mouse eyes with trophozoites alone. In contrast, keratitis signs in mouse eyes inoculated with *A. castellanii* lysate or excretory-secretory protein (ESP) (concentration of each, 10 mg/ml) prepared according to previous reports did not develop in any mice between days 1 and 7 (Figure S1)<sup>37</sup>.

The eyes of the mice were scratched with a syringe needle and ophthalmic blade because it is difficult to infect the cornea without any damage. A previous study showed that the incidence of AK was affected by corneal damage before infection<sup>38</sup>. After scratching the mouse eyeballs, contact lenses containing *A. castellanii* were placed onto the eyes of the mice. Next, the eyelids were sutured. This is because it is difficult to naturally attach contact lenses to the mouse eyeballs because they are rounder than human eyeballs, and it was necessary to ensure the complete attachment of the lenses to the cornea. To detect the incidence of AK signs, the eyelid sutures were sequentially removed on the days of observation.

To determine the minimum number of *Acanthamoeba* cells necessary to induce AK in mice, a mixture containing equal amounts of *A. castellanii* trophozoites and cysts was serially diluted from  $1 \times 10^6$  to  $0.1 \times 10^5$  cells. Infection was induced in mice inoculated with a minimum of  $0.3 \times 10^5$  or  $0.1 \times 10^5$  cells. However, this was not the same as the gross observation results of the mouse eyes and the PCR analysis of ocular DNA samples from repeated experiments. Therefore,  $0.5 \times 10^5$  was determined to be the most stable number of *A. castellanii* cells required for AK induction. After AK induction, signs were observed for up to two months and were confirmed to persist and worsen (data not shown). The AK induction experiments were performed at least thrice. Therefore, it was determined that  $0.5 \times 10^5$  *A. castellanii* cells can be used to establish an AK mouse model.

The diagnosis of AK is mainly based on in vitro testing, in which lenses and lens solution in the lens cases of patients with AK are cultured or corneal biopsies are performed. In addition, PCR can also be used to confirm the amplification of *Acanthamoeba* DNA<sup>33,39</sup>. In this study, when eye tissues and contact lenses from the mice with AK were cultured on PYG medium and non-nutrient agar plates, the presence of *A. castellanii* was not consistent because of rapid fungal growth, even after treatment with anti-fungal agents (data not shown). Next, the eyes of mice that developed keratitis were stained with hematoxylin–eosin (HE) to confirm the presence of amoebae between and underneath the cornea. However, *A. castellanii* was not observed on the mouse eyeballs. It was impossible to observe the amoebae under these conditions because the corneas of the mice with AK are too thin, and it would be difficult to obtain a tissue specimen. To establish our study as keratitis model, it is necessary to perform histopathological or immunohistochemical study of infected eyeballs and to isolate *Acanthamoeba* trophozoites. In further study, it will be required the production of specific monoclonal antibodies for the immunohistochemistry.

To address these problems, genomic DNA was extracted from the eye tissues of mice with AK, and PCR was performed with P-FLA primers that amplified the 18S rRNA *Acanthamoeba* gene. The PCR analysis of DNA from



the ocular tissues of mice with AK produced an amplicon of the same size (1080 bp) as that of *Acanthamoeba* 18S-rDNA, and sequence analysis of the obtained PCR products revealed that AK was indeed induced by *A. castellanii*. The bands that were shorter than 800 bp were identified as the 18S rRNA mouse gene (*Mus musculus*).

The number of reported cases of AK is increasing worldwide every year because many people use contact lenses for various reasons such as vision correction or cosmetic purposes. There have been many attempts to treat AK using various therapeutic agents, but the best way to overcome the disease is a quick and easy way to construct an AK mouse model for in vivo experiments. Finally, the present AK mouse model will be an important platform for in vivo testing in investigations into the molecular biology, pathology, and immunology of AK, and assist in the development of new pharmacological agents for the treatment and prevention of AK.

## Conclusion

In this study, the establishment of an AK mouse model was attempted. *A. castellanii* cell suspensions were loaded onto 2-mm contact lens pieces for insertion into mouse eyes that were scratched using an ophthalmic surgical blade under anesthesia and the eyelids of the mice were sutured. The experimental AK mouse model, characterized by typical hazy blurring and melting of the mouse corneas, was established on day 1 post-inoculation. PCR products amplified from the extracted mouse eye DNA confirmed the development of *Acanthamoeba*-induced keratitis. The optimal number of *Acanthamoeba* to induce AK in mice is  $0.5 \times 10^5$  cells. The PCR products amplified from the extracted mouse eye DNA confirmed the development of *Acanthamoeba*-induced keratitis during the infection periods. In conclusion, the present AK mouse model may serve as an important in vivo model for the development of various therapeutic drugs against AK.

Received: 19 August 2020; Accepted: 4 February 2021

Published online: 18 February 2021

## References

1. Visvesvara, G. S. & Stehr-Green, J. K. Epidemiology of free-living ameba infections. *J. Protozool.* **37**, 25S–33S. <https://doi.org/10.1111/j.1550-7408.1990.tb01142.x> (1990).
2. Marciano-Cabral, F., Puffenberger, R. & Cabral, G. A. The increasing importance of *Acanthamoeba* infections. *J. Eukaryot. Microbiol.* **47**, 29–36. <https://doi.org/10.1111/j.1550-7408.2000.tb00007.x> (2000).
3. Schuster, F. L. & Visvesvara, G. S. Free-living amoebae as opportunistic and non-opportunistic pathogens of humans and animals. *Int. J. Parasitol.* **34**, 1001–1027. <https://doi.org/10.1016/j.ijpara.2004.06.004> (2004).
4. Fears, A. C., Metzinger, R. C., Killeen, S. Z., Reimers, R. S. & Roy, C. J. Comparative in vitro effectiveness of a novel contact lens multipurpose solution on *Acanthamoeba castellanii*. *J. Ophthalmic. Inflamm. Infect.* **8**, 19. <https://doi.org/10.1186/s12348-018-0161-8> (2018).
5. Khan, N. A. *Acanthamoeba*: biology and increasing importance in human health. *FEMS Microbiol. Rev.* **30**, 564–595. <https://doi.org/10.1111/j.1574-6976.2006.00023.x> (2006).
6. Tananuvat, N., Techajongjintana, N., Somboon, P. & Wannasan, A. The first *Acanthamoeba* keratitis case of non-contact lens wearer with HIV infection in Thailand. *Korean J. Parasitol.* **57**, 505–511. <https://doi.org/10.3347/kjp.2019.57.5.505> (2019).
7. Padzik, M. *et al.* Assessment of in vitro dynamics of pathogenic *Acanthamoeba* strains originating from contact lens wearers with infectious keratitis. *Ann. Parasitol.* **62**, 331–336. <https://doi.org/10.1186/s12886-019-1210-2> (2019).
8. Yoder, J. S. *et al.* *Acanthamoeba* keratitis: the persistence of cases following a multistate outbreak. *Ophthalmic. Epidemiol.* **19**, 221–225. <https://doi.org/10.3109/09286586.2012.681336> (2012).
9. Li, W., Wang, Z., Qu, J., Zhang, Y. & Sun, X. *Acanthamoeba* keratitis related to contact lens use in a tertiary hospital in China. *BMC Ophthalmol.* **19**, 202. <https://doi.org/10.1186/s12886-019-1210-2> (2019).
10. Papa, V., Rama, P., Radford, C., Minassian, D. C. & Dart, J. K. G. *Acanthamoeba* keratitis therapy: time to cure and visual outcome analysis for different antiamebic therapies in 227 cases. *Br. J. Ophthalmol.* **104**, 575–581. <https://doi.org/10.1136/bjophthalmol-2019-314485> (2020).
11. Clarke, D. W. & Niederkorn, J. Y. The pathophysiology of *Acanthamoeba* keratitis. *Trends Parasitol.* **22**, 175–180 (2006).
12. Behera, H. S. & Satpathy, G. Characterisation and expression analysis of trophozoite and cyst proteins of *Acanthamoeba* spp. isolated from *Acanthamoeba* keratitis (AK) patient. *Mol. Biochem. Parasitol.* **205**, 29–34. <https://doi.org/10.1016/j.molbio.2016.03.009> (2016).
13. Lindquist, T. D., Doughman, D. J., Rubenstein, J. B., Moore, J. W. & Campbell, R. C. *Acanthamoeba*-contaminated hydrogel contact lenses. Susceptibility to disinfection. *Cornea* **7**, 300–303 (1988).
14. Vaddavalli, P. K. *et al.* Role of confocal microscopy in the diagnosis of fungal and *Acanthamoeba* keratitis. *Ophthalmology* **118**, 29–35. <https://doi.org/10.1016/j.ophtha.2010.05.018> (2011).
15. Roth, M. *et al.* Development and assessment of a simulator for in vivo confocal microscopy in fungal and *Acanthamoeba* keratitis. *Curr. Eye Res.* <https://doi.org/10.1080/02713683.2020.1772830> (2020).
16. Lorenzo-Morales, J., Khan, N. A. & Walochnik, J. An update on *Acanthamoeba* keratitis: diagnosis, pathogenesis and treatment. *Parasite* **22**, 10. <https://doi.org/10.1051/parasite/2015010> (2015).
17. Hendiger, E. B. *et al.* Silver Nanoparticles as a Novel Potential Preventive Agent against *Acanthamoeba* Keratitis. *Pathogens* <https://doi.org/10.3390/pathogens9050350> (2020).
18. Polat, Z. A., Ozcelik, S., Vural, A., Yildiz, E. & Cetin, A. Clinical and histologic evaluations of experimental *Acanthamoeba* keratitis. *Parasitol. Res.* **101**, 1621–1625. <https://doi.org/10.1007/s00436-007-0704-7> (2007).
19. Van Klink, F. *et al.* Systemic immune response to *Acanthamoeba* keratitis in the Chinese hamster. *Ocul. Immunol. Inflamm.* **5**, 235–244. <https://doi.org/10.3109/09273949709085064> (1997).
20. Avila-Blanco, M. E., Martin-Perez, T., Ventura-Juarez, J. & Perez-Serrano, J. Experimental keratitis in rats caused by *Acanthamoeba* griffini: A kinetic histopathological study. *Parasite Immunol.* **42**, e12692. <https://doi.org/10.1111/pim.12692> (2020).
21. Niederkorn, J. Y. *et al.* Susceptibility of corneas from various animal species to in vitro binding and invasion by *Acanthamoebacastellanii*. *Invest. Ophthalmol. Vis. Sci.* **33**, 104–112 (1992).
22. Ren, M. & Wu, X. Evaluation of three different methods to establish animal models of *Acanthamoeba* keratitis. *Yonsei Med. J.* **51**, 121–127 (2010).
23. Visvesvara, G. S. & Balamuth, W. Comparative studies on related free-living and pathogenic amoebae with special reference to *Acanthamoeba*. *J. Protozool.* **22**, 245–256. <https://doi.org/10.1111/j.1550-7408.1975.tb05860.x> (1975).
24. Moon, E. K., Chung, D. I., Hong, Y. C., Ahn, T. I. & Kong, H. H. *Acanthamoebacastellanii*: gene profile of encystation by ESTs analysis and KOG assignment. *Exp. Parasitol.* **119**, 111–116. <https://doi.org/10.1016/j.exppara.2008.01.001> (2008).

25. Sohn, H. J. *et al.* Efficient liquid media for encystation of pathogenic free-living amoebae. *Korean J. Parasitol.* **55**, 233–238. <https://doi.org/10.3347/kjp.2017.55.3.233> (2017).
26. Kang, H. *et al.* Effective PCR-based detection of *Naegleria fowleri* from cultured sample and PAM-developed mouse. *Eur. J. Protistol.* **51**, 401–408. <https://doi.org/10.1016/j.ejop.2015.07.003> (2015).
27. Tsvetkova, N. *et al.* The identification of free-living environmental isolates of amoebae from Bulgaria. *Parasitol. Res.* **92**, 405–413. <https://doi.org/10.1007/s00436-003-1052-x> (2004).
28. Abjani, F., Khan, N. A., Yousuf, F. A. & Siddiqui, R. Targeting cyst wall is an effective strategy in improving the efficacy of marketed contact lens disinfecting solutions against *Acanthamoeba castellanii* cysts. *Cont. Lens. Anterior. Eye* **39**, 239–243. <https://doi.org/10.1016/j.clae.2015.11.004> (2016).
29. Marciano-Cabral, F. & Cabral, G. *Acanthamoeba* spp. as agents of disease in humans. *Clin. Microbiol. Rev.* **16**, 273–307. <https://doi.org/10.1128/cmr.16.2.273-307.2003> (2003).
30. Bouheraoua, N. *et al.* Prognostic factors associated with the need for surgical treatments in *Acanthamoeba* keratitis. *Cornea* **32**, 130–136. <https://doi.org/10.1097/ICO.0b013e31826429bd> (2013).
31. Tu, E. Y. *et al.* The relative value of confocal microscopy and superficial corneal scrapings in the diagnosis of *Acanthamoeba* keratitis. *Cornea* **27**, 764–772. <https://doi.org/10.1097/ICO.0b013e31816f27bf> (2008).
32. Maycock, N. J. & Jayaswal, R. Update on *Acanthamoeba* keratitis: diagnosis, treatment, and outcomes. *Cornea* **35**, 713–720. <https://doi.org/10.1097/ICO.0000000000000804> (2016).
33. Berk, R. S., Hazlett, L. D. & Beisel, K. W. Genetic studies on resistant and susceptibility genes controlling the mouse cornea to infection with *Pseudomonas aeruginosa*. *Antibiot. Chemother.* **1971**(39), 83–91. <https://doi.org/10.1159/000414336> (1987).
34. Ge, Z., Qing, Y., Zicheng, S. & Shiyong, S. Rapid and sensitive diagnosis of *Acanthamoeba* keratitis by loop-mediated isothermal amplification. *Clin. Microbiol. Infect.* **19**, 1042–1048 (2013).
35. Alizadeh, H. *et al.* Successful immunization against *Acanthamoeba* keratitis in a pig model. *Cornea* **14**, 180–186 (1995).
36. Said, N. A., Shoeir, A. T., Panjwani, N., Garate, M. & Cao, Z. Local and systemic humoral immune response during acute and chronic *Acanthamoeba* keratitis in rabbits. *Curr. Eye Res.* **29**, 429–439. <https://doi.org/10.1080/02713680490522470> (2004).
37. Lee, J. *et al.* Excretory and secretory proteins of *Naegleria fowleri* induce inflammatory responses in BV-2 microglial cells. *J. Eukaryot. Microbiol.* **64**, 183–192. <https://doi.org/10.1111/jeu.12350> (2017).
38. van Klink, F. *et al.* The role of contact lenses, trauma, and Langerhans cells in a Chinese hamster model of *Acanthamoeba* keratitis. *Invest. Ophthalmol. Vis. Sci.* **34**, 1937–1944 (1993).
39. Stothard, D. R., Hay, J., Schroeder-Diedrich, J. M., Seal, D. V. & Byers, T. J. Fluorescent oligonucleotide probes for clinical and environmental detection of *Acanthamoeba* and the T4 18S rRNA gene sequence type. *J. Clin. Microbiol.* **37**, 2687–2693. <https://doi.org/10.1128/JCM.37.8.2687-2693.1999> (1999).

## Acknowledgements

This research was supported by a grant of the Basic Science Research Program through the National Research Foundation (NRF) funded by the Ministry of Science and ICT, Republic of Korea (2018R1D1A1B07047302).

## Author contributions

Conceptualization, H.K., H.-J.S., J.-H.K. and H.-J.S.; Data curation, H.K., H.-J.S. and A.-Y.P.; Formal analysis, H.-J.S. and A.-J.H.; Funding acquisition, H.-J.S.; Investigation, H.K., A.-Y.P., A.-J.H., J.-H.L. and Y.-H.O.; Methodology, H.K., A.-Y.P., A.-J.H., S.-Y.J. and J.-H.L.; Project administration, H.-J.S.; Resources, H.-J.S. and H.-J.S.; Supervision, J.-H.K. and H.-J.S.; Validation, H.K. and A.-Y.P.; Writing—original draft, H.K., H.Y., S.-Y.J., J.-H.K. and H.-J.S.; Writing—review and editing, Y.-J.C., K.K., S.P., J.-H.K. and H.-J.S.. All authors have read and agreed to the published version of the manuscript.

## Competing of interests

The authors declare no competing interests.

## Additional information

**Supplementary Information** The online version contains supplementary material available at <https://doi.org/10.1038/s41598-021-83738-4>.

**Correspondence** and requests for materials should be addressed to J.-H.K. or H.-J.S.

**Reprints and permissions information** is available at [www.nature.com/reprints](http://www.nature.com/reprints).

**Publisher's note** Springer Nature remains neutral with regard to jurisdictional claims in published maps and institutional affiliations.



**Open Access** This article is licensed under a Creative Commons Attribution 4.0 International License, which permits use, sharing, adaptation, distribution and reproduction in any medium or format, as long as you give appropriate credit to the original author(s) and the source, provide a link to the Creative Commons licence, and indicate if changes were made. The images or other third party material in this article are included in the article's Creative Commons licence, unless indicated otherwise in a credit line to the material. If material is not included in the article's Creative Commons licence and your intended use is not permitted by statutory regulation or exceeds the permitted use, you will need to obtain permission directly from the copyright holder. To view a copy of this licence, visit <http://creativecommons.org/licenses/by/4.0/>.

© The Author(s) 2021