

# Cone-beam computed tomography and digital model analysis of maxillary buccal alveolar bone thickness for vertical temporary skeletal anchorage device placement

Hai Van Giap, Ju Young Lee, Hieu Nguyen, Hwa Sung Chae, Young Ho Kim, and Jeong Won Shin  
Suwon, South Korea

**Introduction:** This study aimed to quantify the buccal alveolar bone thickness (BABT) in the maxillary molar region to provide a practical guideline for vertical temporary skeletal anchorage device (TSAD) placement using cone-beam computed tomography (CBCT). It also aimed to develop a linear regression model for use in digital models to predict available BABT. **Methods:** The sample for this retrospective study consisted of 31 sites (24 patients; mean age, 28.75 years; range, 18-44 years) in which vertical TSADs were placed successfully in the maxillary posterior interradicular area during the total arch distalization procedure. BABT was measured at 3 points of the interradicular space using CBCT, and the buccal alveolar region thickness (BART), which included buccal-attached gingival thickness and the buccal alveolar bone, was measured using the digital model. In CBCT, BABT was measured at the most convex point of the lamina dura of the root adjacent to the vertical TSAD mesially, at the most convex point of the lamina dura of the root adjacent to the vertical TSAD distally, and the central point between the mesial and distal points. Three linear measurements were obtained at 2, 4, and 6 mm apical to the alveolar crest: the mesial thickness, the central thickness ( $\text{central}_{\text{CBCT}}$ ), and the distal thickness. In the digital model, the most convex points of the clinical crowns of 2 teeth adjacent to vertical TSAD and their contact point along with the corresponding Will Andrews and Lawrence Andrews ridge were identified. The horizontal distance paralleling the model base was digitally measured and recorded at 3 positions: the mesial, central, and distal points. Then, the following 3 linear measurements were taken directly on each 3-dimensional dental model: the mesial thickness, the central thickness ( $\text{central}_{\text{Model}}$ ), and the distal thickness. **Results:** Both BABT and BART at the central position ( $\text{central}_{\text{CBCT}}$ , 3.44 mm;  $\text{central}_{\text{Model}}$ , 6.28 mm) were thicker than at the 2 exterior positions (mesial thickness, 2.16; distal thickness, 2.59 mm; mesial thickness, 2.74 mm; distal thickness, 2.99 mm). BABT was thinnest at 2 mm from the alveolar crest, and there was no statistically significant difference between 4 mm and 6 mm. There was a strong correlation between  $\text{central}_{\text{Model}}$  and  $\text{central}_{\text{CBCT}}$ . **Conclusions:** The mean BABT and BART at the central position, in which we suggest placing vertical TSADs, were  $3.44 \pm 0.69$  mm in CBCT and  $6.28 \pm 1.11$  mm in the digital model, respectively. The minimum BABT and BART at the central position in which vertical TSAD was placed successfully were 2.38 mm in CBCT and 4.25 mm in the digital model. There was a strong correlation between  $\text{central}_{\text{CBCT}}$  and  $\text{central}_{\text{Model}}$ , and we developed a linear regression model that resulted in a useful formula for estimating the actual available BABT at the central position:  $\text{central}_{\text{CBCT}} = 0.57 \times \text{central}_{\text{Model}} - 0.15$ . (Am J Orthod Dentofacial Orthop 2022;161:e429-e438)

Molar and total arch distalization are nonextraction treatment modalities. Either one of these can correct molar relationships or relieve arch

length discrepancies without jeopardizing esthetics and stability.<sup>1</sup> For these procedures, orthodontic temporary skeletal anchorage devices (TSADs) are widely used

From the Department of Orthodontics, Institute of Oral Health Science, School of Medicine, Ajou University, Suwon, South Korea.

Hai Van Giap and Ju Young Lee are joint first authors and contributed equally to this work.

All authors have completed and submitted the ICMJE Form for Disclosure of Potential Conflicts of Interest, and none were reported.

Address correspondence to: Jeong Won Shin, Department of Orthodontics, Institute of Oral Health Science, School of Medicine, Ajou University, 164,

Worldcup-ro, Yeongtong-gu, Suwon-si, Gyeonggi-do 16499, South Korea; e-mail, [orthoshin@aumc.ac.kr](mailto:orthoshin@aumc.ac.kr) or [orthoshin@empal.com](mailto:orthoshin@empal.com).

Submitted, November 2020; revised and accepted, December 2021.

0889-5406/\$36.00

© 2022 by the American Association of Orthodontists. This is an open access article under the CC BY-NC-ND license (<http://creativecommons.org/licenses/by-nc-nd/4.0/>).

<https://doi.org/10.1016/j.ajodo.2021.12.013>

because they do not generate undesirable reciprocal effects, and their success does not depend on the patient's cooperation.<sup>2</sup> Interradicular regions, zygomatic buttresses, and palatal regions, are frequently used for placing TSADs in the clinical setting.<sup>3-6</sup> Although interradicular TSADs are relatively easy to install, the risk of root destruction should be considered in patients in which there are limited dimensions of alveolar bone, if neighboring teeth are too close in the interradicular region.<sup>7</sup> TSADs must be relocated if the interradicular space is insufficient or when >2 mm of distalization is required.<sup>8</sup>

Increasing the space between TSAD and the root can be a way to avoid TSAD relocation; toward this purpose, Yamada et al<sup>9</sup> tried to incline the installation angle. These authors suggested installing TSADs at an oblique angle of 20°-30° to the long axis of the proximal tooth. If there is an adequate amount of buccal alveolar bone in the maxillary molar area, it is possible to install TSADs upright, parallel to the long axis of the tooth. This avoids the possibility of root damage during insertion and prevents contact between the TSAD and the root during distal tooth movement. Moreover, installing vertical TSADs does not require a surgical procedure when miniplates are used. Hence, vertically installed TSADs are useful for molar or total arch distalization in the maxilla.

In dentistry, cone-beam computed tomography (CBCT) has become widely used. It provides accurate anatomic information, such as alveolar bone thickness and interroot distance.<sup>10,11</sup> However, although radiation dose and the costs of CBCT are lower than those of multidetector computed tomography, they are still higher than conventional x-rays.<sup>12,13</sup> Thus, if it is possible to assess the available space from study models, not every patient should be evaluated with CBCT. Recently, 3-dimensional (3D) imaging of digital models has become more popular as an alternative to the traditional plaster models.<sup>14-20</sup> Digital models can be fully calibrated so that the results are always 1:1 in real life. This method not only reduces measurement errors compared with conventional procedures on plaster models, but it is also much easier and less time-consuming.

The purposes of this study were to determine the adequate buccal alveolar bone thickness (BABT) for installing TSADs vertically in a maxillary molar region using CBCT evaluation and also to see if BABT can be determined using digital models by comparing them with the CBCT values.

## MATERIAL AND METHODS

This retrospective study sample consisted of patients treated with vertical TSADs by an orthodontist (J.Y.L., with >20 years of TSAD experience) from January 1,

2017 to July 31, 2020. The patients' vertical TSADs were placed successfully during the orthodontic total arch distalization process. The TSADs (1.5 mm × 11 mm) (ACR screws; Biomaterial Korea Co, Seoul, South Korea) were installed vertically in the buccal alveolar bone area of proximal teeth (Figs 1 and 2). Vertical TSADs were defined as successful when they remained stable until the end of treatment.

A total of 114 sites of the maxillary posterior buccal alveolar bone area were found, in which 109 sites were placed vertical TSADs successfully, and 5 sites were a failure (success rate: 95.6%). To match the CBCT data with digital model data, a total of 31 sites from 24 patients were included in this study (Table 1). The mean age of the patients was 28.75 years (range, 18-44 years).

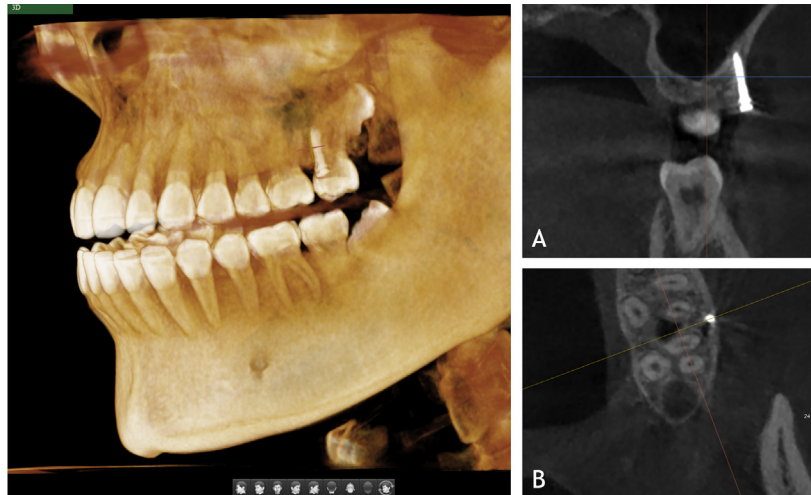
The exclusion criteria included patients with rotated teeth, periodontal diseases or missing maxillary molars. We also used the American Board of Orthodontics' step gauge to select the appropriate buccolingual inclination of molars, in which the lingual cusps must be within 1 mm of the straight edge.

This study was approved by the Institutional Review Board of the Ajou University Hospital (Institutional Review Board no: AJIRB-MED-MDB-20-477).

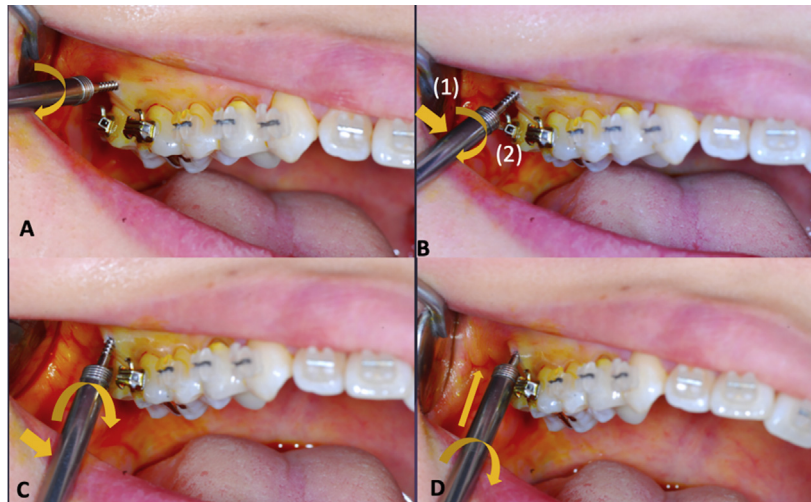
Easy-to-identify and reproducible landmarks were chosen, and all measurements were made according to the same protocol. BABT and buccal alveolar region thickness (BART) were measured using CBCT and digital models at 3 points of the interradicular space, mesially, centrally, and distally, with data from pretreatment (before TSADs insertion) records.

The 3D analysis software (Anatomage, Santa Clara, Calif) was used to import and evaluate the 3D CBCT scans (Green CT2 PHT-65LHS; Vatech, Gyeonggi-do, Korea). Each sample was scanned using the following exposure protocol: 99 kVp; 16 mA; 0.3-mm voxel size; scan time, 9 seconds; and 12 × 9 cm field of view. The images were aligned using a standard method to accurately measure the bone thickness.<sup>21</sup> The image was first aligned from the coronal view and then was adjusted in the sagittal plane so that the bony architecture was symmetrical and a 0° line would pass through the alveolar crest at the same level bilaterally. The image was then aligned from the sagittal view by adjusting the axial plane parallel with the palatal plane. Although the image remained vertical, it was rotated so that the CBCT slice ran through the buccal segment containing all locations to be measured. Maintaining this orientation, axial slices were taken at 2, 4, and 6 mm apical to the alveolar crest (Fig 3, A).

Figure 3, B shows a diagram of the measurements at each location. Alveolar bone thickness was measured at 3 points: the most convex point of the lamina dura of tooth adjacent to vertical TSAD mesially, the most



**Fig 1.** Illustration of the vertical TSAD: **A**, Coronal view; **B**, Axial view.



**Fig 2.** Multiple angle adjustment technique for vertical TSADs: **A**, Initial notch formation: first, place the TSAD perpendicular to the alveolar bone surface and turn it 2-3 times to form the initial notch and avoid slippage; **B**, Angle adjustment: unscrew the TSAD in the opposite direction. At the entrance to the notch, tilt the shaft by 15-20° (1) and turn it 2-3 more times to form a new adjusted notch for the tilted TSAD (2); **C**, Vertically upright: repeat this angle adjustment process 3-5 times to form a notch that can support the TSAD parallel to the axial inclination of the adjacent tooth and vertically upright; **D**, Final insertion: when a final notch that can securely stabilize the vertical TSAD has been formed, install the TSAD until the neck of TSAD is located 1 mm above the surface of the attached gingiva.

convex point of the lamina dura of root adjacent to vertical TSAD distally, and the central point between the mesial and distal points. A line was drawn from the most convex point of the lamina dura of the tooth adjacent to TSAD mesially to that of the root adjacent to TSAD distally. This line was bisected perpendicularly by line CD. Two other lines, AB and EF, parallel to line CD, were drawn perpendicularly at the most convex point of the lamina dura of tooth adjacent to vertical

TSAD mesially and that of root adjacent to TSAD distally, respectively. The following 3 linear measurements were made at levels of 2-, 4-, and 6-mm apical to the alveolar crest: mesial ( $\text{mesial}_{\text{CBCT}}$ ), central ( $\text{central}_{\text{CBCT}}$ ), and distal thickness ( $\text{distal}_{\text{CBCT}}$ ). Their corresponding cortical bone thicknesses were recorded.

The TSAD should be placed out of the movement path of the roots to prevent root contact damage during vertical TSAD placement and distalization. The “danger

**Table I.** Sample population

Sample population	TSAD position	No. of vertical TSADs
Group I (n = 14)		
2 patients	PM2-M1	4
12 patients	M1-M2	24
Group II (n = 7)		
	PM2-M1	7
	M1-M2	7
Group III (n = 3)		
	PM2-M1	2
	M1-M2	1
Total (n = 24)		45

Note. Group I included patients having 2 vertical TSADs in which the position of vertical TSADs placed on the left and right were in similar positions (PM2-M1 or 1 M1-M2).

Group II included patients having 2 vertical TSADs in which the TSADs on the left and right were placed in different positions (1 TSAD placed in PM2-M1 and 1 TSAD placed M1-M2).

Group III included patients having 1 vertical TSAD placement.

PM2-M1, the interradicular space between the maxillary second premolar and first molar; M1-M2, the interradicular space between the first and second molars.

zone” was defined and measured from the contact point of 2 crowns adjacent to the TSAD to the line that connected the most convex points of the lamina dura of the 2 roots. To prevent root damage during TSAD placement and teeth distalization, the TSAD should be placed outside of this zone (Fig 4).

After plaster models were constructed with white stone, they were digitalized using Trios 3 (3Shape, Copenhagen, Denmark). The data were analyzed with OrthoAnalyzer (3Shape).

First, the most convex point of the clinical crown of each tooth around vertical TSAD and its corresponding Will Andrews and Lawrence Andrews (WALA) ridge were identified (Fig 5). The WALA ridge is a landmark immediately superior to the mucogingival junction, and its shape reflects basal bone.<sup>22</sup> The horizontal distance paralleling the model base was digitally measured and recorded at 3 positions: the most mesial point, the central point, and the most distal point. The following 3 linear measurements were made directly on each 3D dental model: mesial (mesial<sub>Model</sub>), central (central<sub>Model</sub>), and distal thickness (distal<sub>Model</sub>). The area on central thickness outside the mesiodistal line to the WALA ridge was defined as a safe zone and measured (safe<sub>Model</sub>) (Fig 6).

### Statistical analysis

All measurements were performed twice by the same examiner (H.V.G.), 2 weeks apart. The resulting intraclass correlation coefficient indicated high reliability (intraclass correlation coefficient >0.90). The data were analyzed using SPSS (version 23.0; IBM, Armonk, NY).

The measurements of the right and left sides in group I were averaged because there was no statistical difference ( $P > 0.05$ ) (Table I). Therefore, the sample size of this study was 31, including 11 between the maxillary second premolar and the first molar and 20 between the first molar and the second molar. With this sample size, the linear regression analysis of central<sub>CBCT</sub> and central<sub>Model</sub> had a power of 100% at the significance level of 0.05 (version 3.5.1; R Foundation for Statistical Computing, Vienna, Austria).

Because of the normal distribution of variables, 1-way analysis of variance test and Tukey post-hoc tests were performed to compare the BABT between 2-, 4-, and 6-mm apical to the alveolar crest on CBCT. To assess the correlation between the measurements on CBCT and the digital model, Pearson correlation analysis was used. Then, linear regression analysis was used to predict the actual value of alveolar bone thickness for vertical TSAD placement. A significance level of 5% was used in all tests.

### RESULTS

The interradicular BABT ranged from 1.27 mm to 5.13 mm (Fig 7). The BABT at the central position (central<sub>CBCT</sub>,  $3.44 \pm 0.69$  mm) was thicker than those at the 2 exterior positions (mesial<sub>CBCT</sub>,  $2.16 \pm 0.67$  mm; distal<sub>CBCT</sub>,  $2.40 \pm 0.66$  mm) (Table I). The minimum central<sub>CBCT</sub> was 2.38 mm between the maxillary second premolar and the first molar, and the maximum central<sub>CBCT</sub> was 5.13 mm between the maxillary first molar and the second molar (Table II; Fig 7).

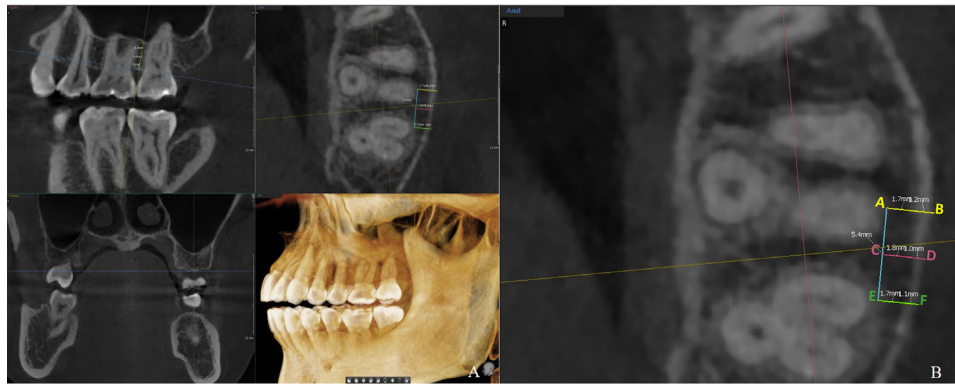
The BABT was thinnest at 2 mm, and there was no significant difference between 4 and 6 mm ( $P < 0.05$ ) (Table II).

The buccal cortical bone thickness ranged from 1.06 to 1.73 mm. The cortical bone-only thickness at the mesial, central, and distal positions was  $1.20 \pm 0.12$ ,  $1.22 \pm 0.17$ , and  $1.22 \pm 0.13$  mm, respectively, and there were no significant differences between 2, 4, and 6 mm (Table III).

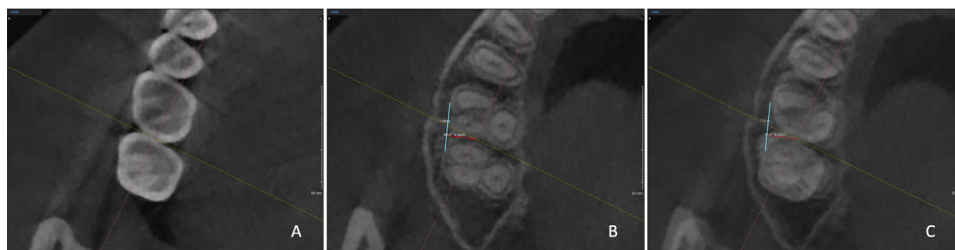
The thickness of the danger zone was  $2.07 \pm 0.65$  mm, and it tended to decrease from the alveolar crest to the apex significantly (Table IV).

The BART on digital models ranged from 0.45 to 8.44 mm in the investigated area (Table V). It was thickest at the central position (central<sub>Model</sub>,  $6.28 \pm 1.11$  mm) compared with the 2 exterior positions (mesial<sub>Model</sub>,  $2.74 \pm 0.96$  mm; distal<sub>Model</sub>,  $2.99 \pm 0.99$  mm) (Fig 8).

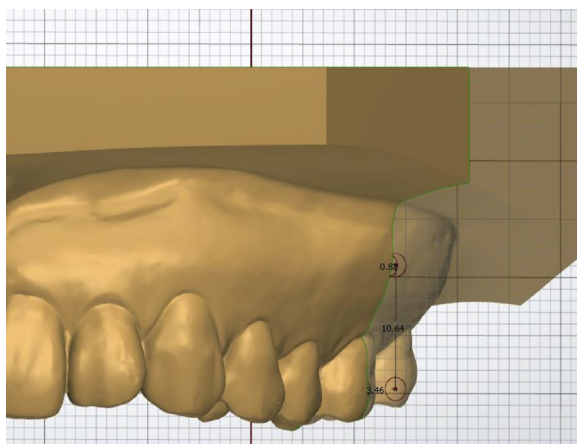
The thinnest point of central<sub>Model</sub> was 4.25 mm between the maxillary second premolar and the first molar, and the thickest point was 8.44 mm between the maxillary first molar and the second molar.



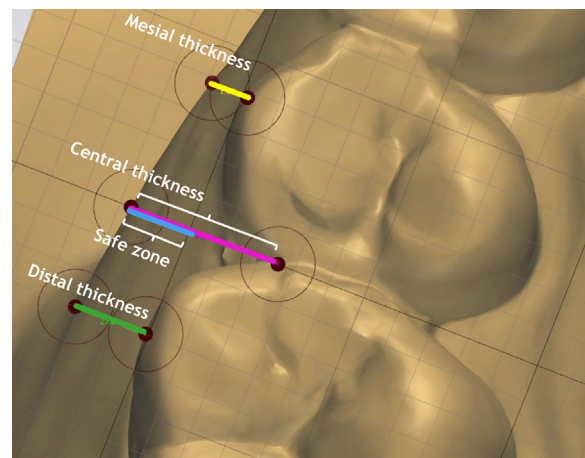
**Fig 3.** **A**, Determination of vertical reference lines on CBCT images for buccal alveolar bone thickness measurements in CBCT. **B**, Diagram of measurements on CBCT. A line was drawn from the most convex point of the lamina dura of tooth adjacent mesially to TSAD to that of root adjacent distally to TSAD. This line was bisected perpendicularly by line CD. Two others lines AB and EF parallel to line CD, were drawn perpendicularly at the most convex point of the lamina dura of tooth adjacent mesially to vertical TSAD and that of root adjacent distally to TSAD, respectively. The following 3 linear measurements were measured at each level of 2 mm, 4 mm, and 6 mm apical to the alveolar crest: the mesial thickness, central thickness, and distal thickness. Their corresponding cortical bone thickness was noted.



**Fig 4.** Illustration of “danger zone” in axial view: **A**, Contact point; **B**, “Danger zone” (from the contact point to the line that connected the most convex points of the lamina dura of the 2 roots) at the level of 4 mm apical to the alveolar crest; **C**, Superimposition of **A** and **B**.



**Fig 5.** The most convex point of the clinical crown of 2 teeth around vertical TSADs, its contact point, and the corresponding WALA ridge were identified.



**Fig 6.** Diagram of measurements on a digital model. The following 3 linear measurements were made directly on each 3D dental model: the mesial thickness, central thickness, and distal thickness.

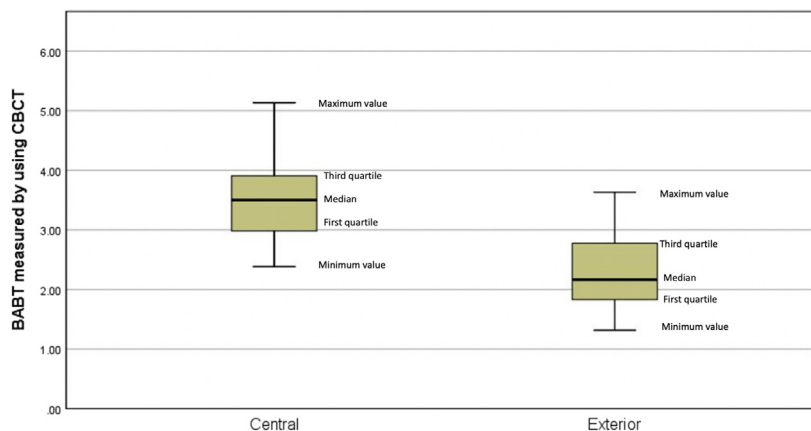


Fig 7. BABT at central and exterior areas, as measured by using CBCT (mm).

Table II. BABT at the investigated areas was measured by using CBCT

Area	2 mm		4 mm		6 mm		Average	
	Mean	SD	Mean	SD	Mean	SD	Mean	SD
<b>Mesial<sub>CBCT</sub></b>								
PM2-M1	1.59	0.33	1.97	0.44	2.15	0.67	1.90	0.37
M1-M2	2.07	0.73	2.42	0.72	2.42	0.98	2.30	0.76
Average	1.90 <sup>a</sup>	0.65	2.26 <sup>b</sup>	0.66	2.32 <sup>c</sup>	0.88	2.16	0.67
<b>Distal<sub>CBCT</sub></b>								
PM2-M1	1.68	0.34	2.08	0.80	2.44	0.74	2.07	0.53
M1-M2	2.12	0.60	2.70	0.78	2.95	0.79	2.59	0.66
Average	1.97 <sup>d</sup>	0.56	2.48 <sup>e</sup>	0.83	2.77 <sup>f</sup>	0.80	2.40	0.66
<b>Central<sub>CBCT</sub></b>								
PM2-M1	2.66	0.62	3.27	0.81	3.54	1.02	3.16	0.76
M1-M2	3.21	0.68	3.69	0.67	3.90	0.67	3.60	0.61
Average	3.01 <sup>g</sup>	0.70	3.54 <sup>h</sup>	0.74	3.77 <sup>i</sup>	0.81	3.44	0.69

PM2, Second premolar; M1, first molar; M2, second molar; SD, standard deviation  
 Note. Post-hoc Turkey test. Different letters indicate statistically significant differences at  $P < 0.05$ : d < e,f; g < h,i; e > d; h > g; f > d; and i > g.

The mean thickness of the safe zone was  $3.13 \pm 0.86$  mm (Table V).

A strong and significant correlation was found among central<sub>Model</sub>, safe<sub>Model</sub>, and central<sub>CBCT</sub> (Table VI). Thus, the BART measured using the digital model is considered to predict the actual available BABT for vertical TSAD placement. Using simple linear regression analysis, the following equation was developed:  $central_{CBCT} = 0.57 \times central_{Model} - 0.15$  (Table VII; Fig 9).

**DISCUSSION**

When the vertical installation of TSADs is planned, confirmation of BABT is important to ensure the stability of TSADs to avoid root damage during installation or

Table III. Buccal cortical bone thickness at investigated areas

Area	2 mm		4 mm		6 mm		Average	
	Mean	SD	Mean	SD	Mean	SD	Mean	SD
<b>Mesial<sub>CBCT</sub></b>								
PM2-M1	1.18	0.16	1.17	0.16	1.20	0.30	1.19	0.13
M1-M2	1.24	0.22	1.21	0.14	1.15	0.11	1.20	0.12
Average	1.22	0.20	1.20	0.15	1.17	0.20	1.20	0.12
<b>Distal<sub>CBCT</sub></b>								
PM2-M1	1.22	0.27	1.23	0.25	1.11	0.11	1.19	0.19
M1-M2	1.22	0.18	1.30	0.21	1.18	0.18	1.23	0.15
Average	1.22	0.21	1.28	0.22	1.16	0.16	1.22	0.17
<b>Central<sub>CBCT</sub></b>								
PM2-M1	1.18	0.13	1.22	0.21	1.22	0.22	1.20	0.15
M1-M2	1.23	0.16	1.22	0.20	1.25	0.15	1.23	0.12
Average	1.21	0.15	1.22	0.20	1.24	0.18	1.22	0.13

PM2, Second premolar; M1, first molar; M2, second molar; SD, standard deviation.  
 Note. Post-hoc Turkey test ( $P < 0.05$ ).

during reinstallation when there has been tooth movement. This is the first study to quantify BABT in the maxillary molar region to provide practical guidelines regarding vertical TSAD placement.

In this study, vertical TSADs were placed in the following interradicular areas: 11 TSADs between the maxillary second premolar and the first molar, and 20 TSADs were placed between the first and second molars, on the basis of the individual situation (Table I). The BABT in the investigated area ranged from 1.27 to 5.13 mm on CBCT, and BART ranged from 0.45 to 8.44 mm in digital models.

In CBCT and digital model measurements, the mean BABT and BART at the central position (central<sub>CBCT</sub>, 3.44 mm; central<sub>Model</sub>, 6.28 mm) tended to be thicker than those of the 2 exterior areas (mesial<sub>CBCT</sub>, 2.16;

**Table IV.** The thickness of the danger zone at the investigated areas

Danger zone thickness	Mean	Standard deviation	95% Confidence interval		Minimum	Maximum
			Lower bound	Upper bound		
2 mm	2.34 <sup>a</sup>	0.61	2.21	2.64	1.10	3.80
4 mm	2.08 <sup>b</sup>	0.64	1.96	2.40	0.90	3.65
6 mm	1.77 <sup>c</sup>	0.77	1.65	2.17	0.60	3.25
Average	2.07	0.65	2.04	2.31	0.87	3.57

Note. Post-hoc Turkey test. Different letters indicate statistically significant differences at  $P < 0.05$ : a > c.

**Table V.** BART at the investigated areas measured using digital models

Area	Mean ± SD	Minimum	Maximum
<b>Mesial<sub>Model</sub></b>			
PM2-M1	2.55 ± 1.03	1.16	3.83
M1-M2	2.84 ± 0.93	0.45	4.92
Average	2.74 ± 0.96	0.45	4.92
<b>Distal<sub>Model</sub></b>			
PM2-M1	2.99 ± 1.17	1.38	4.93
M1-M2	2.99 ± 0.92	1.14	4.81
Average	2.99 ± 0.99	1.14	4.93
<b>Central<sub>Model</sub></b>			
PM2-M1	5.81 ± 1.24	4.31	8.02
M1-M2	6.54 ± 0.97	4.25	8.44
Average	6.28 ± 1.11	4.25	8.44
<b>Safe<sub>Model</sub></b>			
PM2-M1	3.09 ± 0.99	1.86	4.48
M1-M2	3.16 ± 0.81	1.27	4.63
Average	3.13 ± 0.86	1.27	4.63

PM2, Second premolar; M1, first molar; M2, second molar; SD, standard deviation.

mesial<sub>Model</sub>, 2.74 mm; distal<sub>CBCT</sub>, 2.40 mm; distal<sub>Model</sub>, 2.99 mm). Therefore, we suggest that vertical TSADs be inserted centrally in the interradiar area. The smallest distance of BABT and BART at the central position was observed in the area between the maxillary second premolar and the first molar (2.38 mm in CBCT; 4.25 mm in the digital model), and the largest was in the area between the first molar and the second molar (5.13 mm in CBCT; 8.44 mm in the digital model).

In the 3 different bone thicknesses, the BABT was smallest at 2 mm from the alveolar crest. There was no significant difference between 4 mm and 6 mm. Lee et al<sup>10</sup> reported that in the maxilla, the greatest safety depth was found between the first and second molars. The safety depth significantly increased at 4 mm, 6 mm, and 8 mm compared with the 2-mm level at the cemento-enamel junction. Schnelle et al<sup>23</sup> reported that adequate bone for TSAD placement was located more

**Table VI.** The correlation between the measurements of BABT at the central position measured using CBCT and the digital model

Area	Central <sub>CBCT</sub>
<b>Central<sub>Model</sub></b>	
Pearson correlation	0.920
P value	<0.0001*
<b>Safe<sub>Model</sub></b>	
Pearson correlation	0.715
P value	<0.0001*

Note. Pearson correlation analysis was used for assessment. \* $P < 0.05$ .

**Table VII.** Linear regression analysis of Central<sub>Model</sub> and Central<sub>CBCT</sub>

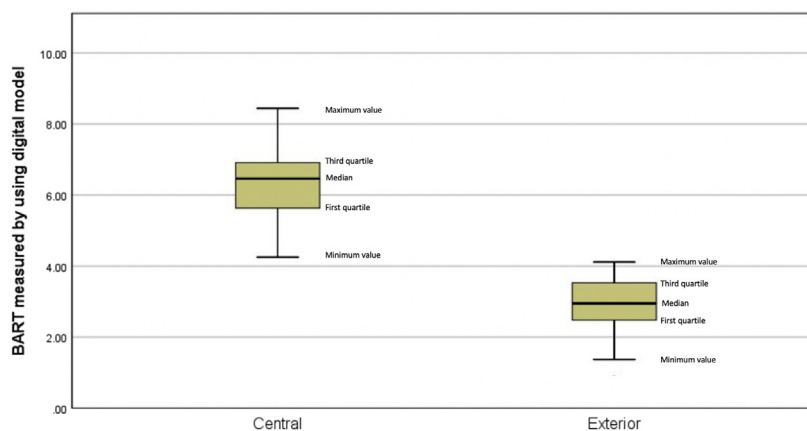
Independent variable	Unstandardized coefficients		Adjusted $r^2$	95% confidence interval for B		P value
	B	Standard error		Lower bound	Upper bound	
(Constant)	-0.154	0.290	0.840	-0.747	0.438	0.598
Central <sub>Model</sub>	0.573	0.045		0.480	0.666	0.000*

Note. Adjusted coefficient of determination used for assessment. \* $P < 0.05$ .

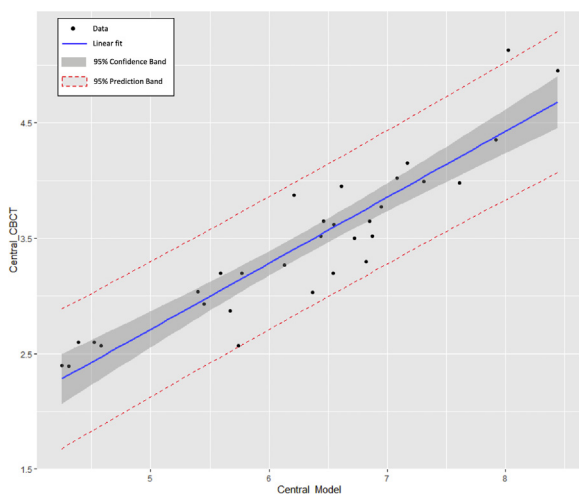
than halfway down the root length. In this study, at 4 mm and 6 mm from the alveolar bone crest, BABT was sufficient for vertical TSAD placement. These correspond to the attached gingival zone in most patients, which is advantageous for TSAD stability.

The measurements between the CBCT and digital models were different, but they had the same tendencies. This could be explained by the soft tissue thickness, which was included in the digital model measurements. Cha et al<sup>24</sup> used an ultrasonic device to evaluate the soft tissue thickness in buccal-attached gingiva, a potential TSAD installation area. They reported that in the maxillary arch, buccal-attached gingiva was  $1.23 \pm 0.32$  mm in between the second premolar and the first molar and  $1.11 \pm 0.21$  mm in between the first and the second molar in men, and it was  $1.09 \pm 0.20$  mm and  $1.05 \pm 0.15$  mm, respectively, in women. Moreover, the digital model measurements were calculated from a contact point of 2 teeth to a reference line in the digital model, whereas the measurement in CBCT was calculated from the most convex point of the lamina dura of the roots to the alveolar bone border.

The distance of the danger zone was  $2.07 \pm 0.65$  mm, and it tended to decrease from the alveolar crest to the apex significantly (Table IV). To prevent root damage during TSAD placement and teeth distalization, the TSAD should be placed outside of this zone.



**Fig 8.** The BART at the central and exterior areas, as measured by using digital models (mm).



**Fig 9.** A Plot of linear regression of Central<sub>Model</sub> and Central<sub>CBCT</sub>.

To achieve proper primary stability and clinical performance, and dependent on the insertion site of vertical TSADs, clinicians should choose an optimum combination of TSADs. Primary stability is the key to the overall success of TSADs and is influenced by 3 factors: bone quality (host factor), implant design (material factor), and placement technique (operator factor).<sup>25</sup> For bone quality, cortical bone thickness is the key determinant for initial stability.<sup>26,27</sup> It is believed that, for sufficient primary stability, the buccal cortical bone  $\geq 1$  mm is necessary.<sup>28</sup> In this study, buccal cortical bone thickness ranged from 1.06 to 1.73, and no area was  $< 1$  mm (Table III). These results are in agreement with previous reports.<sup>29,30</sup> Regarding the design of the TSADs, the important characteristics are diameter, length,

thread pitch width, thread design, thread sharpness, and surface characteristics. The greater diameter and length of TSADs, the greater initial stability and anchorage force resistance.<sup>31</sup> Poggio et al<sup>29</sup> also emphasized the importance of interradicular space measurements in the safe zone considering the microimplant diameter and bone clearance to protect periodontal health and ensure implant stability. According to their study,  $\geq 1$  mm of clearance of alveolar bone around a TSAD could be sufficient for periodontal safety. For conventional TSAD insertion, because the depth of bone penetration might vary 5-7 mm, the maxillary buccal intermolar region is an adequate site for TSADs that are 5-7 mm in length. Longer TSADs can be placed when they are adequately angulated.<sup>29</sup> In this study, longer TSADs were placed vertically and apically and were parallel to the molar axis. We recommend that TSADs with a minimum length of 10 mm be used to ensure primary stability and expose an adequate TSAD head above the gingival surface. There might be some concerns about gingival recession after the vertical installation of the TSADs. Although the head of vertical TSADs may be positioned close to the cervical line of the clinical crown, the insertion point was placed approximately 5.0 mm below the gingival crevice. Therefore, there is a very low possibility that gingival recession related to vertical TSADs will occur. We found no noticeable gingival recessions in this sample. To maintain periodontal health and achieve successful orthodontic treatment, minute details should be carefully monitored and treated if necessary.

CBCT can be used for the precise determination of available BART. However, not every patient should be assessed via computed tomography images for TSAD placement because of radiation exposure and



expenditure concerns. A study model could also reflect the basal bone of patients.<sup>21</sup> There was a strong correlation between the measurements from the CBCT and the digital models. The BART measured by using the digital model showed a significant relation with the actual available BABT for vertical TSAD placement (adjusted  $r^2 = 0.84$ ,  $F_{(1,29)} = 159.57$ ,  $P < 0.0001$ ; Table VII; Fig 9). Thus, the BART measured using the digital model can predict the actual available BABT for vertical TSAD placement. The regression equation is  $\text{central}_{\text{CBCT}} = 0.57 \times \text{central}_{\text{Model}} - 0.15$ .

The minimum BABT and BART in the central position in which vertical TSADs were placed successfully were 2.38 mm in CBCT and 4.25 mm in the digital model, respectively. This is a good point for a trained orthodontist who has multiple experiences with the angle adjustment technique.

Compared with conventional TSAD insertion methods, vertical TSADs can only be done with adequate alveolar bone thickness and trained orthodontists; however, it is a safer technique. Even in patients with thin alveolar bone thickness, vertical TSAD would not damage the root, with only TSAD failing if not achieving the stability of TSAD. Conceptually, this technique could minimize the contact between the TSAD and the root by increasing the space between them, both during insertion and distalization. The installation angle is inclined to an upright position and is parallel to the long axis of the proximal teeth. Because the depth of the TSADs is determined by the angle of the insertion and is dependent on the practitioner's technical experience, a larger alveolar bone thickness may be required for an inexperienced practitioner. To increase the success rate, a vertical TSAD should only be applied in selective patients with adequate buccal alveolar bone thickness. For the precise evaluation of available alveolar bone thickness, CBCT assessment is recommended.

This study has a limitation in considering the voxel size of 0.3 mm (approximately 0.7 mm spatial resolution in this study). There is a possibility of measurement error when assessing buccal bone thickness if its value is smaller than the spatial resolution.<sup>32</sup> The trabecular bone, which is difficult to measure, might be thinner than the spatial resolution. However, there seems to be no problem if the distance between the cortical bone and root is measured. There have been many previous studies using CBCT with similar voxel sizes to measure the alveolar bone width.<sup>33</sup> Although all the measurements with CBCT of this study with only one exception were larger than 0.7 mm, better spatial resolution is recommended in the future study.

## CONCLUSIONS

1. The recommended sites for vertical placement of TSADs in the maxillary molar area region are as follows: (1) the central area of the interradicular space, (2) a position more apical to the alveolar crest, and (3) an area avoiding the danger zone, which is within 2.07 mm from the contact point of crowns.
2. The BABT and BART at the central position for placing vertical TSADs in this study were  $3.44 \pm 0.69$  mm in CBCT and  $6.28 \pm 1.11$  mm in the digital model, respectively. The minimum BABT and BART at the central position in which vertical TSADs were placed successfully were 2.38 mm in CBCT and 4.25 mm in the digital model.
3. The actual available BABT at the central position for vertical TSAD placement could be predicted with the digital study model using the following regression equation:  $\text{entral}_{\text{CBCT}} = 0.57 \times \text{entral}_{\text{Model}} - 0.15$ .

## AUTHOR CREDIT STATEMENT

Hai Van Giap contributed to data curation, formal analysis, and original draft preparation; Ju Young Lee contributed to resources, supervision, conceptualization, and methodology; Hieu Nguyen contributed to investigation and data curation; Hwa Sung Chae contributed to supervision and conceptualization; Young Ho Kim contributed to supervision and conceptualization; and Jeong Won Shin contributed to supervision, conceptualization, methodology, and manuscript review and editing.

## REFERENCES

1. Kim SJ, Choi TH, Baik HS, Park YC, Lee KJ. Mandibular posterior anatomic limit for molar distalization. *Am J Orthod Dentofacial Orthop* 2014;146:190-7.
2. Choi YJ, Lee JS, Cha JY, Park YC. Total distalization of the maxillary arch in a patient with skeletal Class II malocclusion. *Am J Orthod Dentofacial Orthop* 2011;139:823-33.
3. Yang L, Li F, Cao M, Chen H, Wang X, Chen X, et al. Quantitative evaluation of maxillary interradicular bone with cone-beam computed tomography for bicortical placement of orthodontic mini-implants. *Am J Orthod Dentofacial Orthop* 2015;147:725-37.
4. Wilmes B, Vasudavan S, Drescher D. Maxillary molar mesialization with the use of palatal mini-implants for direct anchorage in an adolescent patient. *Am J Orthod Dentofacial Orthop* 2019;155:725-32.
5. Ishida T, Yoon HS, Ono T. Asymmetrical distalization of maxillary molars with zygomatic anchorage, improved superelastic nickel-titanium alloy wires, and open-coil springs. *Am J Orthod Dentofacial Orthop* 2013;144:583-93.
6. Han SH, Park JH, Jung CY, Kook YA, Hong M. Full-step Class II correction using a modified C-palatal plate for total arch distalization in an adolescent. *J Clin Pediatr Dent* 2018;42:307-13.

7. Hourfar J, Bister D, Lux CJ, Al-Tamimi B, Ludwig B. Anatomic landmarks and availability of bone for placement of orthodontic mini-implants for normal and short maxillary body lengths. *Am J Orthod Dentofacial Orthop* 2017;151:878-86.
8. Tai K, Park JH, Tatamiya M, Kojima Y. Distal movement of the mandibular dentition with temporary skeletal anchorage devices to correct a Class III malocclusion. *Am J Orthod Dentofacial Orthop* 2013;144:715-25.
9. Yamada K, Kuroda S, Deguchi T, Takano-Yamamoto T, Yamashiro T. Distal movement of maxillary molars using miniscrew anchorage in the buccal interradicular region. *Angle Orthod* 2009;79:78-84.
10. Lee KJ, Joo E, Kim KD, Lee JS, Park YC, Yu HS. Computed tomographic analysis of tooth-bearing alveolar bone for orthodontic miniscrew placement. *Am J Orthod Dentofacial Orthop* 2009;135:486-94.
11. Ozdemir F, Tozlu M, Germec-Cakan D. Cortical bone thickness of the alveolar process measured with cone-beam computed tomography in patients with different facial types. *Am J Orthod Dentofacial Orthop* 2013;143:190-6.
12. De Vos W, Casselman J, Swennen GR. Cone-beam computerized tomography (CBCT) imaging of the oral and maxillofacial region: a systematic review of the literature. *Int J Oral Maxillofac Surg* 2009;38:609-25.
13. Noar JH, Pabari S. Cone beam computed tomography—current understanding and evidence for its orthodontic applications? *J Orthod* 2013;40:5-13.
14. Kongprasert T, Winaikosol K, Pisek A, Manosudprasit A, Manosudprasit A, Wangsrimongkol B, et al. Evaluation of the effects of cheiloplasty on maxillary arch in uclp infants using three-dimensional digital models. *Cleft Palate Craniofac J* 2019;56:1013-9.
15. Duarte MEA, Gribel BF, Spitz A, Artese F, Miguel JAM. Reproducibility of digital indirect bonding technique using three-dimensional (3D) models and 3D-printed transfer trays. *Angle Orthod* 2020;90:92-9.
16. Ho CT, Lin HH, Lo LJ. Intraoral scanning and setting up the digital final occlusion in three-dimensional planning of orthognathic surgery: its comparison with the dental model approach. *Plast Reconstr Surg* 2019;143:1027e-36e.
17. Yılmaz RBN, Çakan DG, Altay M, Canter HI. Reliability of measurements on plaster and digital models of patients with a cleft lip and palate. *Turk J Orthod* 2019;32:65-71.
18. Henninger E, Vasilakos G, Halazonetis D, Gkantidis N. The effect of regular dental cast artifacts on the 3D superimposition of serial digital maxillary dental models. *Sci Rep* 2019;9:10501.
19. Verma RK, Singh SP, Verma S, Kumar V, Bhupali NR, Arora S. Comparison of reliability, validity, and accuracy of linear measurements made on pre- and posttreatment digital study models with conventional plaster study models. *J Orthod Sci* 2019;8:18.
20. Rosti F, Sfondrini MF, Bressani D, Vitale MC, Gandini P, Scribante A. Digital workflow for indirect bonding with 2D lingual brackets: a case report and procedure description. *Case Rep Dent* 2019;2019:6936049.
21. Holmes PB, Wolf BJ, Zhou J. A CBCT atlas of buccal cortical bone thickness in interradicular spaces. *Angle Orthod* 2015;85:911-9.
22. Andrews LF. The six keys to normal occlusion. *Am J Orthod* 1972;62:296-309.
23. Schnelle MA, Beck FM, Jaynes RM, Huja SS. A radiographic evaluation of the availability of bone for placement of miniscrews. *Angle Orthod* 2004;74:832-7.
24. Cha BK, Lee YH, Lee NK, Choi DS, Baek SH. Soft tissue thickness for placement of an orthodontic miniscrew using an ultrasonic device. *Angle Orthod* 2008;78:403-8.
25. Park J, Cho HJ. Three-dimensional evaluation of interradicular spaces and cortical bone thickness for the placement and initial stability of microimplants in adults. *Am J Orthod Dentofacial Orthop* 2009;136:314.e1-12: discussion 314-5.
26. Wilmes B, Rademacher C, Olthoff G, Drescher D. Parameters affecting primary stability of orthodontic mini-implants. *J Orofac Orthop* 2006;67:162-74.
27. Miyamoto I, Tsuboi Y, Wada E, Suwa H, Iizuka T. Influence of cortical bone thickness and implant length on implant stability at the time of surgery—clinical, prospective, biomechanical, and imaging study. *Bone* 2005;37:776-80.
28. Motoyoshi M, Inaba M, Ono A, Ueno S, Shimizu N. The effect of cortical bone thickness on the stability of orthodontic mini-implants and on the stress distribution in surrounding bone. *Int J Oral Maxillofac Surg* 2009;38:13-8.
29. Poggio PM, Incorvati C, Velo S, Carano A. “Safe zones”: a guide for miniscrew positioning in the maxillary and mandibular arch. *Angle Orthod* 2006;76:191-7.
30. Farnsworth D, Rossouw PE, Ceen RF, Buschang PH. Cortical bone thickness at common miniscrew implant placement sites. *Am J Orthod Dentofacial Orthop* 2011;139:495-503.
31. Tatli U, Alraawi M, Toroğlu MS. Effects of size and insertion angle of orthodontic mini-implants on skeletal anchorage. *Am J Orthod Dentofacial Orthop* 2019;156:220-8.
32. Ballrick JW, Palomo JM, Ruch E, Amberman BD, Hans MG. Image distortion and spatial resolution of a commercially available cone-beam computed tomography machine. *Am J Orthod Dentofacial Orthop* 2008;134:573-82.
33. Spin-Neto R, Gotfredsen E, Wenzel A. Impact of voxel size variation on CBCT-based diagnostic outcome in dentistry: a systematic review. *J Digit Imaging* 2013;26:813-20.