

## Bronchiolitis Obliterans Organizing Pneumonia: Clinicopathologic Review of a Series of 45 Korean Patients Including Rapidly Progressive form

Bronchiolitis obliterans organizing pneumonia (BOOP) is a clinicopathological syndrome associated with a variety of disease entities. The aim of this study was to review cases with initial diagnosis of BOOP applying uniform histopathologic criteria, and analyze the clinical characteristics of proven cases of BOOP including rapidly progressive form. A total of 81 cases, initially diagnosed as BOOP and with available tissue sections, was collected. Thirty six cases (44.4%) were excluded from the study, more than two thirds of which were given a revised diagnosis of interstitial pneumonitis/fibrosis other than BOOP. Thirty one patients were classified as idiopathic BOOP, 8 patients as secondary BOOP, and 6 patients as rapidly progressive BOOP. Open lung biopsy specimen from all six cases with lethal outcome showed more severe interstitial inflammation and septal fibrosis and/or alveolar exudate with a varying degree than those with good prognosis. There was no difference by the sexes. The two most frequent presenting symptoms were cough and dyspnea. Bilateral multifocal consolidation was a common radiological finding. More than 70% cases of idiopathic BOOP experienced clinical improvements. The diagnosis of BOOP is usually suggested by clinicoradiologic findings, but needs to be confirmed histopathologically, preferably through surgical open or video-assisted thoracoscopic biopsy.

Key Words : *Bronchiolitis Obliterans Organizing Pneumonia; Retrospective Studies; Pathology*

Joon Chang, Joung-ho Han<sup>1</sup>,  
Dong Won Kim<sup>2</sup>, In-chul Lee<sup>3</sup>,  
Kyo Young Lee<sup>4</sup>, Soonhee Jung<sup>5</sup>,  
Hye Seung Han<sup>6</sup>, Bong Kwon Chun<sup>7</sup>,  
Seong Jin Cho<sup>8</sup>, Kibeom Lee<sup>9</sup>,  
Beom Jin Lim<sup>10</sup>, Dong Hwan Shin<sup>10</sup>

Departments of Internal Medicine and Pathology<sup>10</sup>,  
Yonsei University, Seoul; Departments of Pathology,  
Samsung Medical Center<sup>1</sup>, Sungkyunkwan University  
College of Medicine, Seoul; Soonchunhyang  
University<sup>2</sup>, Seoul; Asan Medical Center<sup>3</sup>, University  
of Ulsan College of Medicine, Seoul; Catholic  
University of Korea<sup>4</sup>, Seoul; Wonju Medical College<sup>5</sup>,  
Yonsei University, Wonju; Inha University<sup>6</sup>, Incheon;  
Kosin University<sup>7</sup>, Busan; Korea University<sup>8</sup>, Seoul;  
Ajou University<sup>9</sup>, Suwon, Korea

Received : 12 December 2001  
Accepted : 14 January 2002

### Address for correspondence

Dong Hwan Shin, M.D.  
Department of Pathology, Yonsei University  
College of Medicine, 134 Shinchon, Seodaemun,  
C.P.O. Box 8044, Seoul 120-752, Korea  
Tel : +82-2-361-5261, Fax : +82-2-362-0860  
E-mail : shindh417@yumc.yonsei.ac.kr

## INTRODUCTION

Bronchiolitis obliterans organizing pneumonia (BOOP) is a clinicopathologic syndrome first described in 1985 and has become increasingly recognized in association with a variety of causes or conditions (1-9). It is histologically defined by the presence of buds of granulation tissue consisting of fibroblasts and collagen within the lumen of the distal airspaces. BOOP may be idiopathic or secondary being associated with various underlying conditions and most of cases of BOOP reported in larger studies were idiopathic (also called cryptogenic organizing pneumonia [COP]) (5, 6, 9). The disease is usually manifested as a distinct clinicopathological syndrome of subacute pneumonia, with typical alveolar patchy and often migratory pulmonary opacities on imaging. Other imaging presentations consist of diffuse infiltrative opacities or focal pneumonia (3, 10, 11). The clinical response to corticosteroids is usually dramatic, but relapses are common during tapering after the discontinuation of the treatment (1-

9). There have been several case reports of BOOP with unfavorable, even lethal outcome (12, 13) and recent collective follow-up studies of similar cases described patients with unfavorable outcome or rapidly progressive respiratory failure that has been obviously attributed to BOOP (14, 15). However rapidly progressive BOOP cases have not been reported in Korea.

BOOP should not be considered as a specific histopathologic feature, since the disease has been reported in a wide variety of conditions, such as infection, connective-tissue diseases, vasculitides, hypersensitivity pneumonitis (HP), and chronic eosinophilic pneumonia (CEP) and can occur as a secondary inflammatory process in idiopathic interstitial pneumonia and organizing diffuse alveolar damage (DAD), and is also commonly noted as a process secondary to localized lesions (16, 17). Thus, before considering BOOP as the primary cause of respiratory disease in a patient, possible underlying disease entities should be carefully ruled out by both clinicians and pathologists (1, 2, 18, 19).

We reviewed cases with initial diagnosis of BOOP applying uniform histopathologic criteria, and then analyzed the clinical characteristics of proven cases of BOOP, including rapidly progressive form.

## MATERIALS AND METHODS

A total of 81 patients, initially diagnosed as BOOP and with available tissue sections, were accrued from 19 major general hospitals (including 17 university hospitals) in Korea. In six cases, the submitted lung tissue was inadequate for proper examination. The hematoxylin-eosin stained sections in all cases were initially examined for the presence of intraluminal organization both in the alveolar ducts or alveoli (organizing pneumonia) and bronchiolar lumina (bronchiolitis obliterans) by one of the authors (DHS) in a blinded fashion and then the other pathologist (JH) independently reviewed cases selected for consensus opinion based on the generally accepted histologic features (16). Discrepancies were resolved by re-review and mutual agreement. Some of cases submitted had been discussed in the monthly meeting of Korean Study Group of Cardiovascular and Pulmonary Pathology. In some cases, slides with complementary stains (Verhoeff, trichrome, PAS, acid fast, and methenamine silver) were also reviewed. The biopsy specimens were obtained by various methods, such as open lung/or thoracoscopic biopsy (n=39), fiberoptic transbronchial lung biopsy (n=5), and core needle biopsy (n=1) (Table 1).

Given the fact that the presence of necrosis, acute inflammation, microabscess formation, and vasculitis serves as strong evidence against the diagnosis of BOOP (16), pathologic diag-

**Table 1.** Method of lung biopsy and patient characteristics

	Idiopathic (n=31)	Secondary (n=8)	Rapidly progressive (n=6)
Method of lung biopsy			
Open lung or thoracoscopic	28	5	6
Fiberoptic transbronchial	2	3	0
Core needle	1	0	0
Age (mean $\pm$ S.D., years)	50.6 $\pm$ 11.4	33.8 $\pm$ 17.3	50.5 $\pm$ 16.5
Sex (male:female)	19:12	5:3	4:2
Current or former smoker	11/24 (46%)	2/6 (33.3%)	2/4 (50%)
Cough	25 (80.7%)	3 (37.5%)	1 (16.7%)
Dyspnea	20 (64.5%)	3 (37.5%)	6 (100.0%)
Sputum	15 (48.4%)	3 (37.5%)	0
Hemoptysis	1 (3.2%)	0	0
Pleuritic chest pain	5 (16.1%)	2 (25.0%)	0
Weight loss (>2 kg)	3 (9.7%)	1 (12.5%)	2 (33.3%)
Fever	6 (19.4%)	2 (25.0%)	2 (33.3%)
Night sweat	3 (9.7%)	0	0
Flu-like illness	5 (16.1%)	1 (12.5%)	0
Tachypnea	3 (9.7%)	2 (25.0%)	1 (16.7%)
Fine crackles	17 (54.8%)	3 (37.5%)	5 (83.3%)
Cyanosis	0	0	1 (16.7%)

noses of interstitial pneumonia/fibrosis other than BOOP were made in 16 cases and infectious bronchiolitis/pneumonia in 4 cases. There were no bronchiolitis obliterans, however microgranulomas in three cases suggested hypersensitivity reaction or infection. Patchy organizing pneumonia suggesting post-aspiration reaction or an association with space-occupying lesion was recognized in seven cases. Thus 45 cases were finally confirmed as histopathologically proven BOOP (Table 2).

Clinical data were collected retrospectively from the clinical records with a standardized data sheet and were reviewed by a single investigator (JC), who was unaware of pathologic information. All patients enrolled in the study were required to meet the following criteria: 1) radiologic lung infiltrates; 2) lung biopsy compatible with BOOP.

## RESULTS

### Pathologic review and patients characteristics

At low magnification, the most distinguishing histologic features were the patchy nature of the lesion consisting of small buds of fibromyxoid tissue in the small bronchiole, alveolar ducts, and alveoli (Fig. 1). The connective tissue buds were more conspicuous in alveoli than in bronchiolar lumina and extended from one alveolus to another. The buds contained loosely woven fibers of collagen and reticulin, which were highlighted by van Gieson's and Masson's trichrome stains. The extent of involvement of various small conducting airways differed from case to case. Terminal bronchioles

**Table 2.** Pathologic and clinical review of 81 cases submitted as bronchiolitis obliterans organizing pneumonia

	Number of cases
Bronchiolitis obliterans organizing pneumonia (BOOP)	45
Idiopathic BOOP (not rapidly progressive)	31
Secondary BOOP (with known cause or in the context of disease)	8
Bone marrow transplantation	2
Thoracic radiotherapy and chemotherapy	2
Systemic lupus erythematosus	1
Behçet's disease	1
Amiodarone	1
Mycoplasmal infection	1
Rapidly progressive BOOP	6
Idiopathic	4
Systemic lupus erythematosus	1
Rheumatoid arthritis	1
Excluded from BOOP:	36
Inadequate specimen	6
Interstitial pneumonia/fibrosis other than BOOP	16
Infective bronchiolitis/pneumonia	4
No bronchiolitis obliterans and microgranuloma	3
Patch organizing pneumonia suggesting post-aspiration reaction or association to the space-occupying lesion	7

commonly had a cellular infiltrate in the wall composed predominantly of mononuclear cells, sometimes with neutrophils in the lumen. In some cases, acute inflammatory cells and fibrinous exudate were also present in or near the buds, sug-

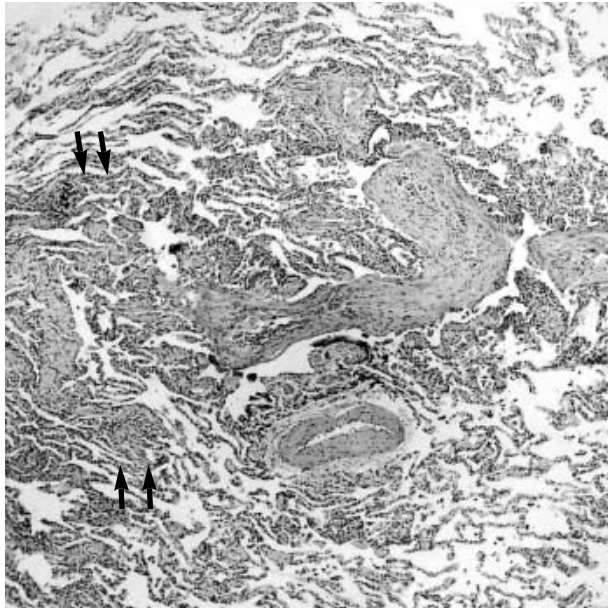


Fig. 1. Typical pathologic feature of BOOP. Section shows intra-luminal fibrous buds branching in respiratory bronchioles and alveolar ducts. Characteristic atelectatic change around patchy lesion is perceptible (arrows) and the surrounding lung architecture is well preserved. Central collection of mononuclear inflammatory cells is noted within buds (H&E,  $\times 40$ ).

gesting that the process was still active. The intraluminal buds frequently had central collection of inflammatory cells, including histiocytes, lymphocytes, and plasma cells, which tended to cluster at the center of the buds. Away from the involved lung tissue, the alveoli appeared normal or minimally affected, with slight thickening of septa with mild inflammatory infiltrate and slight predominance of type II cells. Microscopical obstructive pneumonia was noted in alveoli distal to plugged alveolar ducts as shown by intra-alveolar aggregates of foamy macrophages. Not a single case showed a honeycombing fibrosis.

Of the 45 patients, 8 were found to have a clearly defined etiology or condition, because they were associated with an identifiable cause (e.g. infection) or with a well-defined context (e.g. connective tissue disease, hematologic malignancies, drugs, or disorders previously reported to cause BOOP): 2 cases with acute leukemia treated with bone marrow transplantation and chemotherapy, 2 cases with thymic tumor treated with thoracic radiotherapy and chemotherapy, and one each with systemic lupus erythematosus (SLE), Behcet's disease, amiodarone medication, and *Mycoplasma pneumoniae* infection. These cases were classified as secondary BOOP.

We identified six patients with a clinical course compatible with rapidly progressive BOOP, because they presented with severe respiratory failure requiring mechanical ventilation or causing death despite aggressive supportive care. Two patients were associated with SLE and rheumatoid arthritis, respectively. In four patients the lung biopsy specimen showed alveolar septal inflammation and mild collagenous fibrosis as well as typical organizing pneumonia (Fig. 2). The rest re-

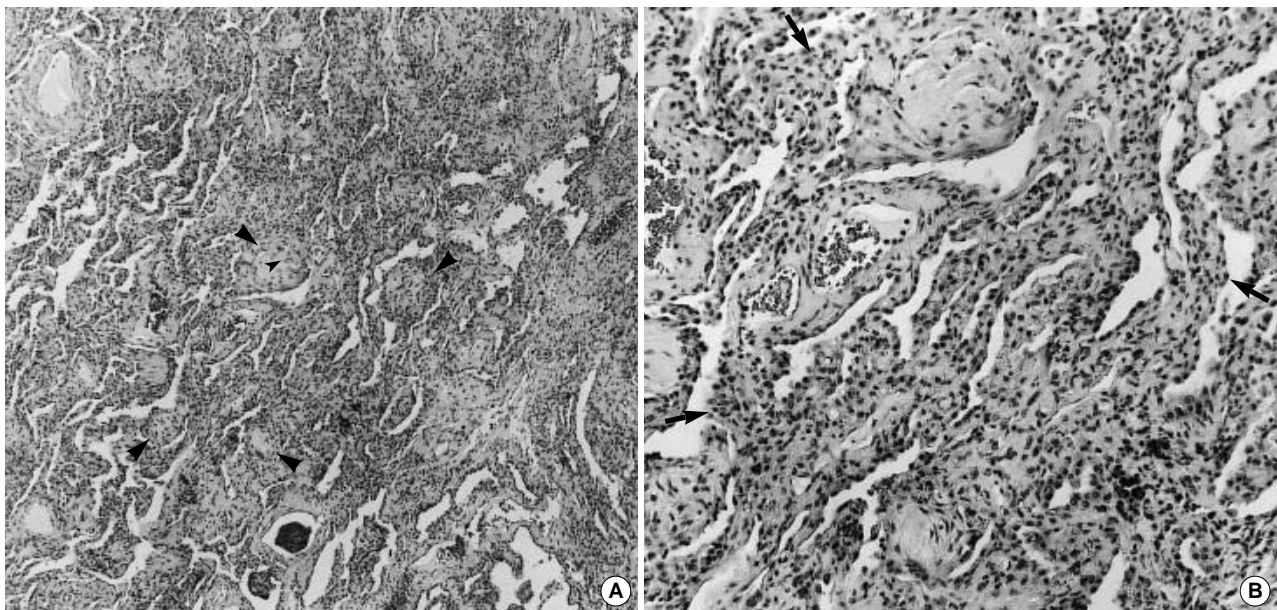


Fig. 2. Idiopathic BOOP with rapidly progressive course. (A) Intraalveolar fibrous buds (arrowheads) and interalveolar septa affected with inflammation and some collagenous fibrosis. (B) High magnification of intraalveolar buds of loose fibrous tissue and inflamed septa (arrows) with slight fibrosis (H&E, A:  $\times 100$ , B:  $\times 200$ ).

vealed more marked septal and intraalveolar cellularity and organizing fibrin with a BOOP pattern (Fig. 3). All six cases showed nodularity of lesion as usually present in typical BOOP but no histologic evidence of chronic interstitial inflammatory process in the portion of the lung without involvement. The remaining cases were classified as idiopathic BOOP not of rapidly progressive form (Table 2).

In the final analysis, 45 patients were identified as histopathologically confirmed BOOP: 31 cases as idiopathic, 8 cases as secondary, and 6 cases as rapidly progressive form. The mean age was  $50.6 \pm 11.4$  yr (mean  $\pm$  standard deviation) in idiopathic BOOP,  $33.8 \pm 17.3$  yr in secondary BOOP, and  $50.5 \pm 16.5$  yr in rapidly progressive BOOP. The male gender accounted for 19 of 31 cases (61.3%) in idiopathic BOOP, 5 of 8 (62.5%) in secondary BOOP, and 4 of 6 (66.7%) in rapidly progressive BOOP. Current or ex-smoker with identifiable history accounted for 11 of 24 cases (46%) in idiopathic BOOP, 2 of 6 (33.3%) in secondary BOOP, and 2 of 4 (50%) in rapidly progressive BOOP (Table 1).

### Clinical manifestations

The two most common presenting symptoms were cough and dyspnea. Cough was presented in 25 cases (80.7%) of idiopathic BOOP, 3 cases (37.5%) of secondary BOOP, and 1 case (16.7%) of rapidly progressive BOOP. Dyspnea was manifested in 20 cases (64.5%) of idiopathic BOOP, 3 cases (37.5%) of secondary BOOP, and all cases of rapidly progressive BOOP. Fever was present in 6 cases (19.4%) and flu-like illness in 5 cases (16.1%) in idiopathic BOOP. The most fre-

quent physical finding was crackles, noted in 17 cases (54.8%) of idiopathic BOOP, 3 cases (37.5%) of secondary BOOP, and 5 cases (83.3%) of rapidly progressive BOOP (Table 1).

The radiological findings were classified into 3 categories: bilateral multifocal alveolar consolidations, diffuse infiltrative lung diseases, and unifocal consolidation or mass-like lesion (3). In idiopathic BOOP (n=31), bilateral multifocal alveolar consolidations were observed in 14 cases (45.2%), diffuse infiltrative lung diseases in 10 cases (32.3%), and unifocal consolidation or mass-like lesion in 9 cases (29.0%). Diffuse infiltrative lung disease was observed in 57.1% of secondary BOOP, and in 40% of rapidly progressive BOOP (Table 3).

### Respiratory physiologic parameters

Arterial blood PaO<sub>2</sub> levels on room air breathing at the time of presentation were  $76.1 \pm 13.7$  mmHg (n=21) in idiopathic BOOP,  $74.5 \pm 17.4$  mmHg (n=6) in secondary BOOP, and  $60.9 \pm 10.9$  mmHg (n=4) in rapidly progressive BOOP. Arterial hypoxemia (PaO<sub>2</sub><80 mmHg) was recorded in 12

Table 3. Chest radiological findings

	Idiopathic (n=31)	Secondary (n=7)	Rapid (n=5)
Bilateral multifocal alveolar consolidations	14 (45.2%)	3 (42.9%)	2 (40%)
Diffuse infiltrative lung diseases	10 (32.3%)	4 (57.1%)	2 (40%)
Unifocal consolidation or mass-like lesion	9 (29.0%)	0	1 (20%)

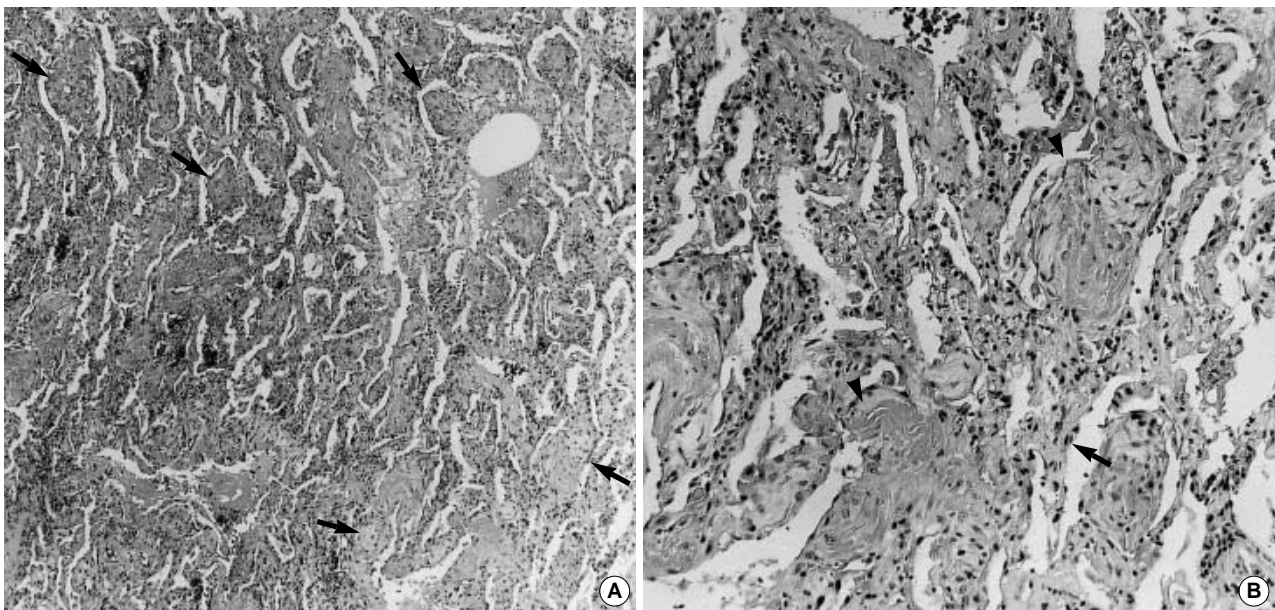


Fig. 3. Idiopathic BOOP with rapidly progressive course. (A) Intraalveolar buds of young fibromyxoid tissue (arrows) accompanied by septa showing increased cellularity and fibrosis. (B) High magnification of intraalveolar buds associated with increased exudate, organizing (arrowheads) and cellular septa (arrows) (H&E, A:  $\times 100$ , B:  $\times 200$ ).

of 21 cases (57.1%) in idiopathic BOOP, in 4 of 6 (66.7%) in secondary BOOP, and in 4 of 4 (100%) in rapidly progressive BOOP (Table 4).

Pulmonary spirometry revealed decreased forced vital capacity (FVC) and forced expiratory volume in 1 sec (FEV<sub>1</sub>). FVC was 71.1 ± 21.1% of predicted value (n= 23) in idiopathic BOOP, and 57.2 ± 26.0 % of predicted value (n=5) in secondary BOOP. FEV<sub>1</sub> was 72.5 ± 20.8% of predicted value (n=23) in idiopathic BOOP, and 62.4 ± 32.7% of predicted value (n=5) in secondary BOOP. Decreased FVC (<80% of predicted value) was observed in 14 of 23 cases (60.9%) in idiopathic BOOP, and in 4 of 5 (80.0%) in secondary BOOP. Decreased FEV<sub>1</sub> (<80% of predicted value) was observed in 13 of 23 cases (56.5%) in idiopathic BOOP, and in 4 of 5 (80.0%) in secondary BOOP. Obstructive pattern (FEV<sub>1</sub>/FVC <0.70) was present in 1 of 23 cases (4.3%) in idiopathic BOOP, and in 1 of 5 (20%) in secondary BOOP. Diffusing capacity of the lung (DL<sub>CO</sub>) was 67.2 ± 19.0% of predicted value (n=16) in idiopathic BOOP, and 47.2 ± 25.8% of predicted value (n=4) in secondary BOOP. Decreased DL<sub>CO</sub> (<80% of predicted value) was observed in 15 of 17 cases (88.2%) in idiopathic BOOP, and in 4 of 4 (100%) in secondary BOOP. Specific diffusing capacity, DL<sub>CO</sub>/V<sub>A</sub>, was lower than 80% of the predicted value in 4 of 15 cases (26.7%) in idiopathic BOOP, and in 1 of 3 (33.3%) in secondary BOOP (Table 4).

**Bronchoalveolar lavage**

Bronchoalveolar lavage (BAL) by bronchoscopy was per-

**Table 4.** Respiratory physiologic and laboratory parameters at diagnosis

	Idiopathic	Secondary	Rapid
PaO <sub>2</sub> (mmHg)	76.1 ± 13.7* (n=21)	74.5 ± 17.4 (n=6)	60.9 ± 10.9 (n=4)
PaO <sub>2</sub> <80 mmHg	12/21 (57.1%)	4/6 (66.7%)	4/4 (100%)
FVC	71.1 ± 21.1† (n=23)	57.2 ± 26.0 (n=5)	
FVC <80% of predicted	14/23 (60.9%)	4/5 (80.0%)	
FEV <sub>1</sub>	72.5 ± 20.8 (n=23)	62.4 ± 32.7 (n=5)	
FEV <sub>1</sub> <80% of predicted	13/23 (56.5%)	4/5 (80.0%)	
DL <sub>CO</sub>	67.2 ± 19.0 (n=16)	47.2 ± 25.8 (n=4)	
WBC >10,000/μL	10/30 (33.3%)	3/6 (50.0%)	1/5 (20.0%)
WBC <4,000/μL	2/30 (6.7%)	1/6 (16.7%)	0
ESR >60 mm/hr	1/11 (9.1%)	1/5 (20%)	1/4 (25%)
Positive antinuclear antibody	3/29 (10.3%)	1/8 (12.5%)	1/6 (16.7%)
Positive rheumatoid factor	1/29 (3.4%)	0/8 (0%)	1/6 (16.7%)

\*Values are expressed as mean ± standard deviation, †Values are expressed as percentage of predicted.

formed in 12 cases of idiopathic BOOP, and 2 of secondary BOOP. The differential counts of the BAL fluid were available in 11 idiopathic BOOP cases. An increase of lymphocytes (>25%) was observed in 7 cases (63.6%). An increase of neutrophils (>5%) and that of eosinophils (>2%) were observed in 6 cases (54.5%) and in 5 (45.5%), respectively. An increase of both lymphocytes and neutrophils was observed in 5 cases (45.5%), and that of both lymphocytes and eosinophils was observed in 4 (36.4%). An increase of lymphocytes, neutrophils, and eosinophils was observed in 3 cases (27.3%).

**Laboratory parameters**

Peripheral blood leukocytosis (WBC >10,000/μL) was manifested in 10 of 30 cases (33.3%) in idiopathic BOOP, in 3 of 6 (50.0%) in secondary BOOP, and in 1 of 5 (20.0%) in rapidly progressive BOOP. Decreased serum albumin level (<3.5 g/dL) was observed in 12 of 28 cases (42.9%) in idiopathic BOOP, in 2 of 5 (40%) in secondary BOOP, and in 3 of 4 (75%) in rapidly progressive BOOP. Serum antinuclear antibody test was positive in 3 of 29 cases (10.3%) in idiopathic BOOP, in 1 of 8 (12.5%) in secondary BOOP, and in 1 of 6 (16.7%) in rapidly progressive BOOP. Serum rheumatoid factor was present in 1 of 29 cases (3.4%) in idiopathic BOOP, and in 1 of 6 (16.7%) in rapidly progressive BOOP (Table 4).

**Treatment and clinical outcome**

Twenty patients with idiopathic BOOP received prednisolone and other corticosteroid treatment. Eighteen of them were evaluable for the outcome: 11 cases (61.1%) showed complete recovery of symptoms and radiological resolution, 5 cases (27.8%) showed partial recovery, and one each case (5.6%) showed no change and aggravation, respectively. Among 11 idiopathic BOOP patients without corticosteroid treatment, 6 cases showed complete recovery, 1 case showed partial recovery, and the remaining 4 patients were not assessable for the clinical outcome. Among 31 idiopathic BOOP patients, 23 (74.2%) improved: 17 (54.8%) recovered completely and 6 (19.4%) recovered partially (Table 5). There was no mortality.

**Table 5.** Treatment and clinical outcome

	Idiopathic		Secondary		Rapid	
	Corticosteroid	Corticosteroid	Corticosteroid	Corticosteroid	Corticosteroid	Corticosteroid
	Yes	No	Yes	No	Yes	No
Complete recovery	11	6	1	2	-	-
Partial recovery	5	1	1	-	-	-
No change	1	-	-	-	-	-
Aggravation	1	-	-	-	3	3
Unable to evaluate	2	4	2	2		
Total	20	11	4	4	3	3

Four out of eight patients with secondary BOOP received prednisolone (Table 5). One patient had died 12 months after the diagnosis due to the lung involvement of thymic carcinoma.

All six patients with rapidly progressive BOOP died within two months after the diagnosis. The mean duration of survival was  $4 \pm 2.5$  weeks ( $n=5$ ). Three patients were not treated by corticosteroid or antiinflammatory agents. Three patients received intravenous administration of methylprednisolone 1,000 mg/day or at larger doses, and two patients received intravenous administration of cyclophosphamide 1,000 mg/day in addition to the corticosteroid therapy (Table 5).

## DISCUSSION

For the clinical classification of BOOP, clinicians must have specific information regarding the patients' clinical setting or underlying illnesses. In this study we were able to obtain further clinical information by formulating standard data sheet with complete list of conditions and drugs previously reported to be the cause or to be associated with BOOP. As a result, 10 cases of BOOP (including 2 cases of rapidly progressive BOOP) were found to be associated with these conditions or drugs. Although some of them might have no direct relation between the occurrence of BOOP and the underlying conditions, it is very important to identify any possibly related clinical settings before making a diagnosis of idiopathic BOOP, because it has been known that the cases associated with another chronic disease process, especially collagen vascular diseases and autoimmune diseases, had poor outcome, compared with idiopathic cases despite identical histologic findings (1, 4, 6, 18).

The open lung biopsy has been preferred for a definitive diagnosis, but video-guided thoracoscopy can also provide sufficient tissue specimen to establish a diagnosis. In selected situations, a transbronchial biopsy examination may be useful if both bronchiolar and alveolar elements are present in the tissue specimen accompanied with typical clinical and radiological findings (16, 20).

There were limitations in the interpretation of our clinical data, because the cases were collected retrospectively from many hospitals. Even though we used a standardized data sheet, some data were missing. Protocols for clinical therapy and follow-up were not uniform. The incidence for each clinical finding was generally somewhat lower than those of the previous reports, most likely because of the retrospective nature of the present analysis and incomplete follow-up. Even with these limitations, this is the first study in Korea with critical review of biopsied lung tissues applying uniform criteria, and identification of cases of so-called rapidly progressive BOOP. We would like to recommend that a standardized data sheet be applied in future prospective study to avoid loss of important clinical history and findings.

In Korea there was one retrospective clinical study of BOOP in a smaller group of Korean patients comprised of 23 cases including 10 outside cases previously reported in Korean literatures (21). Eighteen of the 23 cases (78%) were classified as idiopathic BOOP and the other five were revealed to have associated connective tissue diseases. The authors observed female predominance with a male-to-female ratio of 1:2 in idiopathic BOOP, which had not been reported in other reports. They speculated that this difference might be explained in terms of either ethnic characteristics of Korea or a selection bias from a small number of cases. The present study did not show a gender difference in Korean BOOP patients including all 3 categories, that is, idiopathic, secondary, and rapidly progressive forms.

A few case reports have been published on an accelerated or rapidly progressive form of BOOP in a small percentage of patients (12, 13). In a recent review of 10 such cases, all but one were associated with various illnesses, such as rheumatoid arthritis, asthma, dermatomyositis, cancer, hypothyroidism, and chronic obstructive pulmonary disease (14). All 10 patients underwent an open lung biopsy that revealed their predominant histopathology to be BOOP. In addition, alveolar septal inflammation/fibrosis and honeycombing were common features at autopsy. The authors speculated that BOOP could be a precursor of alveolar septal inflammation and honeycomb lung and thus might represent an early phase of the temporal spectrum of interstitial lung disease. Yousem *et al.* (15) also noted that cases of idiopathic BOOP nonresponsive to corticosteroid were accompanied by scarring and remodeling of the background parenchyma in 89% of cases, in contrast to 10% of those with good prognosis. There were no honeycombing changes in their cases and they suggested that the background fibrosis might have resulted from aggressive nature of BOOP or pre-existing lung damage caused by a chronic interstitial pneumonia with superimposed BOOP reaction. Our analysis of cases with progressive BOOP does not allow for definitive conclusions as to whether the interalveolar septal fibrosis is a part of BOOP that involves the alveolar interstitium or just secondary reaction to the preexisting chronic interstitial inflammation. This is partly because none of six cases had follow-up lung biopsies or postmortem examination, so that we were not able to definitely exclude the possibility of preexisting chronic lung disease. In this regard, intraluminal organization is sometimes observed within the airspace in the transbronchial lung biopsy specimens obtained from patients with the clinical characteristics of idiopathic pulmonary fibrosis (IPF) raising the possibility of organizing pneumonia. The confusion between BOOP and fibrosing interstitial pneumonia/usual interstitial pneumonia (UIP) can be traced to the interpretation of extensive intra-airway organization as "interstitial fibrosis" (16, 17). The differential diagnosis is important, however, because patients with BOOP have a favorable prognosis and response to therapy, compared with those with UIP (22).

The histologic differential diagnosis of BOOP can be divided into 2 broad groups (16). The first group is comprised of lesions that may show a BOOP pattern. Since BOOP are common reparative reactions in the lung, there are numerous lesions that may show a BOOP pattern as part of their histologic features. Indeed a major issue for pathologists in the diagnosis of organizing pneumonia (OP) is the exclusion of infection, because many organizing infections may show a pattern similar to that of BOOP. Thus negative special stains for microorganisms and biopsy cultures should be confirmed prior to making the diagnosis of COP. The term COP was suggested in order to avoid confusion with post-infective organizing pneumonia (2). The second group was established in part because of the clinical presentation and because they represent idiopathic fibrosing interstitial pneumonias. This group includes idiopathic organizing DAD/acute interstitial pneumonia (AIP) and IPF. Organizing DAD shows some overlap with BOOP histologically, although the changes in the former tend to be more extensive, uniform, and confluent, and hyaline membranes are often present in the former. There are some cases of idiopathic organizing DAD that show both clinical and histologic overlap with BOOP, and the distinction between the two may be somewhat arbitrary (16, 17).

Nagata et al. (23) presumed that IPF with OP represents an incompletely resolved course of BOOP that is accompanied with fibrotic changes. However, patients with IPF and OP can not be classified as BOOP, because the honeycombing appearance on their chest radiography or CT scans is reportedly never seen in BOOP patients (1) and moreover, the presence of honeycombing as part of the interstitial pneumonia (and not an incidental finding) serves as evidence against the diagnosis of BOOP (16, 17). More studies are needed to define the relationship between BOOP presenting as an infiltrative pulmonary disease and UIP.

The histologic features of BOOP are frequently encountered in cases of HP and organizing CEP. A few eosinophils are occasionally seen in lesions of BOOP, but numerous eosinophils raise the possibility of organizing CEP or an organizing allergic reaction, such as a drug reaction. Some cases appear to represent true hybrid cases of either BOOP and CEP or BOOP and HP. Likewise, the presence of more than a rare or isolated granuloma should lead to an exclusion of granulomatous infection and, more commonly, HP (16, 17).

Solitary focal pneumonia has been suggested as the third imaging pattern of BOOP (10) and such cases have been reported (24, 25). Some patients present with a subacute process identical to typical BOOP, whereas others are asymptomatic and the solitary pulmonary opacity is often located in the upper lobes. Given the propensity of aspiration to affect upper lobe particularly apicoposterior segment in supine position (26), difficulties arise as to the pathologic differentiation between focal solitary BOOP and just localized OP following aspiration, despite great efforts to detect foreign bodies or extrinsic lipid. We suspect that some cases probably corre-

spond to unresolved pneumonia and indeed the possibility has been suggested that BOOP might have resulted from organization of any other type of infectious pneumonia (18, 27).

In summary we performed a critical and comprehensive review of 45 cases of biopsy-proven BOOP and were able to ascertain cases of rapidly progressive BOOP histologically characterized with interalveolar septal inflammation and fibrosis. However we could not identify definite risk factors for an unfavorable outcome in BOOP, for which larger prospective studies are warranted in the future.

## ACKNOWLEDGEMENT

The authors thank the following pathologists for providing their cases for review: Han Kyeom Kim, M.D., Korea University; Eun Joo Seo, M.D., Catholic University of Korea; Na Hye Myoung, M.D., Dankook University; Kun Young Kwon, M.D., Keimyung University; Heasoo Koo, M.D., Ewha Womans University; Eun Suk Ko, M.D., Soonchunhyang University; Jeong Hae Kie, M.D., NHIC Ilsan Hospital; Jong Eun Joo, M.D., Nowon Eulji General Hospital; Woo Hee Jung, M.D., Yonsei University; Won Hee Choi, M.D., Yeungnam University; Yong Hee Lee, M.D., Pundang Cha General Hospital; Eun Hee Lee, M.D., Catholic University of Korea Daejeon St. Mary's Hospital.

We also thank Drs Eugene Mark, Department of Pathology, Massachusetts General Hospital, Boston, and Anna-Luise Katzenstein, Department of Pathology, Crouse Hospital SUNY Health Science Center, New York, U.S.A. for critical microscopic review and discussion of selected cases.

We are very grateful to Drs. Young Sam Kim, Department of Internal Medicine, Yonsei University and Kyu Rae Kim, Department of Pathology, Asan Medical Center for their assistance in the work-up of their cases.

## REFERENCES

1. Epler GR, Colby TV, McLoud TC, Carrington CB, Gaensler EA. *Bronchiolitis obliterans organizing pneumonia*. *N Engl J Med* 1985; 312: 152-8.
2. Davidson AG, Heard BE, McAllister WAC, Turner-Warwick MEH. *Cryptogenic organizing pneumonitis*. *Q J Med* 1983; 207: 382-94.
3. Cordier JF, Loire R, Brune J. *Idiopathic bronchiolitis obliterans organizing pneumonia. Definition of characteristic clinical profiles in a series of 16 patients*. *Chest* 1989; 96: 999-1004.
4. Lohr RH, Boland BJ, Douglas WW, Dockrell DH, Colby TV, Swensen SJ, Wollan PC, Silverstein MD. *Organizing pneumonia. Features and prognosis of cryptogenic, secondary and focal variants*. *Arch Intern Med* 1997; 157: 1323-9.
5. Epler GR. *Bronchiolitis obliterans organizing pneumonia*. *Arch Intern Med* 2001; 161: 158-64.

6. Costabel U, Guzman J, Teschler H. *Bronchiolitis obliterans with organizing pneumonia: outcome*. *Thorax* 1995; 50(Suppl 1): S59-S64.
7. Cordier JF. *Bronchiolitis obliterans organizing pneumonia*. *Semin Respir Crit Care Med* 2000; 21: 135-46.
8. Epler GR. *Bronchiolitis obliterans organizing pneumonia*. *Semin Respir Infect* 1995; 10: 65-77.
9. Epler GR. *Heterogeneity of bronchiolitis obliterans organizing pneumonia*. *Curr Opin Pulm Med* 1998; 4: 93-7.
10. Cordier JF. *Cryptogenic organizing pneumonitis. Bronchiolitis obliterans organizing pneumonia*. *Clin Chest Med* 1993; 14: 677-92.
11. Lee KS, Kullnig P, Hartman TE, Muller NL. *Cryptogenic organizing pneumonia in 43 patients: CT findings*. *Am J Roentgenol* 1994; 162: 543-6.
12. Iannuzzi MC, Farhi DC, Bostrom PD, Petty TL, Fisher JH. *Fulminant respiratory failure and death of a patient with idiopathic bronchiolitis obliterans*. *Arch Intern Med* 1985; 145: 733-4.
13. Nizami IY, Kissner DG, Visscher DW, Dubaybo BA. *Idiopathic bronchiolitis obliterans with organizing pneumonia: An acute and life-threatening syndrome*. *Chest* 1995; 108: 271-7.
14. Cohen AJ, King TE, Downey GP. *Rapidly progressive bronchiolitis obliterans with organizing pneumonia*. *Am J Resp Crit Care Med* 1994; 149: 1670-5.
15. Yousem SA, Lohr RH, Colby TV. *Idiopathic bronchiolitis obliterans organizing pneumonia/cryptogenic organizing pneumonia with unfavorable outcome: pathologic predictors*. *Mod Pathol* 1997; 10: 864-71.
16. Colby TV. *Pathologic aspects of bronchiolitis obliterans organizing pneumonia*. *Chest* 1992; 102: 38S-43S.
17. Myers JL, Colby TV. *Pathologic manifestations of bronchiolitis, constrictive bronchiolitis, cryptogenic organizing pneumonia, and diffuse panbronchiolitis*. *Clin Chest Med* 1993; 14: 611-22.
18. Cordier JF. *Organizing pneumonia*. *Thorax* 2000; 55: 318-28.
19. Cazzato S, Zompatori M, Baruzzi G, Schiattone ML, Burzi M, Rossi A, Ratta L, Terzuolo G, Falcone, Poletti V. *Bronchiolitis obliterans-organizing pneumonia: an Italian experience*. *Respir Med* 2000; 94: 702-8.
20. Dina R, Sheppard MN. *The histological diagnosis of clinically documented cases of cryptogenic organizing pneumonia: diagnostic features in transbronchial biopsies*. *Histopathology* 1993; 23: 541-5.
21. Han SK, Yim J-J, Lee JH, Yoo CG, Chung HS, Shim Y-S, Kim YH. *Bronchiolitis obliterans organizing pneumonia in Korea*. *Respirology* 1998; 3: 187-91.
22. Katzenstein A-L, Myers JL, Prophet M, Corley LS III, Shin MS. *Bronchiolitis obliterans and usual interstitial pneumonia. A comparative clinicopathologic study*. *Am J Surg Pathol* 1986; 10: 373-81.
23. Nagata N, Nagatomo H, Yoshii C, Nikaido Y, Kido M. *Features of idiopathic pulmonary fibrosis with organizing pneumonia*. *Respiration* 1997; 64: 331-5.
24. Domingo JA, Perez-Calvo JI, Carretero JA, Ferrando J, Cay A, Civiero F. *Bronchiolitis obliterans organizing pneumonia. An unusual cause of solitary pulmonary nodule*. *Chest* 1993; 103: 1621-3.
25. Yang DG, Kim KD, Shin DH, Choe KO, Kim SK, Lee WY. *Idiopathic bronchiolitis obliterans with organizing pneumonia presenting with spontaneous hydropneumothorax and solitary pulmonary nodule*. *Respirology* 1999; 4: 267-70.
26. Dail DH. *Bronchial and transbronchial diseases*. In: Dail DH, Hammar SP, editors, *Pulmonary pathology*. New York: Springer-Verlag, 1994: 79-87.
27. Katzenstein AL-A. *Personal communication*, 2001.