

Partial Preventive Effect of Ibuprofen in a Mouse Model of Vascular Cognitive Impairment Induced by Unilateral Common Carotid Artery Occlusion

Jin Soo Lee, M.D.
Doo Soon Im, B.S.*†
Gyeong Joon Moon, Ph.D.†
Byoung Joo Gwag, Ph.D.*†
So Young Moon, M.D., Ph.D.
Ji Man Hong, M.D., Ph.D.
In Soo Joo, M.D.

Department of Neurology and Interdisciplinary Course for Neuroscience and Technology*, Graduate School, Ajou University, and Neurotech Pharmaceuticals Co.†, Suwon, Korea

Received : September 23, 2009
Revision received : September 24, 2009
Accepted : November 4, 2009

Address for correspondence

In Soo Joo, M.D.
Department of Neurology, School of Medicine and Graduate School, Ajou University, San 5 Woncheon-dong, Yeongtong-gu, Suwon 442-749, Korea
Tel: 82-31-219-5172
Fax: 82-31-219-5178
E-mail : isjoo@ajou.ac.kr

*This study was supported by a grant from Korean Dementia Association and Eisai Korea Inc.

Background: Vascular cognitive impairment (VCI) has been shown to be related to inflammation in previous clinical and animal studies. A recent study showed VCI and increase in inflammatory cytokines in a mouse model of right common carotid artery occlusion (rCCAO). We aimed to determine the preventive effect of an anti-inflammatory drug, ibuprofen, on VCI in an rCCAO mouse model. **Methods:** C57BL/6 mice were rCCAO- or sham-operated. First, serial object recognition tests with respective vehicle and sham groups of mice were performed weekly to evaluate VCI until 4 weeks after surgery, and the discrimination index was compared. Histological observations were made 3 hr, 1 day, 1 week, and 4 weeks after surgery. Second, object recognition tests and histological studies with three groups of mice were performed 4 months after surgery to evaluate the preventive effect of ibuprofen on VCI. The experimental groups were sham (n=15), vehicle (rCCAO-operated; n=15), and ibuprofen (rCCAO-operated, ibuprofen-supplemented chow; n=15). **Results:** Until 4 weeks after rCCAO surgery, the discrimination index was lower in rCCAO-operated mice than in sham-operated mice, and the difference was marginally significant in week 1 (mean \pm standard error: 0.35 \pm 0.08 for rCCAO vs. 0.68 \pm 0.12 for sham; *t*-test, *p*=0.050). The index from week 2 to week 4 tended to be low in rCCAO-operated mice as compared to sham-operated mice, but the difference was not statistically significant. Eosin-positive neurons were not observed at all stages, but activated microglia, which was stained by using antibodies against Iba-1, was observed in some rCCAO-operated mice on day 1 and week 1. The preventive effect of ibuprofen was not sufficient on objective recognition tests (discrimination index, mean \pm standard error: sham 0.36 \pm 0.10, vehicle 0.01 \pm 0.15 and ibuprofen 0.14 \pm 0.13; analysis of variance, *F*=1.987, *p*=0.151), and no specific histological finding was observed 4 months after surgery. **Conclusions:** The anti-inflammatory drug ibuprofen was not effective enough to prevent VCI induced by rCCAO. The effects of inflammation seemed to be evident only in the early phase in this model.

Key Words: Vascular cognitive impairment, Dementia, Common carotid artery occlusion, Object recognition test, Ibuprofen

INTRODUCTION

The incidence of vascular cognitive impairment (VCI) is particularly high among Asian populations [1, 2], and it can progress toward obvious vascular dementia. Nonetheless, a specific treatment for preventing vascular dementia has not been developed although a number of drugs have been proposed, such as those for prevention of stroke and control of vascular risk factors [3, 4]. Anti-inflammatory drugs can be another option since inflammatory changes have been observed in several clinical and animal studies [5-7].

A recent study reported that right common carotid artery occlusion (rCCAO) in mice could induce behavioral abnormality 1 month after operation and that the deficit was related to damage to the cortical subcortical circuit [8]. There was no gross neuronal death, but rarefaction was shown on the medial corpus callosum, and the levels of inflammatory cytokines increased. The authors suggested that these changes resulted from chronic cerebral hypoperfusion induced by rCCAO. However, it is not clear whether only chronic hypoperfusion dominantly caused the cognitive deficit.

The object recognition test is one behavioral experiment

for animals and is related to nonspatial working memory [9]. Damage to the cortical subcortical circuit is known to affect cognitive function and to be associated with VCI [8]. Impairment observed during the object recognition test was induced in some animal models by unilateral CCAO in mice and bilateral CCAO in rats [8, 10].

In this study, to estimate whether early ischemic insult affects the cognitive deficit in an rCCAO model, serial object recognition tests and histological observations were evaluated. We also aimed to determine the effect of an anti-inflammatory drug, ibuprofen, in preventing VCI by using an rCCAO model.

MATERIALS AND METHODS

1. Animal preparation and surgical procedure

All experiments were performed in accordance with the Guidelines for Animal Experiments of Ajou University. Wild-type female C57BL/6 mice weighing 18 to 26 g (10 to 11 months) and male C57BL/6 mice weighing 18 to 26 g (10 to 11 months) were purchased from Orient, Korea. The male mice were only used for early cognitive function tests. The mice were given free access to food and water under a 12/12 light-dark cycle. For anesthesia, the inhalation or intraperitoneal (i.p.) method was used, and the latter was only used for early cognitive function tests. The mice were administered 2.5% isoflurane for anesthesia induction and 1.5% isoflurane for anesthesia maintenance in 30% O₂/70% N₂O through a face mask. In the case of i.p. anesthesia, mice were anesthetized intraperitoneally with chloral hydrate (400 mg/kg). For the animal model of rCCAO, the right CCA was carefully isolated from the adjacent vagus nerve after midline neck incision and completely ligated with 6-0 silk sutures. Upon conclusion of behavioral testing, the animals were anesthetized with chloral hydrate (400 mg/kg, i.p.) and intracardially perfused with 4% paraformaldehyde solution in 0.1 M phosphate-buffered saline. Paraffin-embedded coronal sections of the brain between 1.0 mm anterior to and 1.0 mm posterior to the bregma were used.

2. Object recognition test

The object recognition test was performed by using a modification of a method described in a previous study [8] (Fig. 1A). Briefly, the apparatus used in the test was constructed using an opaque white acrylic box (30×45×30 cm). The objects to be discriminated were made of acrylic and were of two different shapes and colors: cubes and pyramids of 12 cm height and 6 cm width. The day before the test, the mice were allowed to explore the box without any objects for 5 min. On the day of the test, a session of two trials was conducted. The inter-trial interval was 60 min. In the first trial, two identical objects (black cubes) were presented on two opposite sides of the box, and the mice explored for 10 min. Exploration was considered if the center of the mouse body was at a distance 5 cm from the object. In the second trial, one of the objects presented in the first trial was replaced with a new object, and the mice were placed in the box for 3 min. The left cube was replaced with a red pyramid for the early serial cognitive tests, and the right one was replaced with a green pyramid for the chronic phase test with the ibuprofen group. The time spent exploring the familiar (F) object and the new (N) object was automatically recorded by a video tracking system, EthoVision 3.0 (Noldus Information Technology, Wageningen, The Netherlands). The discrimination index was calculated as $(N-F)/(N+F)$ for intergroup comparison.

3. Histochemical observation

Three animals in each group were used for histological evaluation. Coronal brain blocks, including the corpus callosum and striatum, were embedded in paraffin and sectioned with a thickness of 5 μ m. Standardized hematoxylin and eosin (Sigma-Aldrich, St. Louis, MO, USA) stain was used to detect neuronal death and morphologic change of brain tissue. Tissue sections were processed by soak mounting and were incubated in the antibody to Iba-1 (Wako, Osaka, Japan; diluted 1:200) for staining of microglia. The sections were subsequently incubated with biotinylated anti-rabbit IgG (Vector Laboratories, Burlingame, CA, USA; diluted 1:200) for

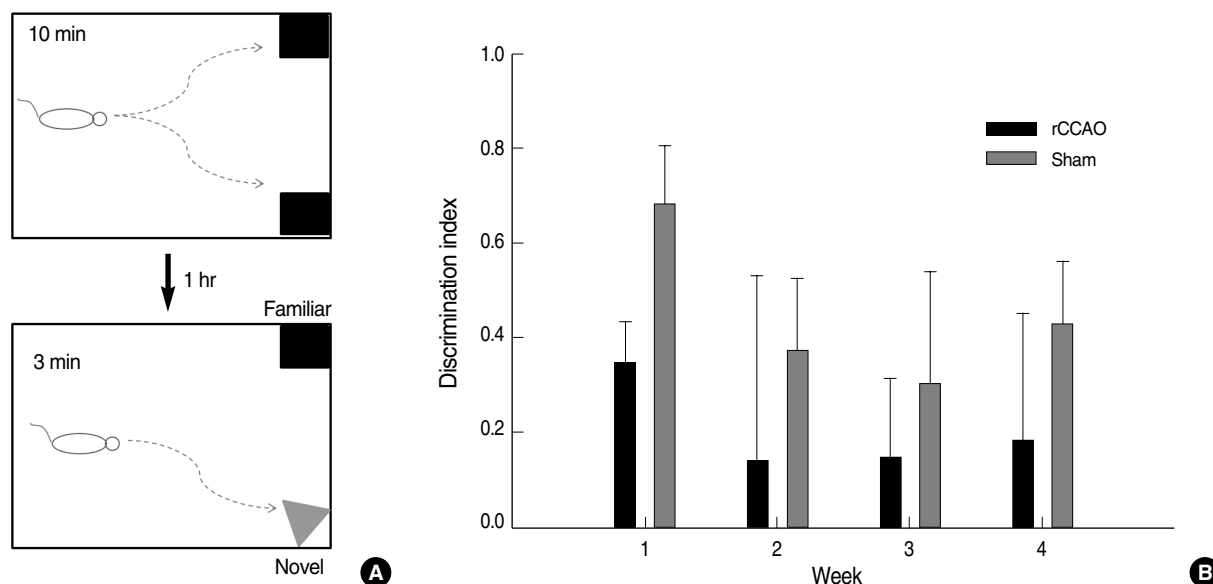


Fig. 1. Serial object recognition tests until 4 weeks after surgery. (A) Method of object recognition test: in the first trial, two identical objects (black cubes) were presented on two opposite sides of the box, and the mice explored for 10 min. In the second trial, one of the objects presented in the first trial was replaced with a new object (red or green pyramid), and the mice were placed in the box for 3 min. (B) Weekly objective recognition tests were performed until 4 weeks after surgery. The histogram shows the discrimination index as the mean \pm SEM. The discrimination index in week 1 was lower in rCCAO-operated mice than in sham-operated mice, and the difference was marginally significant ($p=0.050$). The index from week 2 to week 4 tended to be lower in rCCAO-operated mice as compared to sham-operated mice, but the differences were not statistically significant.

2 hr, and then incubated with an avidin-biotin peroxidase complex solution (Vectastain ABC kit, Vector Laboratories; diluted 1:100) for 1.5 hr. Finally, immunoreaction products were visualized using diaminobenzidine as the substrate (DAB Kit, Vector Laboratories).

4. Experimental sets and grouping

1) To reveal early cognitive changes from rCCAO

To evaluate cognitive condition after rCCAO, the objective recognition test was performed from week 1 to week 4 after surgery. Male C57BL/6 mice weighing 18 to 26 g (10 to 11 months) were used in this experiment. The object recognition test was performed before surgery and the mice with discrimination index less than 0.10 were excluded. Among 60 mice, 33 remained up to the final tests. Mice were anesthetized i.p. with chloral hydrate (400 mg/kg) for surgery. On week 1, the object recognition test was performed on five rCCAO- and four sham-operated mice. From week 2 to week 4, it was respectively performed on groups of four rCCAO- and four sham-operated mice.

2) To reveal early histological changes from rCCAO

To evaluate serial histological conditions, female C57BL/6 mice weighing 18 to 26 g (10 to 11 months) were used. All mice were rCCAO-operated and were compared with sham-operated mice whose brain tissues were obtained at 4 months after surgery. Serial groups of three mice were sacrificed at 3 hr, 24 hr, 3 days, 1 week, and 4 weeks after surgery. The brain tissues were embedded in paraffin and sectioned with a thickness of 5 μ m.

3) To evaluate role of ibuprofen for prevention of VCI

Animals were randomly chosen to evaluate anti-inflammatory effect of ibuprofen for prevention of cognitive decline from rCCAO. Female C57BL/6 mice weighing 18 to 26 g (10 to 11 months) were used in this experiment. The experimental group included sham ($n=15$), vehicle ($n=15$), and ibuprofen ($n=15$), among which mice in the vehicle and ibuprofen groups were subjected into rCCAO. The mice were administered 2.5% isoflurane for anesthetic induction and 1.5% isoflurane for anesthetic maintenance in 30% O_2 /70% N_2O through a face mask. After surgery, mice in the

ibuprofen group were fed ad libitum with ibuprofen-supplemented chow (62.5 mg/kg/d) and mice in the sham and vehicle groups were fed with control chow. Upon conclusion of behavioral testing, 4 months after operation, animals were anesthetized with chloral hydrate (400 mg/kg, i.p.) and intracardially perfused with 4% paraformaldehyde solution in 0.1 M phosphate-buffered saline.

5. Statistical analysis

Data are presented as the mean \pm standard error of the mean (SEM). A *t*-test was used to compare the discrimination index between rCCAO- and sham-operated mice in the early serial object recognition tests. An analysis of variance (ANOVA) was used to compare the performance on the object recognition test to evaluate the anti-inflammatory drug effect. Scheffé's test was used for post hoc comparisons. Differences with $p < 0.05$ were considered to be statistically significant. Statistical analyses were performed using a commercially available software package, SPSS version 12.0 (SPSS Inc., Chicago, IL, USA). Graphs were drawn using SigmaPlot version 9.0 (Systat Software Inc., San Jose, CA, USA).

RESULTS

1. Early deterioration of cognition on objective recognition test after rCCAO surgery

To evaluate early cognitive changes after rCCAO, serial objective recognition tests were performed from week 1 to week 4 after surgery. The object recognition test was performed before surgery, and the mice with a discrimination index less than 0.10 were excluded. Among 60 mice, 33 remained up to the final tests. On week 1, object recognition tests were performed on five rCCAO- and four sham-operated mice. From week 2 to week 4, it was performed on groups of four rCCAO- and four sham-operated mice. In week 1, the discrimination index was lower in rCCAO-operated mice than in sham-operated mice, and the difference was marginally significant (discrimination index, mean \pm SEM; 0.35 ± 0.08

for rCCAO vs. 0.68 ± 0.12 for sham, $p = 0.050$) (Fig. 1B). The index from week 2 to week 4 tended to be low in rCCAO-operated mice as compared to sham-operated mice, but the difference was not statistically significant (discrimination index in week 2, mean \pm SEM; 0.14 ± 0.39 for rCCAO vs. 0.38 ± 0.15 for sham, $p = 0.595$; week 3, mean \pm SEM; 0.15 ± 0.16 for rCCAO vs. 0.30 ± 0.23 for sham, $p = 0.605$; week 4, mean \pm SEM; 0.19 ± 0.27 for rCCAO vs. 0.43 ± 0.13 for sham, $p = 0.434$) (Fig. 1B). The statistical significance of the difference in the discrimination index was maximal at week 1.

2. Microglial activation at week 1 after rCCAO

From 3 hr to 4 weeks after surgery, serial histological studies were performed. No evident neuronal death was found on hematoxylin and eosin staining at all points (Fig. 2A). Iba-1-positive cells, which reflected microglial activation, appeared at day 7 (Fig. 2B). This inflammatory change appeared mild but was clearly evident, and was mostly observed on the watershed zone of the right CCA territory but not on the corpus callosum.

3. A partial effect of ibuprofen in preventing VCI induced by rCCAO

None of the sham- or rCCAO-operated mice died, and none showed any apparent motor weakness. The object recognition test was conducted 4 months after operation. The discrimination ability tended to decrease in the vehicle group as compared to the sham group (discrimination index, mean \pm SEM: sham 0.36 ± 0.10 , vehicle 0.01 ± 0.15 , and ibuprofen 0.14 ± 0.13 ; ANOVA, $F = 1.987$, $p = 0.151$) (Fig. 3). The index slightly recovered in the ibuprofen group (Fig. 3). On histological observation, no apparent neuronal death was revealed on hematoxylin and eosin staining (Fig. 4A). Immunohistochemical staining with the Iba-1 antibody did not reveal activation of microglia in the three groups (Fig. 4B). Inflammatory change was not obvious in rCCAO-operated mice in the chronic phase, indicating that ibuprofen might have had an effect only in the early phase of cerebral hypoperfusion.

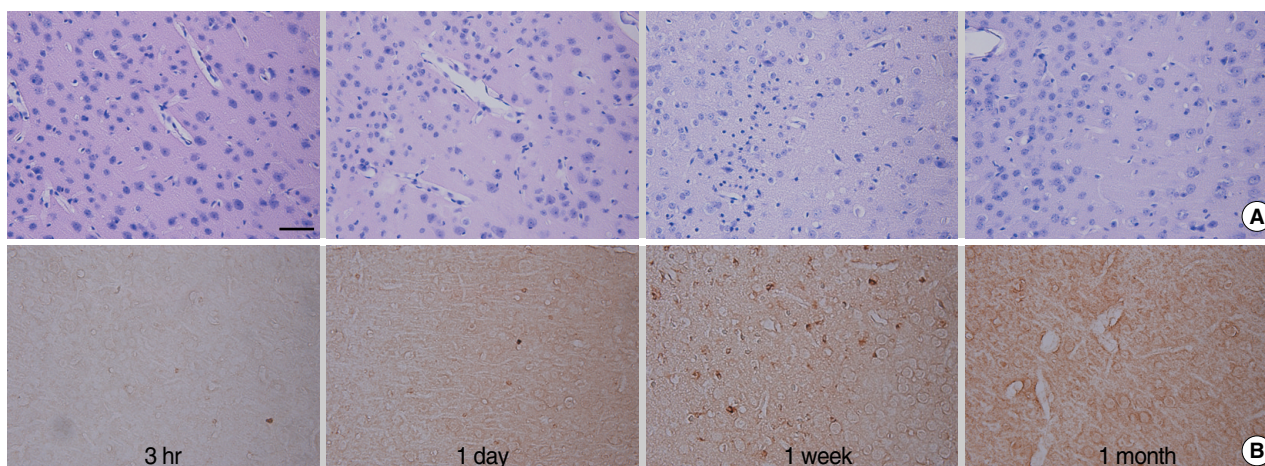


Fig. 2. Apoptosis and microglial activation induced in rCCAO-operated mice in the early phase. (A) Eosin-positive neurons were not observed in all periods. (B) Microglial activation, as indicated by immunohistochemical staining with Iba-1 antibody, was evident particularly in week 1. Photographs were taken on the right sensory cortex (magnification, $\times 400$; bar=50 μm).

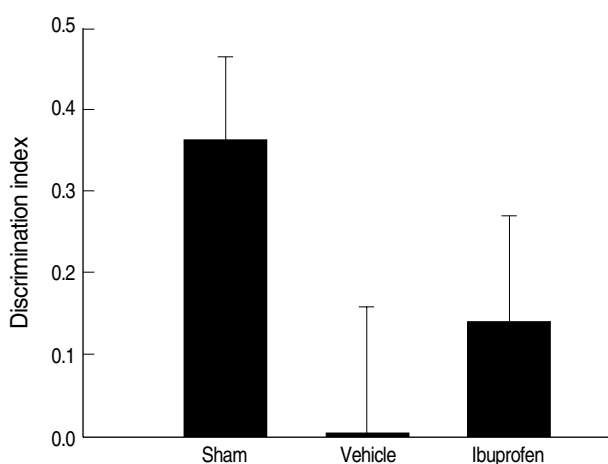


Fig. 3. The partial effect of ibuprofen in the prevention of cognitive deficit in the object recognition test performed 4 months after surgery. The discrimination ability tended to decrease in the vehicle group as compared to the sham group (discrimination index, mean \pm SEM: sham 0.36 \pm 0.10; vehicle 0.01 \pm 0.15; and ibuprofen 0.14 \pm 0.13; ANOVA, $F=1.987$, $p=0.151$). The index slightly recovered in the ibuprofen group.

DISCUSSION

In our study, nonspatial working memory examined by object recognition test was impaired after rCCAO, and microglial activation occurred mostly in the early phase of cerebral hypoperfusion. Anti-inflammatory drugs only have a partial preventive effect against VCI due to chronic cerebral hypoperfusion.

Cognitive impairment observed in rCCAO-operated mice might be associated with vascular damage in the cortical subcortical circuit. It has been suggested that in human patients with subcortical ischemic vascular dementia, the area vulnerable to hypoperfusion is associated with impairment of the cortical subcortical circuit [11]. Among patients with white matter lesions, those who had cognitive impairment showed decreased levels of regional cerebral blood flow as compared to those without cognitive impairment [12]. Similarly, animal models of cerebral hypoperfusion showed behavioral change that reflects damage to the cortical subcortical circuit. In one study, spatial working memory examined by an eight-arm radial maze test was selectively impaired in a mouse model with bilateral CCA stenosis [6]. In another study, nonspatial working memory examined by the object recognition test was impaired in a rat model with bilateral CCA occlusion [10].

In our study, nonspatial working memory performance decreased in rCCAO-operated mice. Unilateral rCCAO has been proposed as a model to bring about VCI via chronic cerebral hypoperfusion without acute lesion [8]. The authors suggested that the cognitive impairment was associated with decreased fiber density on the medial corpus callosum. However, to some extent our results contradict that study. Damage or rarefaction on the corpus callosum was not observed in our study. Instead, activated microglia were observed in

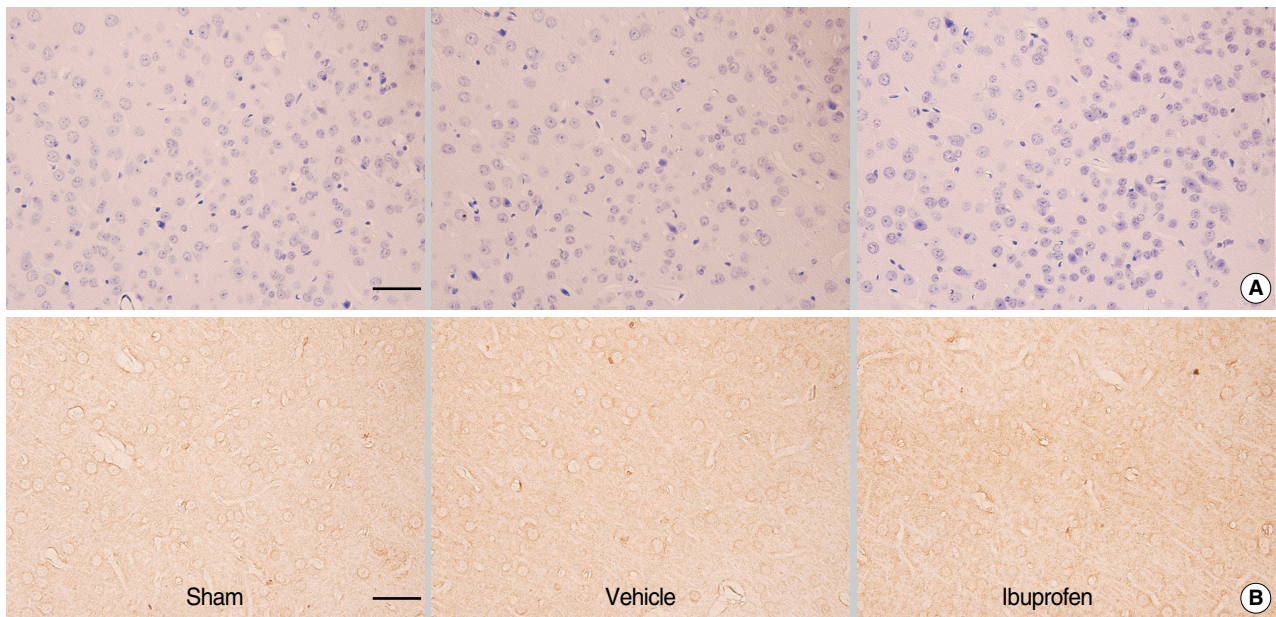


Fig. 4. Histological findings of the right sensory cortex 4 months after surgery. (A) There was no evident eosin-positive neurons among specimens of the three groups on hematoxylin and eosin staining (magnification, $\times 400$; bar= $50\ \mu\text{m}$). (B) Microglial activation was not observed in the three groups (immunohistochemical staining with the Iba-1 antibody; magnification, $\times 400$; bar= $50\ \mu\text{m}$).

some rCCAO-operated mice in the early phase, and this feature was prominent on the watershed zone of the right CCA. This area was similarly involved in another mouse model, where cognitive impairment was induced by varying degrees of bilateral CCA stenosis using microcoils [13]. Moderate stenosis on the right CCA and then severe stenosis on the left CCA were induced. The model revealed that cortical, hippocampal, and corpus callosal damage was located on the watershed area of the CCA. Our results are supported by that study, although change in the corpus callosum was not evident in our study. Damage to the cortical subcortical circuit indicates not only white matter lesion such as the corpus callosum but also any cortical lesion in the circuit. Hypoperfusion injury on the watershed area of unilateral CCA may affect the cortical subcortical circuit. VCI induced by rCCAO in our study is possibly associated with hypoperfusion to the area.

An early ischemic insult from rCCAO seems to affect the cognitive changes apart from the chronic effect of cerebral hypoperfusion. In our serial object recognition tests, the difference in performance between the rCCAO- and sham-operated mice was significant at the earliest point, i.e., 1 week after surgery. It is logical to postulate that blood flow to the

brain is suddenly disturbed in the course of surgery for rCCAO. Then collateral circulations, primarily abetted by the Circle of Willis, develop quickly, and hypoperfusion recovers to some extent in the chronic stage [14].

In a previous study using an rCCAO mouse model, inflammatory cytokines increased in the early phase of hypoperfusion [8]. Post-ischemic inflammation contributes to ischemic brain injury within days [15]. Our study showed microglial activation within 7 days after surgery in some mice, but histological change was not evident after 1 month. The cognitive features reflected the histological changes. Nonetheless, those changes were mild and appeared in only a few mice; therefore, chronic injury from cerebral hypoperfusion should not be excluded.

A tendency of decreased cognition during chronic cerebral hypoperfusion might be effected under sustained oligemic status due to rCCAO. There was a mismatch in our results in that cognition was impaired but neuronal death was not observed. Injury due to rCCAO seemed to be relatively mild because neuronal death was not observed even at 4 months after surgery. Regardless of neuronal death, dendritic arborizations and synaptic contacts might be affected [16]. A decline in microtubule-associated protein-2, which reflects den-

driftic branching, remodeling, or plasticity, and reduction of synaptophysin protein, which reflects synaptic condition, have been reported to be associated with chronic cerebral hypoperfusion [17, 18]. These factors might affect cognitive dysfunction without evident neuronal death in the status between benign oligemia and ischemic penumbra.

Inflammatory processes in the brain have been shown to be related to chronic cerebral hypoperfusion in both clinical and animal studies. Activation of the microglia, a marker of inflammation, was shown in a previous clinical pathological study [5]. Microglial activation was also demonstrated in animal studies with chronic cerebral hypoperfusion using a mouse model with bilateral CCA stenosis and a rat model with bilateral CCA occlusion [6, 7]. Ibuprofen was thought to be able to suppress microglial activation and reduce cognitive impairment, but in our results inflammation seemed to be little affected in the chronic phase of cerebral hypoperfusion. A previous study using an rCCAO model also showed that the levels of both IL-1 β , and IL-6 were highest 1 day after operation [8]. A partial preventive effect of ibuprofen might result from only early association with inflammation in the rCCAO model. Overall, the effects of inflammation seem to be evident only in the early phase and are partially responsible for the pathogenesis of VCI in the chronic rCCAO mouse model.

Chronic injury due to cerebral hypoperfusion might have affected the rCCAO-operated mice to a significant degree, although inflammatory changes were revealed in histological studies only in the early phase. To confirm this, further studies should be done to clarify the decreased cerebral metabolic state arising due to chronic cerebral hypoperfusion. Positron emission tomography or single photon emission computed tomography animal studies can be performed.

REFERENCES

- Geldmacher DS, Whitehouse PJ. *Evaluation of dementia. N Engl J Med* 1996; 335: 330-6.
- Ikeda M, Hokoishi K, Maki N, Nebu A, Tachibana N, Komori K, et al. *Increased prevalence of vascular dementia in Japan: a community-based epidemiological study. Neurology* 2001; 57: 839-44.
- Lee AY. *New treatment of vascular cognitive impairment. J Korean Dementia Assoc* 2005; 4: 63-7.
- Román GC. *Vascular dementia prevention: a risk factor analysis. Cerebrovasc Dis* 2005; 20(S2): 91-100.
- Akiguchi I, Tomimoto H, Suenaga T, Wakita H, Budka H. *Alterations in glia and axons in the brains of Binswanger's disease patients. Stroke* 1997; 28: 1423-9.
- Shibata M, Ohtani R, Ihara M, Tomimoto H. *White matter lesions and glial activation in a novel mouse model of chronic cerebral hypoperfusion. Stroke* 2004; 35: 2598-603.
- Farkas E, Donka G, de Vos RA, Mihály A, Bari F, Luiten PG. *Experimental cerebral hypoperfusion induces white matter injury and microglial activation in the rat brain. Acta Neuropathol* 2004; 108: 57-64.
- Yoshizaki K, Adachi K, Kataoka S, Watanabe A, Tabira T, Takahashi K, et al. *Chronic cerebral hypoperfusion induced by right unilateral common carotid artery occlusion causes delayed white matter lesions and cognitive impairment in adult mice. Exp Neurol* 2008; 210: 585-91.
- Ennaceur A, Delacour J. *A new one-trial test for neurobiological studies of memory in rats. 1: behavioral data. Behav Brain Res* 1988; 31: 47-59.
- Sarti C, Pantoni L, Bartolini L, Inzitari D. *Persistent impairment of gait performances and working memory after bilateral common carotid artery occlusion in the adult Wistar rat. Behav Brain Res* 2002; 136: 13-20.
- Román GC. *Brain hypoperfusion: a critical factor in vascular dementia. Neurol Res* 2004; 26: 454-8.
- Kato H, Yoshikawa T, Oku N, Imaizumi M, Takasawa M, Kimura Y, et al. *Statistical parametric analysis of cerebral blood flow in vascular dementia with small-vessel disease using Tc-HMPAO SPECT. Cerebrovasc Dis* 2008; 26: 556-62.
- Miki K, Ishibashi S, Sun L, Xu H, Ohashi W, Kuroiwa T, et al. *Intensity of chronic cerebral hypoperfusion determines white/gray matter injury and cognitive/motor dysfunction in mice. J Neurosci Res* 2009; 87: 1270-81.
- Tamaki M, Kidoguchi K, Mizobe T, Koyama J, Kondoh T, Sakurai T, et al. *Carotid artery occlusion and collateral circulation in C57Black/6J mice detected by synchrotron radiation microangiography. Kobe J Med Sci* 2006; 52: 111-8.
- Dirnagl U, Iadecola C, Moskowitz MA. *Pathobiology of ischaemic stroke: an integrated view. Trends Neurosci* 1999; 22: 391-7.
- Farkas E, Luiten PG, Bari F. *Permanent, bilateral common carotid artery occlusion in the rat: a model for chronic cerebral hypoperfusion-related neurodegenerative diseases. Brain Res Rev* 2007; 54: 162-80.

17. Liu HX, Zhang JJ, Zheng P, Zhang Y. *Altered expression of MAP-2, GAP-43, and synaptophysin in the hippocampus of rats with chronic cerebral hypoperfusion correlates with cognitive impairment. Mol Brain Res* 2005; 139: 169-77.
18. Thiel G. *Synapsin I, synapsin II, and synaptophysin: marker proteins of synaptic vesicles. Brain Pathol* 1993; 3: 87-95.