

Clinical Usefulness of Modified Bondy Operation for Management of Cholesteatomas

Eun Hwang, Hye Jin Lim, Han-Bin Lee, Sung Yeal Kim, Keehyun Park, Hun Yi Park and Yun-Hoon Choung

Department of Otolaryngology, Ajou University School of Medicine, Suwon, Korea

Received May 14, 2011
Revised August 6, 2011
Accepted August 8, 2011

Address for correspondence

Yun-Hoon Choung, MD, DDS, PhD
 Department of Otolaryngology,
 Ajou University School of Medicine,
 San 5 Woncheon-dong,
 Yeongtong-gu,
 Suwon 443-721, Korea
Tel +82-31-219-5263
Fax +82-31-219-5264
E-mail yhc@ajou.ac.kr

Background and Objectives: Bondy operation is a type of modified radical mastoidectomy whose operation window is through an external auditory canal via removal of superior and posterior walls without management of the middle ears. However, the usefulness of this operation is unclear. This study aimed to review our clinical experience of modified Bondy operations and to clarify its usefulness. **Materials and Methods:** Fifteen patients underwent a modified Bondy operation at the Department of Ajou University Hospital between 1996 and 2010. Their clinical data were retrospectively reviewed including age, gender, chief complaint, diagnosis, pure tone average (PTA, a mean threshold of 0.5, 1, 2, and 3 kHz before and 3 months after the operation), otoscopic finding, temporal bone computed tomography, and recurrence rate. **Results:** The mean age of the 15 patients was 35.3 ± 14 (range 18–65) years. Post-operative diagnosis of all cases was cholesteatoma (nine attic, three external auditory canal, one sinus, and two recurrent). Pre- and postoperative PTAs were 27.4 ± 18.3 dBHL and 26.0 ± 10.7 dBHL, respectively ($p=0.72$). No postoperative recurrence or complications were noted over at least a 3-month follow-up. **Conclusions:** Modified Bondy operation is a good option to preserve hearing and prevent recurrence after operations in cases of cholesteatoma with relatively preserved middle ears.

Korean J Audiol 2011;15:72-75

KEY WORDS: Bondy operation · Hearing · Cholesteatoma · Mastoidectomy · Pure tone average.

Introduction

The surgical methods for chronic otitis media proposed by the American Society of Otolaryngology in 1964 included (and remain to the present day) radical mastoidectomy, modified radical mastoidectomy, mastoid obliteration, myringoplasty, tympanoplasty, and tympanoplasty with mastoidectomy. In 1910, Gustave Bondy reported on a modified radical mastoidectomy technique applicable to patients with an attic cholesteatoma who had only perforation of pars flaccida without ossicle and pars tensa lesions, and attempted removal of the mastoid cell inflammation to preserve hearing.¹⁻³⁾

In the Bondy operation, the operation window is made through an external auditory canal via removal of superior and posterior walls without managing the middle ears.⁴⁻⁷⁾ To date, there have been only a few reports of the use of the procedure in Korea. Berrettini, et al.⁸⁾ and Sanna, et al.⁹⁾ reported the results of modified Bondy operation, and also reported that good

functional results and low recurrence in cases where pre-operative hearing is good and when the cholesteatoma is confined to the epitympanum without ossicle and pars tensa lesions.¹⁰⁻¹²⁾

The present study was undertaken to analyze the clinical features and the results of hearing through cases of modified Bondy operation in our clinic for last 13 years. The aim was to suggest appropriate indications for the operation and its usefulness.

Materials and Methods

This study was a retrospective chart review of 15 patients who had undergone the modified Bondy operation in our tertiary hospital between 1996 and 2010. The operation for all patients involved an open cavity mastoidectomy including the superior and posterior wall of the bony external auditory canal without manipulation of middle ear structures such as the

ear drum and ossicle. All operations were carried out in case of cholesteatoma with little modification of ear drum, ossicle, and middle ear structure, and when the hearing on one side of the lesion was better than the opposite side or when hearing was only on one side. The operational procedure involved elevation of the tympanomeatal flap to the tympanic ring to confirm the lesion of epitympanum, middle ear, and ossicular chain by lifting up the posterior part of the ear drum, with no further tympanotomy conducted. Mastoidectomy and atticotomy were done to remove all air cells, all cholesteatoma in attic and mastoid were removed, but pars flaccida was preserved to maintain the ossicular chain (Fig. 1). Data concerning patient age, gender, chief complaint, diagnosis, hearing level, endoscopic findings, temporal bone computed tomography findings, and recurrence were analyzed, and especially pure tone average (PTA; 0.5, 1, 2, 3 kHz) was compared between pre-operative and post-operative hearing levels at 2–3 months. SPSS version 12.0 software (SPSS, Chicago, IL, USA) was used for analyses. Significance was determined using Wilcoxon signed rank test and a *p* value < 0.05 was considered significant.

Results

Fifteen 15 patients (nine males, six females, mean age 35.3

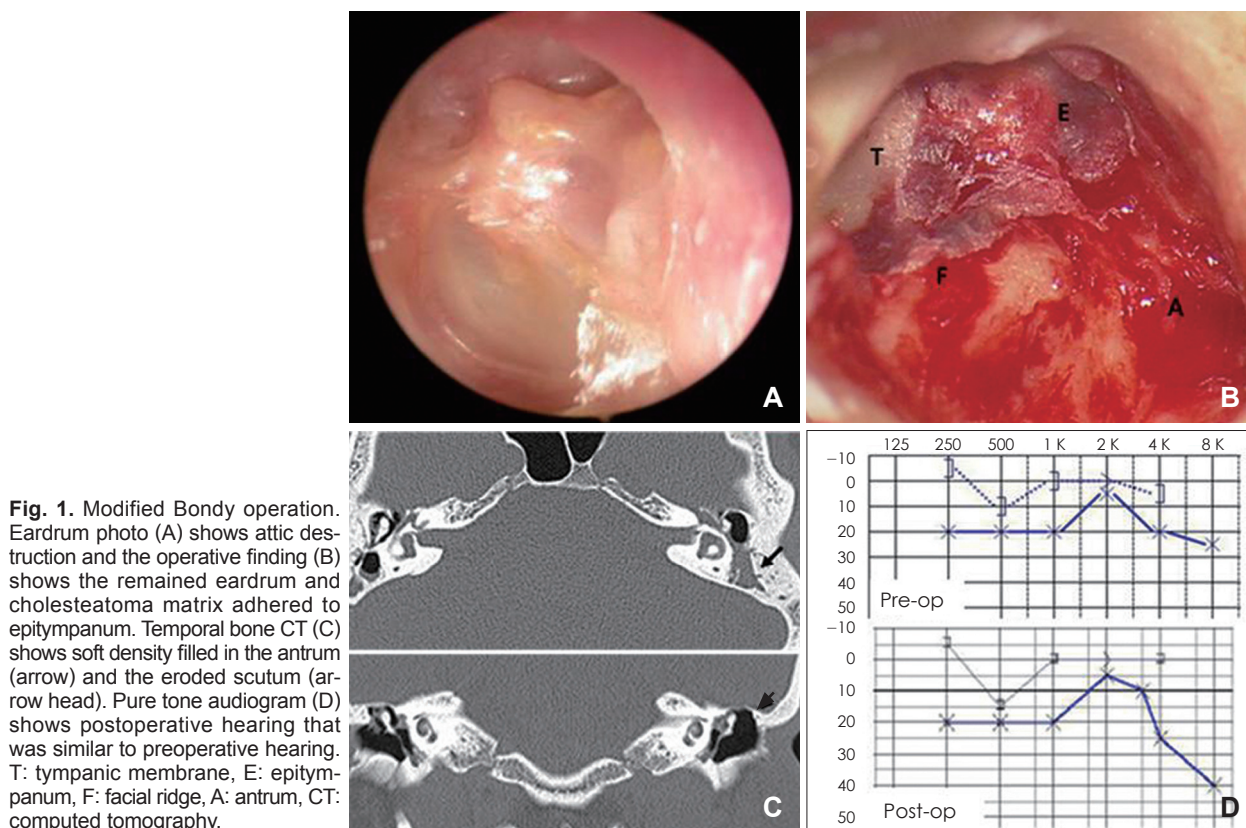
± 14 years, range 18–65 years) underwent the modified Bondy operation at our center from 1996–2010 (Table 1). The chief complaints of the patients were otorrhea (n=12, involving nine cases of purulent otorrhea and three cases of bloody otorrhea), hearing impairment (n=1), and accident (n=2). The lesion was located in the left-side in four patients and on the right-side in 11 patients. Post-operative diagnoses were attic cholesteatoma (n=9; involving one case of huge cholesteatoma with lateral sinus thrombophlebitis), three cases of external auditory canal cholesteatoma, one case of sinus cholesteatoma, and two cases of recurrent cholesteatoma (Fig. 2).

Pre-operative hearing tests were performed in all 15 cases and post-operative (8–12 weeks) PTA was determined in 10 cases. Pre-operative and post-operative mean air conduction was 27.4 ± 18.3 dBHL and 26.0 ± 10.7 dBHL, respectively (*p*=0.72), and pre-operative and post-operative mean bone

Table 1. Clinical characteristics of cases with modified Bondy operations

Gender (male : female)	9 : 6
Age, years (mean ± SD)	35.3 ± 14
Site (right : left)	11 : 4
Duration, years (mean ± SD)	8 ± 15.4
Operation period, days (mean ± SD)	84 ± 66
Post-operation F/U period, days (mean ± SD)	127 ± 26

SD: standard deviation, F/U: follow up



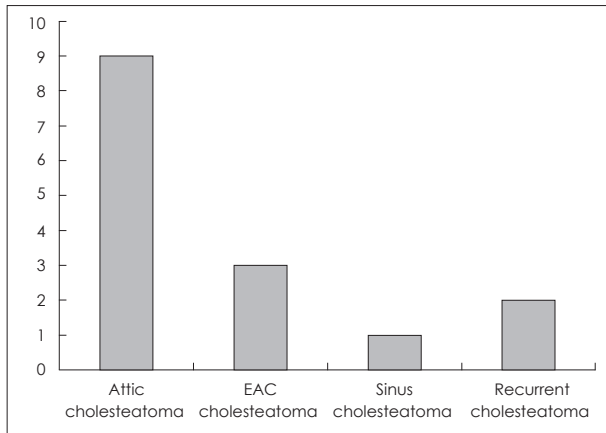


Fig. 2. Post-operative diagnosis of cases with modified Bondy operation. EAC: external auditory canal.

Table 2. Hearing of cases with modified Bondy operations

	Pre-operative	Post-operative	p
PTA AC (dBHL)	27.4±18.3	26.0±10.7	0.72
PTA BC (dBHL)	9.6± 6.5	7.4± 6.2	0.23
ABG (dBHL)	17.8±14.3	18.7±11.7	0.71

Wilcoxon signed rank test. PTA: pure tone average, AC: air conduction, BC: bone conduction, ABG: air-bone gap

conduction (BC) was 9.6 ± 6.5 dBHL and 7.4 ± 6.2 dBHL, respectively ($p=0.23$). Pre-operative and post-operative mean air-bone gap (ABG) was 17.8 ± 14.3 dBHL and 18.7 ± 11.7 dBHL, respectively, indicating similar hearing before and following surgery ($p=0.71$)(Table 2). Preoperative ABG exceeded 25 dB in two of the 10 post-operative hearing tests: two cases were an improved pre-operative and post-operative ABG to > 20 dB, two cases were improved to < 10 dB, one case exhibited no pre-operative and post-operative difference, two cases exhibited deterioration to < 10 dB, two cases deteriorated to $< 10-20$ dB, and one case deteriorated > 30 dB (Table 3). Fig. 3 showed the change of hearing thresholds in individual cases.

Just after the operation, two cases displayed symptoms of granuloma and otorrhea related to the use of otic solution. For post-operative follow-up (3 months-to-3 years), no recurrence or complications occurred, and additional surgery was unnecessary.

Discussion

The primary goal of a cholesteatoma operation is to remove the lesion completely and to maintain hearing without any complications. The methods to remove the mastoid lesion in a cholesteatoma operation are roughly divided in canal wall up mastoidectomy and canal wall down mastoidectomy. The advantages of canal wall up mastoidectomy include less reg-

Table 3. Number of cases falling in the different air-bone gap (10 cases)

Air-bone gap (dBHL)	Pre-operative, n	Post-operative, n
0-10	3	1
11-20	5	6
21-30	0	1
>30	2	2

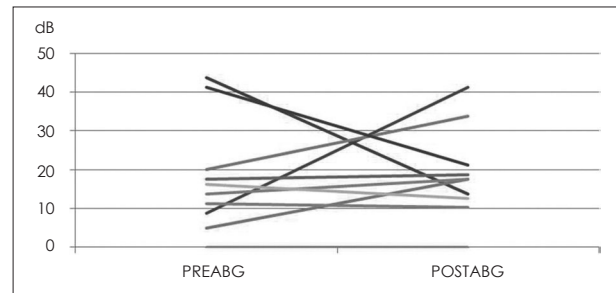
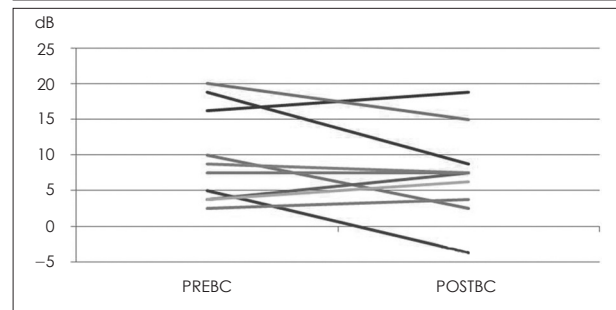
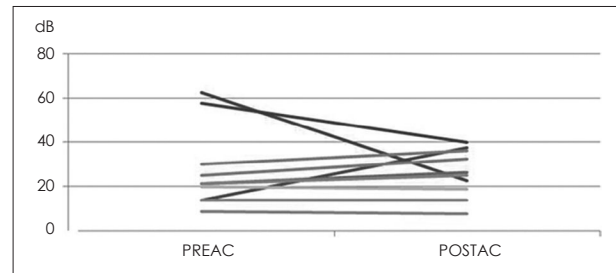


Fig. 3. Pure tone average of pre- and post-modified Bondy operation. PREAC: pre-operation air conduction, POSTAC: post-operation air conduction, PREBC: pre-operation bone conduction, POSTBC: post-operation bone conduction, PREABG: pre-operation air bone gap, POSTABG: post-operation air bone gap.

ular monitoring needs, more avoidance of labyrinth stimuli, easy subsequent use of a hearing aid, and greater possibility of post-operative hearing improvement. Disadvantages include technical difficulty, possibility of a subsequent operation, and recurrence of cholesteatoma by the formation in the retraction pocket. Although the canal wall down mastoidectomy is easy, speedy, and safe, it necessitates continuous treatments, probability of repeated otorrhea, and a much longer healing period.¹¹⁾

The recent trend in middle ear surgery has been to choose the best method for each case. This makes standardized surgery impossible, and all cases should be individualized. The

selection of the surgery method should be decided after complete understanding of the relationship between anatomical structure and the range in the lesions because of the superposition of multiple pathological factors in otitis media with its various locations. Interest in the Bondy procedure was generated immediately upon its report in 1910.¹²⁻¹⁴⁾ However, there have been few reports concerning the operation.

Recent reports have indicated that the modified Bondy operation could be performed in cases when normal or good hearing condition (pre-operative air bone gap ≤ 25 dB), when attic cholesteatoma does not involve a lesion of the ossicle and pars tensa, or when the hearing of the lesion side is better than the other side (if the other side has hearing capability). Also, the operation is warranted when the attic cholesteatoma involves a less effective ossicular chain but the conduction of ossicle is good in the superior-hearing (perhaps only) ear.^{9,11,14)}

The modified Bondy operation can preserve hearing well, with previous studies reporting 77–88% of cases demonstrating no changes or improvement, as compared with pre-operative air bone gap measurements.^{10,11)} Presently, no changes or improvement in air bone gap was evident in 70% of the cases, which was reduced in hearing post-operatively compared to references. But, statistically, there were no significant differences in pre-operative/post-operative air conduction and bone conduction, similar to the air bone gap. Another study reported no mean differences in pre-operative/post-operative air conduction and bone conduction, and also reported no pre-operative/post-operative air bone gap.⁸⁻¹⁰⁾ Even though some cases experienced high tone sensorineural hearing loss caused by acoustic trauma related to the use of the drill during the operation,⁹⁾ there were no differences in our clinic between PTA in high tone post-operatively and hearing level pre-operatively, and all BC were within 20 dBHL after the operation. Although the period of regular follow-up was limited to the short-term, there were no complications, no recurrences, and no reoperations in any of the cases.

The collective past and present results indicate that the modified Bondy operation will be useful as one of modified radical mastoidectomy in cases of cholesteatoma that do not

have any modification in middle ear structure.

Conclusion

In cases of attic cholesteatoma patients who have good hearing without any serious modification in drum and ossicle, regardless of any mastoid destruction and inflammation, the modified Bondy operation could be a good procedure to maintain hearing and prevent post-operative recurrence.

REFERENCES

- 1) Bondy G. Totalaufmeisselung mit Erhaltung von Trommelfell und Gehorknochen. *Monatsschr Ohrenheilkd* 1910;44:15.
- 2) Day KM. Primary pseudocholesteatoma of the ear. *Arch Otolaryngol* 1941;34:1144-51.
- 3) Baron SH. Modified radical mastoidectomy; preservation of the cholesteatoma matrix; a method of making a flap in the endaural technic. *Arch Otolaryngol* 1949;49:280-302.
- 4) Falcioni M, De Donato G, Taibah A, Russo A, Sanna M. [Modified Bondy technique in the treatment of epitympanic cholesteatoma. Otologic group, Piacenza]. *Acta Otorhinolaryngol Ital* 1997;17:325-8.
- 5) Cook JA, Krishnan S, Fagan PA. Hearing results following modified radical versus canal-up mastoidectomy. *Ann Otol Rhinol Laryngol* 1996;105:379-83.
- 6) Pappas DG. Bondy's modified radical mastoidectomy revisited. *Ear Nose Throat J* 1994;73:15-8.
- 7) Sheehy JL. The intact canal wall technique in management of aural cholesteatoma. *J Laryngol Otol* 1970;84:1-31.
- 8) Berrettini S, Ravecca F, de Vito A, Forli F, Valori S, Franceschini SS. Modified Bondy radical mastoidectomy: long-term personal experience. *J Laryngol Otol* 2004;118:333-7.
- 9) Sanna M, Facharzt AA, Russo A, Lauda L, Pasanisi E, Bacciu A. Modified Bondy's technique: refinements of the surgical technique and long-term results. *Otol Neurotol* 2009;30:64-9.
- 10) Mukherjee P, Saunders N, Liu R, Fagan P. Long-term outcome of modified radical mastoidectomy. *J Laryngol Otol* 2004;118:612-6.
- 11) Sanna M, Agarwal M, Khrais T, Di Trapani G. Modified Bondy's technique for epitympanic cholesteatoma. *Laryngoscope* 2003;113:2218-21.
- 12) Gopalakrishnan S, Chadha SK, Gopalan G, Ravi D. Role of mastoid obliteration in patients with persistent cavity problems following modified radical mastoidectomy. *J Laryngol Otol* 2001;115:967-72.
- 13) Naguib MB, Aristegui M, Saleh E, Cokkeser Y, Russo A, Sanna M. Surgical management of epitympanic cholesteatoma with intact ossicular chain: the modified Bondy technique. *Otolaryngol Head Neck Surg* 1994;111:545-9.
- 14) Shaan M, Landolfi M, Taibah A, Russo A, Szymanski M, Sanna M. Modified Bondy technique. *Am J Otol* 1995;16:695-7.