

## Anatomical Variation of the Glissonean Pedicle of the Right Liver

**Purpose:** Many studies have been conducted to date regarding whether the right hepatic vein is the accurate border that divides the anterior and posterior section of the right liver. It has been reported that the Glisson pedicle of the right liver may be an anatomical variation that does not have a consistent morphology. We analyzed the relationship between the true borders of the anterior and posterior sections, and the right hepatic vein, based on cadaver dissection and MD-CT image analysis of the anatomical variation of the Glisson pedicle of the right liver.

**Methods:** Sixteen cadaver livers were available for dissection from the Department of Anatomy, and pre-operative MD-CTs of 20 donor livers who underwent living donor liver transplantation prior to December 2009, were obtained. We analyzed the 3D-relationship between the branches of the Glisson pedicles and the right hepatic vein of the right liver. They were divided into 3 groups according to the sliding pattern of the branches of the Glisson pedicle origin. When all segmental branches of the anterior pedicle arise from the main trunk of the anterior pedicle and all branches of posterior pedicle arise from the main trunk of posterior pedicle, it was designated as Group A (Normal Group). When a portion of the segmental branches of the anterior pedicle arises from the main trunk of the posterior pedicle, it was designated as Group B (Posterior dominant group). When a portion of the branches of the posterior pedicle arises from the main trunk of the anterior pedicle, it was designated as Group C (Anterior dominant group).

**Results:** Among the 16 cadaver liver dissections, 6 cases were in Group A, 5 in Group B, and 3 in Group C. Two cases were excluded from the study because the inferior right hepatic vein was the main draining vein of the right liver. The analysis of preoperative MD-CT of the 20 donor livers showed that there were 13, 4, and 3 patients in Groups A, B, and C, respectively.

**Conclusion:** According to Couinaud's theory of anatomy, the right hepatic vein serves as the border between the anterior and posterior sections of the right liver. But, due to the frequent anatomical variations, an adequate understanding of the anatomical variations of the right Glisson pedicle should be necessary for liver surgery.

**Key Words :** Liver anatomy, Glisson pedicle, Hepatectomy

Weiguang Xu, M.D., Hee Jung Wang, M.D., Ph.D., Bong-Wan Kim, M.D., Ph.D., Yong-Keun Park, M.D., Guangyi Li, M.D.

Department of Surgery, Ajou University School of Medicine

### Corresponding Author

Hee Jung Wang  
Department of Surgery, Ajou University School of Medicine, San 5, Woncheondong, Yeongtong-gu, Suwon 443-721, Korea  
Tel: +82-31-219-5204  
Fax: +82-31-219-5755  
E-mail: wanghj@ajou.ac.kr

Received: 2011. 3. 16

Accepted: 2011. 4. 10

## Introduction

The ideal hepatic resection in patients with hepatocellular carcinoma (HCC) is complete resection of the segment or hemiliver including the tumor, thus enhancing the radicality of the procedure. Also, the absence of injury to the vascular pedicle of the remaining liver minimizes the

extent of dead tissue, and reduces the incidence of complications or organ failure. To enhance resectability in HCC patients with accompanying liver cirrhosis, the Glissonean pedicle approach, including a systematic, limited resection technique that satisfies the above conditions, is widely employed as the standard procedure in all liver resections or hepatectomies.

In addition, it is essential to accurately perform the

resection along the planned resection plane in order to minimize intraoperative bleeding. According to Couinaud's concept of liver anatomy, the right liver is divided into the anterior section and posterior section by the right portal fissure. Therefore, it may be assumed that the entire length of the right hepatic vein can be exposed during anterior sectionectomy/posterior sectionectomy.<sup>1</sup> However, anatomical variations are not infrequent, and therefore the right hepatic vein may not always be entirely exposed during right posterior sectionectomy/right anterior sectionectomy, and hepatectomy employing the Glissonean pedicle approach occasionally leads to ischemic color changes of other unexpected segment surfaces. Couinaud observed that the anatomical variation of the right Glissonean pedicle (or the portal pedicle) showed a sliding of the origin pattern. We attempted this study to further ascertain the variations of the right Glissonean pedicle.

## Methods

### 1. Dissection of cadaver livers

Sixteen cadaver livers were recruited in the initial phase. Two of the livers were excluded from study as the inferior

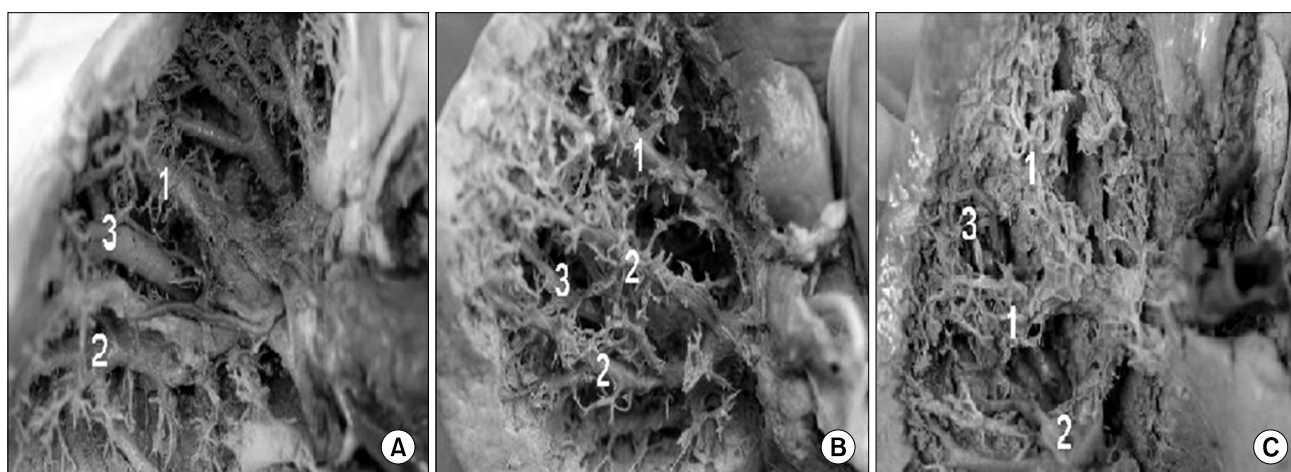
right hepatic vein was the main draining vein of the right liver. The remaining 14 cadaver livers were included in the final study. The male to female ratio was 8 : 6 and the mean age was 64.6 (range, 38~86) years.

Dissection of the cadaver livers began with dissection of the liver parenchyma using Mosquito forceps from the inferior surface of the liver, that is, the visceral surface. The procedure proceeded to separation up to the Glissonean pedicle segmental branches of the right liver anterior and posterior sections, followed by meticulous dissection of the right hepatic vein and evaluation of the relationship between the Glissonean pedicle segmental branches and the right hepatic vein, which was recorded by photography for documentation (Fig. 1).

### 2. MD-CT of live donors for liver transplantation

Among patients who received pre-operative MD-CT and underwent living donor liver transplantation (LDLT) prior to December 2009, 20 donors who were the most recent and consecutive were selected for study. The male to female ratio was 16 : 4 and the mean age was 28.5 (range, 15~53) years.

The anatomical relationship between the segmental



**Fig. 1.** Dissected pictures of cadaver liver. (A) Normal group: all right posterior branches from the right posterior portal pedicle or all right anterior branches from the right anterior portal pedicle. (B) Right posterior dominant group: some right anterior branches from the right posterior portal pedicle. (C) Right anterior dominant group: some right posterior branches from the anterior portal pedicle. 1: Right anterior portal pedicle, 2: Right posterior portal pedicle, 3: Right hepatic vein.

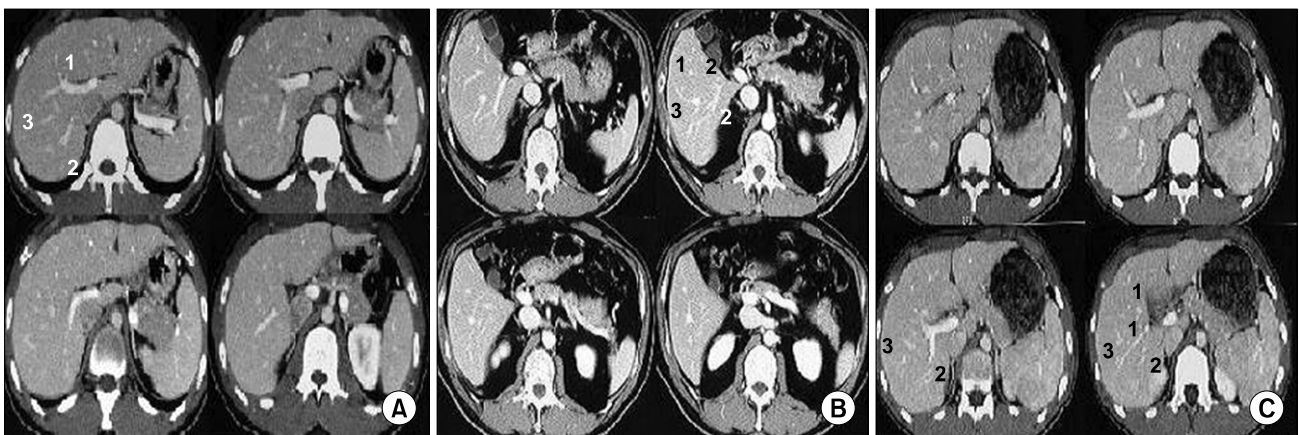
branches of the Glisson pedicle and the right hepatic vein of the right liver were analyzed in detail and assessed by pre-operative 2 mm MD-CT segments (Fig. 2).

The A group (normal group) consisted of all anterior sectional branches of the Glissonean pedicle (branches of segment 5 and segment 8) that originated from the main Glissonean trunk of the anterior section, and all posterior sectional branches of the Glissonean pedicle (branches of segment 6 and segment 7) that originated from the main Glisson trunk of the posterior section. The B group (posterior pedicle dominant group) consisted of cases in which some portions of the segmental Glissonean branches of the anterior section originated from the posterior

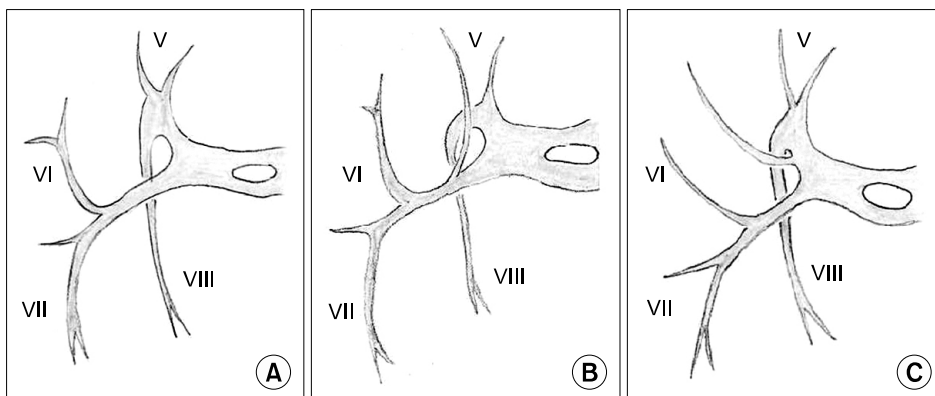
Glissonean trunk. Cases in which some portions of the segmental Glissonean branches of the posterior section originated from the anterior Glisson trunk were designated as the C group (anterior pedicle dominant group) (Fig. 3).

## Results

Of the 14 dissected cadaver livers, 6 had branches of the Glissonean pedicle (branches of segment 5 and segment 8) that originated from the main Glissonean trunk of the anterior section, and all posterior sectional branches of the Glissonean pedicle (branches of segment 6 and segment 7) originated from the main Glisson trunk of the posterior



**Fig. 2.** (A) Normal group: all right posterior branches from the right posterior portal pedicle or all right anterior branches from the right anterior portal pedicle. (B) Right posterior dominant group: some right anterior branches from the right posterior portal pedicle. (C) Right anterior dominant group: some right posterior branches from the anterior portal pedicle. 1: Right anterior portal pedicle, 2: Right posterior portal pedicle, 3: Right hepatic vein.



**Fig. 3.** Variations of the right pedicle. (A) No variations of the right pedicle. (B) Branch of V originating from the right posterior pedicle. (C) Branch of VI originating from the right anterior pedicle (caudal view).

section. These cases were thus designated as belonging to group A. In 5 cases some portions of the segmental Glissonian branches of the anterior section originated from the posterior Glissonian trunk (the B group, posterior pedicle dominant group). The remaining 3 cases were those in which some portions of the segmental Glissonian branches of the posterior section originated from the anterior Glissonian trunk (the C group, anterior pedicle dominant group). In addition, MD-CT imaging analysis demonstrated that 13 cases were group A, 4 were group B, and 3 were group C.

In summary, the Glissonian pedicle that supplies the anterior and posterior sections of the liver display considerable anatomical variation. In group A, 6 and 13 cases (55.9%, 19/34, cadaver dissection and MD-CT analysis, respectively) were observed to be normal variations in accordance with Couinaud's results. For the B group, the posterior pedicle dominant group, 5 and 4 cases were observed (26.5%, 9/34, cadaver dissection and MD-CT analysis, respectively). For the C group, the anterior pedicle dominant group, 3 and 3 cases were observed (17.6%, 6/34, cadaver dissection and MD-CT analysis, respectively).

Therefore, the overall analysis showed that in 44.1% (15/34) the true border between the anterior and posterior segments of the right liver is different from the right hepatic vein, as suggested by Couinaud. Thus it is our conclusion that in 44% of anterior sectionectomy or posterior sectionectomy procedures, it would be difficult to expose the entire length of the right hepatic vein in the resection plane (Table 1).

**Table 1.** Analysis for anatomical variations of the Glissonian pedicle in the right liver

	Cadaver dissection	MD-CT	Total cases
Normal group	6	13	19 (55.9%)
Posterior dominant group	5	4	9 (26.5%)
Anterior dominant group	3	3	6 (17.6%)

## Discussion

Currently, systematic liver resection that incorporates the Glissonian pedicle approach is widely employed for liver resection or hepatectomy.<sup>2,3</sup> Within the intrahepatic space of the liver, the hepatic artery, portal vein, and bile duct are firmly enclosed in connective tissue, while they are surrounded by loose connective tissue and covered by the peritoneum in the extrahepatic space. The Glisson pedicle is divided into the left pedicle, right anterior pedicle, and the right posterior pedicle in the hepatic hilum.

They become second order branches after leaving caudate branches. The next branches within the liver are tertiary branches. No regularity can be found with regard to the branching pattern and location of the hepatic artery, portal vein, and bile duct within the extrahepatic Glisson branch, but the second order branches that enter the liver show a distribution to the corresponding section of the hepatic artery, portal vein, and bile duct, and do not distribute to any other sections.<sup>4</sup>

Therefore, a safe and simple Glissonian pedicle approach may be accomplished by performing the procedure at the second order branch or at more distal branches. This also permits hepatectomy by ischemic discoloration of the liver surface. However, some liver surgeons occasionally ligate the right anterior or posterior Glisson pedicle, which sometimes leads to discoloration of the liver, not only of the entire right anterior or posterior section, but also of some portion of the right posterior or anterior section, respectively. In order to clarify the above phenomenon, we conducted this study by investigating the branching patterns of the Glissonian pedicle or portal vein.

The Brisbane Meeting of the International Society of Hepato-biliary-Pancreatic Surgery in 2000 formed a consensus of a uniform anatomical term/terminology classification to correct the confusion that was present at that time. Their consensus was that first-order divisions were those that supplied the right and left hemiliver,

second-order divisions those that supplied the liver sections, and the third-order divisions those that supplied the segment.<sup>5</sup> This classification should be based on accurate functional and anatomical criteria, but third-order divisions according to the Glisson pedicle are still under debate.

Also, in a series by Cho et al.<sup>6</sup> who employed 3D vascular imaging, it was suggested that rather than dividing the right anterior portal vein into upper and lower portions, it would be more appropriate to divide it into ventral and dorsal portions, thus dividing the right liver into 3 sections; an anterior ventral section, an anterior dorsal section, and a posterior section.

On the other hand, if the portal pedicle is divided into 4 sections, as described by Couinaud, the borders between the sections would be the 3 hepatic veins, and with the hepatic vein as the reference, the 3 divided territories would be divided with the right portal fissure and umbilical fissure as the borders<sup>1</sup> (Fig. 4). It would follow that the borders of the right anterior section and the right posterior section would be the right hepatic vein, and exposure of the right hepatic vein would always be available during hepatectomy that employs the border between the right anterior section and the right posterior section as the resection plane. However, exposure of the right hepatic vein is not always possible during an inflow-oriented hepatectomy, including a Glissonean pedicle approach. The reason stated by Couinaud is that the right Glisson pedicle

is characterized by a sliding of the origin variation. Although the course of the second order branches of the hepatic artery, portal vein, and bile duct in the Glisson sheath space are always to assigned sections, there is considerable variation with regard to the course of the Glisson pedicle itself, starting from the origin. This is demonstrated in the 3 types described above. In the majority of cases, the right hepatic vein serves as the accurate border between the right anterior and right posterior sections in the right liver.

Won et al.<sup>7</sup> reported that the most common (46%) third-order branching pattern of the right portal pedicle was the normal pattern consisting of dorsal and ventral branches of segment 8 and segment 5 branches that arise from the right anterior pedicle, and segment 6 and segment 7 branches that arise from the right posterior pedicle. The next most common (44%) was not only segment 5 and 6 branches, but also portions of segment 7 branches that arise from the main right anterior pedicle, and is termed an anterior pedicle dominant pattern. In this study, all anterior segmental Glissonean pedicles arising from the main anterior Glissonean trunk plus all posterior segmental pedicles arising from the main posterior Glissonean trunk comprised 55.9% of study cases. A portion, 26.5%, of the anterior segmental pedicles arose from the main posterior Glissonean pedicle; a portion, 17.6%, of posterior segmental pedicles arose from the anterior section.

That is, some of the branches of the right anterior portal pedicle cross over the right hepatic vein to distribute to the right posterior section (anterior pedicle dominant pattern), while those that cross over from the right posterior portal pedicle to the right hepatic vein to distribute to the right anterior section show a posterior pedicle dominant pattern. In these instances, hepatectomy by the Glissonean pedicle approach with the right hepatic vein as the border of the resection plane would be more feasible. In actual clinical practice, if the liver tumor is located in the right posterior section and right posterior Glisson pedicle ligation is performed to resect this section, and if the ischemic surface

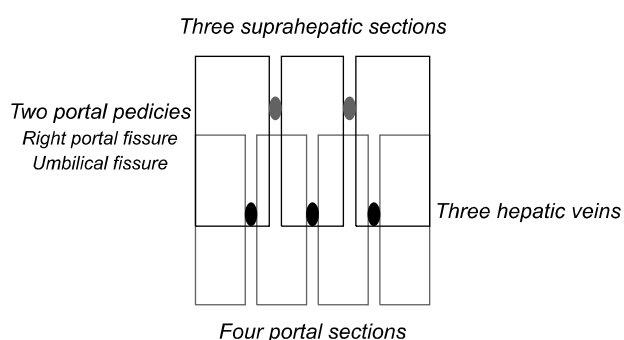


Fig. 4. Diagram of the two segmentations.

discoloration theoretically carries over to the right hepatic vein, resection of all discolored areas would result in congested areas of the remaining right anterior section. This entails the risk of liver failure in a patient with inadequate liver function reserve. However, if the right hepatic vein is designated as the resection reference, an ischemic area occurs in a portion of the right anterior section. Therefore, when planning such a procedure, consideration should be given to various factors such as the distance between the tumor and resection plane and liver function status.

It is thought that adequate understanding of the anatomical variation of the Glisson pedicle with regard to the right hepatic vein, which serves as the reference structure for dividing the right anterior section and the right posterior section, as specified by Couinaud, is essential. Also, adequate imaging analysis should be conducted prior to hepatectomies to accurately assess variations in the Glisson pedicle by evaluating the nearest structures, i.e., the branching pattern of the portal vein.

## Conclusion

According to Couinaud's theory of anatomy, the right hepatic vein serves as the border between the anterior

section and posterior section of the right liver, but due to not infrequent anatomical variations, an adequate understanding of the anatomical variations of the right Glisson pedicle will assist in liver surgery.

## References

1. Couinaud C. *Liver anatomy: portal (and suprahepatic) or biliary segmentation*. *Dig Surg* 1999;16:459-467.
2. Okamoto E, Yamanaka N. *Anatomical resection of the right hepatic subsegments preceded by suprahilar ligation of the portal pedicles*. In: Tobe T, Kameda H, Okudaira M, et al, editors. *Primary liver cancer in Japan*. Tokyo: Springer; 1992.229
3. Launois B, Jamieson G. *Modern operative techniques in liver surgery*. Edinburgh: Churchill Livingstone; 1993.
4. Makuuchi M. *Knack & pitfalls of liver surgery. (Kr) 1st ed*. Seoul: Koon Ja Publishing co; 2003. 102-103.
5. Belghiti J, Clavien PA, Gadzijev E, et al. *The Brisbane 2000 terminology of liver anatomy and resections*. *HPB* 2000;2: 333-339.
6. Cho A, Okazumi S, Miyazawa Y, et al. *Proposal for a reclassification of liver based anatomy on portal ramifications*. *Am J Surg* 2005;189:195-199.
7. Won TW, Park DE, Lee YH, Chae KM. *A new classification of the right portal vein using 64 channel multi-detector CT (MDCT)*. *J Korean Surg Soc* 2008;75:96-101.